



HOSTED BY



ELSEVIER

Contents lists available at ScienceDirect

Journal of Acute Disease

journal homepage: www.jadweb.orgOriginal article <http://dx.doi.org/10.1016/j.joad.2015.06.005>

Advances in management of patients with acute diverticulitis

Sibilla Focchi^{1*}, Alberto Carrara^{1,2}, Ettore Contessini Avesani^{1,2}¹Department of General and Emergency Surgery, IRCCS Ca' Granda – Maggiore Policlinico Hospital Foundation, Milan, Italy²Faculty of Medicine, University of Milan, Milan, Italy

ARTICLE INFO

Article history:

Received 28 May 2015

Received in revised form 28 May 2015

Accepted 16 Jun 2015

Available online 28 Jul 2015

Keywords:

Diverticulitis

Emergency surgery

Damage control surgery

Laparoscopic lavage and drainage

Percutaneous drainage

Primary resection with anastomosis

Hartmann's procedure

ABSTRACT

Objective: To analyse the development of the medical and surgical treatment of acute diverticulitis to develop an appropriate decision-making algorithm.

Methods: We analysed the demographic characteristics, radiological images, disease severity, treatments and surgical outcomes of all of the patients with a diagnosis of acute diverticulitis admitted to the Department of General and Emergency Surgery between 1 January 2009 and 30 June 2014.

Results: During the 66-month study period, 219 patients with acute diverticulitis attended our department; 69% had simple diverticulitis (93% were treated conservatively and 7% surgically) and 31% had complicated diverticulitis (76% were treated surgically and 24% conservatively). Of the patients who were treated surgically, 62.5% underwent primary resection with anastomosis, 31.94% Hartmann's procedure, and 5.56% laparoscopic lavage and drainage.

Conclusions: Our cases and a careful review of the literature allowed us to develop a decision-making algorithm for patients with acute diverticulitis.

1. Introduction

Diverticulitis is the most frequent surgically treated disease after cancer in modern Western societies, and its incidence is increasing with the older average age of the population. It affects 10% of the people living in industrialised countries: 5% aged <40 years, 30% aged >60 years and 65% aged >80 years^[1]. Only 16% of patients experience a first episode at an age <45 years while the average age of hospitalization for the first episode of acute diverticulitis is 63 years^[2,3].

Diverticulitis is a heterogeneous disease that 75% of cases occur in uncomplicated form while 25% of cases can be complicated by abscess, fistula, peritonitis, obstruction and haemorrhage^[4].

Disease severity is classified using Hinchey's staging system^[5], as modified by Wasvary *et al.* in 1999: Stage 0 mild clinical diverticulitis; Stage IA confined pericolic inflammation or phlegmon; Stage IB pericolic or mesocolic abscess; Stage II pelvic, distant intra-abdominal or retroperitoneal abscess; Stage

III generalised purulent peritonitis; and Stage IV generalised faecal peritonitis (Table 1)^[6]. Treatment mainly depends on disease severity and recent surgical strategies have concentrated on reducing the duration of surgery and postoperative complications^[7].

The first surgical technique, known as the “three-stage procedure”, was developed by Mayo *et al.* in 1907: a colostomy at the level of the transverse colon and the positioning of drainage; the resection of the diseased colon after a period of 3–6 months; and stoma closure after a further 3–6 months^[8]. The morbidity rate was acceptable, but it was burdened by a high rate of mortality (30%–60%) because the diseased colon remained *in situ* for a long time and was a significant source of infection^[9].

The second method, the “two-stage” or Hartmann's procedure (HP), was used for the first time by Henry Hartmann in 1921 in order to perform sigmoid resection for the treatment of neoplastic disease^[10]. It consists of a segmental resection of the diseased colon without a primary anastomosis but with an end colostomy^[11]; intestinal continuity can be restored during a second operation, but this is not possible in 20%–50% of cases^[12]. Widely used since the 1950s, HP became the standard of care in the 1980s, but has a significant complication rate and mortality rates range from 5% to 14%^[13].

A “one-stage” procedure [primary resection with anastomosis (PRA)] has been proposed since 1990. The most feared

*Corresponding author: Sibilla Focchi, Department of General and Emergency Surgery, IRCCS Ca' Granda – Maggiore Policlinico Hospital Foundation, Milan, Italy.
Tel: +39 3338547891
E-mail: Sibilla.focchi@hotmail.it
Peer review under responsibility of Hainan Medical College.

Table 1

Hinchey staging system as modified by Wasvary and CT findings according to Ambrosetti's criteria.

Hinchey classification modified by Wasvary		CT findings (Ambrosetti's criteria)
Stage 0	Mild clinical diverticulitis	Diverticula with or without colonic wall thickening
Stage IA	Confined pericolic inflammation or phlegmon	Colonic wall thickening and inflammatory reaction of pericolic fatty tissue
Stage IB	Pericolic or mesocolic abscess	Colonic wall thickening, inflammatory reaction of pericolic fatty tissue and pericolic or mesocolic abscess
Stage II	Pelvic, distant intra-abdominal or retroperitoneal abscess	Colonic wall thickening, inflammatory reaction of pericolic fatty tissue and pelvic/distant intra-abdominal/retroperitoneal abscess
Stage III	Generalised purulent peritonitis	Extraluminal air/extraluminal contrast
Stage IV	Generalised faecal peritonitis	Extraluminal air/extraluminal contrast

complication of this technique is anastomotic leakage, which occurs in 6% of cases, particularly when there is considerable peritoneal contamination; however, the risk of anastomotic dehiscence can be reduced by performing a proximal loop ileostomy to be closed during a second procedure^[14].

In a bid to reduce the mortality and morbidity associated with emergency surgery, a new approach that consists of administering intravenous antibiotics and performing a percutaneous drainage (PCD) of major abscesses or using laparoscopic lavage of the abdominal cavity with the positioning of drainages [laparoscopic lavage and drainage (LLD)] has recently been adopted.

It has been noted that mortality is very low in patients treated in this manner, who are discharged earlier than those undergoing HP^[15]. PCD can be performed under ultrasound (US) or computed tomography (CT) guidance, and drainage is usually done through the anterior or lateral abdominal wall in order to avoid damaging the inferior epigastric artery and deep circumflex iliac vessels, although transgluteal, transperineal, transvaginal and transanal approaches can also be used^[16]. Complications, such as bleeding, visceral perforation, solid organ injury and fistulation only occur in 5% of cases, and the failure rate ranges from 15% to 30%^[17].

LLD is a minimally invasive operation that consists of aspirating free purulent fluid from the peritoneal cavity, mobilising inflammatory abdominal wall attachments from the inflamed colon, opening purulent cavities and copious (>4 L) washings with a warmed iodine and saline solution, followed by the placement of drainages. This operation is supported by the administration of intravenous antibiotics. The use of LLD to manage severe diverticulitis with generalised peritonitis is associated with mortality and morbidity rates less than 5%, and so it is useful in patients with Hinchey stage III or IV diverticulitis^[18].

Finally, Damage Control Surgery (DCS) is an approach that can be used for patients with peritonitis caused by acute perforated diverticulitis who are rapidly developing septic shock. The technique was created in 1983 by Stone *et al.* as a means of treating trauma patients presenting with the bloody viscous cycle: acidosis, hypothermia, coagulopathy^[19], but can also be used for patients with intra-abdominal sepsis that may rapidly evolve in septic shock as they are too unstable to undergo immediate surgery and have an high postoperative risk of acute kidney injury and multiple organ failure^[20]. In the case of acute diverticulitis with perforation and severe septic shock, DCS consists of a limited resection of the inflamed perforated colon using staplers without making a colostomy, after which the abdominal wall is temporarily closed using the vacuum-assisted closure (VAC) technique. The patients are then

transferred to an ICU for ongoing resuscitation and, once their physiological status has been optimised, returned to the operating room to undergo peritoneal lavage and colostomy or primary anastomosis depending on the condition of the bowel (oedema and hypoperfusion of the wall), their comorbidities and the surgeon's experience^[21].

Given the frequency and severity of the disease, and the rapidly evolving therapeutic scenario, the aim of this study was to analyse the development of the medical and surgical treatment of acute diverticulitis on the basis of a literature review and our own clinical experience in order to develop an appropriate decision-making algorithm.

2. Materials and methods

We considered all of the patients admitted to the Department of General and Emergency Surgery, IRCCS Ca' Granda – Maggiore Policlinico Hospital Foundation (Milan, Italy) between 1 January 2009 and 30 June 2014 with a diagnosis of acute diverticulitis. Diverticulitis was diagnosed by evaluating the patients' history, clinical features (left lower abdominal pain, tenderness, palpable resistance, fever, diarrhoea, constipation, vomiting, and urinary disorders), laboratory findings (leukocytes, C-reactive protein, s-amylase, s-lipase, s-aminotransferase, s-alkaline phosphatase, s-bilirubin, s-electrolytes), abdominal radiography and CT scan in order to confirm the suspected diagnosis by excluding other causes of abdominal pain and allow disease staging. We also analysed their demographic characteristics, disease severity and treatments, and finally examined their surgical outcomes on the basis of operating times, the number of days of analgesia, the resumption of peristalsis and canalisation, the day of nasogastric tube (NGT) removal, the resumption of eating, the duration of hospitalisation, the incidence of major and minor complications, reoperations, and intra- or postoperative mortality.

3. Results

During the 66-month study period, 219 patients with acute diverticulitis [47% males and 53% females; mean age 61.9 years (range 25–94); median age 63 years] attended the Department of General and Emergency Surgery; 10% aged <40 years, 33% aged 40–60 years, 42% aged 60–80 years, and 15% aged >80 years (fully in line with the age distribution described in the literature)^[22]. The age- and gender-related disease prevalence rates was also the same as those previously published^[23]: the disease was more prevalent among males than females aged <50 years (74% vs. 26%; M:F = 2.9:1); similarly prevalent among those aged 50–70 years (52% vs. 48%; M:F = 1.1:1);

and more prevalent among females than males aged >70 years (21% vs. 79%; M:F = 0.28:1). Males therefore developed the disease at a younger age, but overall gender frequency was similar (47% vs. 53%; M:F = 0.8:1).

The disease was mainly localised at the level of the descending colon and/or sigma (89%), and less frequently at the level of the caecum, and the ascending and transverse colon (11%). Caecal and ascending colon diverticula are generally congenital^[24], and attacks of acute diverticulitis in these regions occur earlier, at a median age of 49 years.

In line with the findings of previous studies (75% and 25%)^[25], diverticulitis was simple (Hinchey Stage 0, IA or IB) in 69% of the patients, and Hinchey Stage II, III or IV, or complicated by stenosis or fistulas in 31%.

The vast majority (93%) of the patients with uncomplicated diverticulitis were treated conservatively, and only 7% underwent surgery, whereas 76% of the patients with complicated diverticulitis were treated surgically and 24% were treated conservatively. These figures are slightly different from other published data, which indicate that 85% of patients with uncomplicated diverticulitis can be treated conservatively, with negligible mortality and success rates of 70%–100% (the remaining 15% generally do not respond to conservative treatment)^[26], and that surgery is required in 90%–95% of patients with complicated diverticulitis, with only 5%–10% responding to conservative treatment (Figure 1)^[27].

Our patients in Hinchey Stage 0, IA, IB, and Stage II with abscesses of <3 cm were usually treated conservatively, which involved: complete bowel rest and start of parenteral feeding; the placement of NGT in case of nausea and vomiting or abdominal distension; intravenous antibiotics: ciprofloxacin 400 mg twice a day and metronidazole 500 mg three times daily.

Once the clinical symptoms have improved and inflammatory indices have decreased, enteral feeding is started and antibiotic therapy is administered orally: ciprofloxacin 500 mg twice a day and metronidazole 500 mg three times daily. When the symptoms have completely remitted, the patient is discharged and continues antibiotic therapy at home until the end of the 14-day cycle; we also recommend a fibre-free diet for about 20 days, after which fibre can be gradually reintroduced. Finally, given

the likelihood of disease exacerbation, the patients are advised to return for a check-up 4–6 weeks after discharge in order to assess the need for surgical resection.

During the study period, average hospitalisation was 4.68 days: 76% of the patients stayed in hospital for up to 5 days, 21% for 2–10 days, and only 3% for >10 days. Treatment was successful in 100% of cases.

The patients in Hinchey Stage II with abscesses of >3 cm were treated with conservatively as described above, with the addition of the US-guided placement of PCD through the anterior abdominal wall (86%) or trans-vaginally (14%). The catheter was left in place for an average of eight days (range 1–19 days) until the drained material was <10 mL/24 hours and the indices of inflammation had decreased. The average recovery time was nine days (range 6–21 days) and there were not complications related to the procedure. All of the patients were discharged with an indication to return for a check-up in order to assess the need for surgical resection.

The diverticulitis was uncomplicated in 19.44% of the surgically treated patients, who underwent surgery after an average of six days of antibiotic therapy. Surgery was considered necessary because of the risk of a sudden clinical and/or the possibility of recurrence.

Complicated diverticulitis was observed in 80.56% of the patients: 25% in Hinchey Stage II, 33.33% in Hinchey Stage III, 13.89% in Hinchey Stage IV, 4.17% with occlusions, and 4.17% with fistulae. Surgical treatment consisted of PRA in 62.5% of the patients (17.78% with and 82.22% without loop ileostomy), HP in 3.94%, LLD in 5.56%.

PRA was mainly used in patients with uncomplicated acute diverticulitis (31.11%), and in those in Hinchey Stage II (28.89%) and III (22.22%), and less frequently in those in Hinchey Stage IV (4.44%) and those with diverticulitis complicated by occlusions (6.67%) or fistulae (6.67%), and HP was mainly used in patients in Hinchey Stage III (56.52%) and IV (34.78%), and less frequently in those in Hinchey Stage II (8.7%). LLD was used in patients in Hinchey Stage II (75%) and III (25%).

Outcomes were better in the patients who underwent PRA than in those undergoing HP: less postoperative pain (5.98 vs. 12.25 days of analgesic therapy), more rapid resumption of peristalsis (2.44 vs. 3.25 days) and canalisation (5.31 vs. 6.25 days), earlier NGT removal (3.71 vs. 5 days), more rapid resumption of eating (5.16 vs. 6.70 days), a shorter hospital stay (15.11 vs. 19.70 days), lower rate of minor complications (47.7% vs. 59.1%) and major complications (23.82% vs. 36.4%), less frequent reoperations (14% vs. 18%) and a lower mortality rate (0% vs. 13.6%). The most feared complication of PRA (anastomosis leakage) occurred in only 2.98% of cases. Finally, it was possible to close the ileostomy in 100% of the PRA patients, whereas intestinal continuity was restored only in 41% of those who underwent HP.

In Table 2, LLD also led to better outcomes than HP in terms of the need for analgesic therapy (7.75 vs. 12.25 days).

The resumption of peristalsis was the same (3.25 days), but canalisation took longer (8.00 vs. 6.25 days) and so the resumption of eating was later (7.00 vs. 6.70 days). There weren't minor (0% vs. 59.1%) or major complication (0% vs. 36.4%), reoperation wasn't necessary (0% vs. 18%) and the mortality rate was 0% vs. 13.6%. Furthermore, operating time was shorter (94 vs. 201 min), a very important advantage in the case of patients at high operatory risk, and the patients

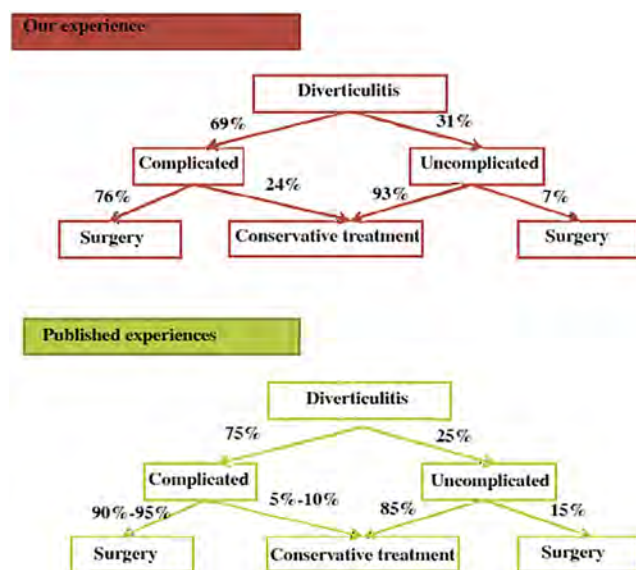


Figure 1. Management of patients with acute diverticulitis: our experience and a summary of previously published experiences.

Table 2
Outcomes of surgical patients.

Outcomes	LLD (n = 4)	PRA (n = 45)	HP (n = 23)
Operating time (min)	94.00 (54–149)	256.20 (90–1 964)	201.43 (130–329)
Days of analgesia	7.75 (3–18)	5.98 (2–28)	12.25 (3–65)
Resumption of peristalsis	3.25 (1–9)	2.44 (1–23)	3.25 (1–13)
Resumption of canalisation	8.00 (4–13)	5.31 (2–25)	6.25 (3–17)
Day NGT removed	4.00 (1–9)	3.71 (1–25)	5.00 (2–13)
Resumption of eating	7.00 (3–15)	5.16 (2–28)	6.70 (3–19)
Length of hospital stay (days)	14.50 (7–29)	15.11 (6–58)	19.70 (7–87)
Major complications	0%	23.82%	36.4%
Minor complications	0%	47.70%	59.1%
Re-operations	0%	14.00%	18.0%
Mortality rate	0%	0.00%	13.6%
Bowel continuity reconstruction	100%	100.00%	41.0%

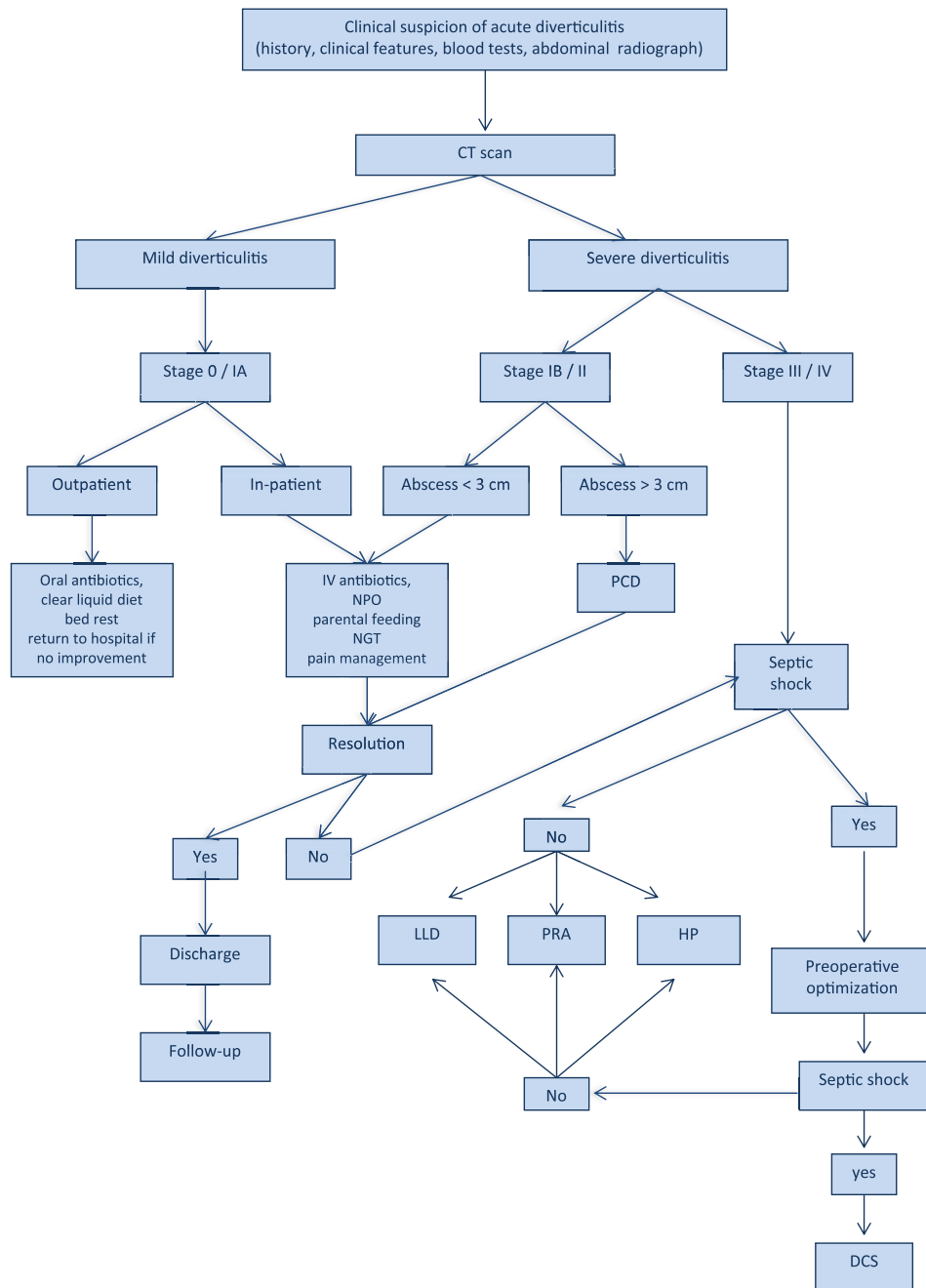


Figure 2. Decision making algorithm for patient with acute diverticulitis.

enjoyed the benefits of undergoing a minimally invasive technique, and the fact that any resection necessary could be performed minimally invasively during a quiescent stage of disease, thus reducing the risks involved in emergency surgery (Table 2).

Analysis of our and other published experiences allowed us to establish a decision-making algorithm for patients with acute diverticulitis (Figure 2).

4. Discussion

Our experience shows that a decision-making algorithm is very useful to establish the correct treatment for patient with acute diverticulitis. After disease diagnosis and staging using Wasvary's revised version of the Hinchey staging system, it is possible to proceed as follow below.

4.1. Hinchey Stage III/IV with septic shock

In the case of patients in Hinchey Stage III or IV, it is necessary to determine whether there are any signs of septic shock: hypothermia (body temperature $<36^{\circ}\text{C}$) or fever (body temperature $>38^{\circ}\text{C}$); heart rate $>90/\text{min}$; leucocytosis (white blood cells $>12000/\mu\text{L}$) or leukopenia (white blood cells $<4000/\mu\text{L}$); tachypnea (respiratory rate >20 breaths/min) or $\text{PaCO}_2 <4$ kPa.

In the presence of signs of septic shock, preoperative optimisation is necessary. This takes 2–3 h and involves: the placement of two large-bore intravenous lines for the infusion of broad-spectrum antibiotics and a bolus of isotonic crystalloid (20 mL/kg); the US-guided establishment of a central line via the internal jugular for the administration of fluids until central venous pressure is between 8 and 12 mmHg; the placement of an arterial line; tracheal intubation and mechanical ventilation (target tidal volume 6 mL/kg); the administration of norepinephrine in order to maintain a mean arterial pressure of >65 mmHg; the correction of electrolyte abnormalities; the infusion of blood cells if haematocrit is $<30\%$ ^[28].

After preoperative optimisation, the patient should be re-evaluated and, if still in septic shock, should undergo DCS which consists of abdominal cavity lavage, limited bowel resection of the inflamed perforated colon using staplers, without colostomy or anastomoses, temporary abdominal vacuum-assisted closure. The patient is then returned to the ICU for treatment to improve vital parameters and allow the second and final operation after 24–48 h.

Reconstructive surgery may consist of abdominal cavity lavage and colostomy. According to Kafka-Ritsch *et al.*^[29] and Perathoner *et al.*^[30], after evaluating the condition of the colon (oedema and perfusion) and the patient's comorbidities, bowel continuity can be restored with or without a loop ileostomy.

DCS allows sepsis to be controlled by resecting the perforated bowel tract: by avoiding the dissection of tissues and organs, this reduces the risk of propagating the inflammatory process and spreading toxæmia. The stapled resection limited to the diseased bowel and the dead-end maintenance of the stumps also limits the spread of inflammation and contamination of the retroperitoneal space. Another advantage of DCS is that it allows the restoration of intestinal continuity using a primary anastomosis in patients who, without DCS, would undergo HP because of the severity of the disease, inflammation of the bowel tract, and contamination.

4.2. Hinchey Stage III/IV without septic shock

In the case of patients in Hinchey Stage III or IV without any signs of septic shock, or in whom preoperative optimisation has resolved previous septic shock, it is possible to select: Hartmann's procedure; primary resection with anastomosis; laparoscopic lavage and drainage. The choice of the most appropriate technique depends on: the severity of the disease; the condition of the intestine to anastomose (inflammation, vascularisation); the patient's clinical condition (nutritional status, comorbidities); the experience of the surgical team.

HP was long considered the gold standard for perforated diverticulitis with peritonitis, and is still used even though it leads to high mortality and morbidity rates, and bowel continuity cannot be restored in 20%–50% of patients because of the serious operative risks. However, its still frequent use is justified by the fact that removing the diseased colon and avoiding the anastomosis of the infected and inflamed colonic tract reduce the risk of anastomotic leakage; furthermore, it is still a good choice for unstable patients and the elderly with serious comorbidities insofar as it reduces the duration of surgery and peritoneal contamination.

The PRA is preferred to HP in selected cases because: it reduces mortality rate; it is associated with fewer postoperative complications; it decreases the duration of hospitalisation; it avoids the need for a second operation in order to restore intestinal continuity, which involves many operative risks^[31].

The most serious complication of PRA is anastomotic leakage due to the suture being made on an insufficiently prepared, inflamed and infected colon. In an emergency, the preparation of the bowel can be replaced by colon lavage on the operating table, which reduces the risk of infection and faecal load on the anastomosed intestinal tracts^[32,33]. A loop ileostomy is an important means of decreasing the risk of anastomotic leakage^[34,35].

LLD has been developed in an attempt to reduce HP-related mortality and morbidity. It involves an abdominal cavity lavage and the laparoscopic placement of drainages in addition to the administration of intravenous antibiotics.

The advantages of LLD are: it reduces the risk of colon resection in an acute situation; it reduces painful symptoms; it avoids a stoma; it rapidly improves the patient's clinical condition and reduces the duration of hospitalisation; elective colon resection using a minimally invasive procedure reduces the mortality and morbidity (infection and wound dehiscence, anastomosis dehiscence, post-incisional hernia) associated with emergency surgery^[18,36].

LLD is an effective and safe means of treating Stage III diverticulitis^[37,38], with an efficacy rate of 95.7%, a morbidity rate of 10.4%, and a mortality rate of 1.7%^[39].

Moreover, associated with laparoscopic sigmoid closure, it can also be used in patients in Stage IV. The sigmoid perforation can be closed using Lambert's technique and discontinuously delayed absorbance sutures, and further buttressed using Graham's patch-like technique and a piece of epiploic appendix^[40].

4.3. Hinchey Stage IB and II

Patients in Hinchey Stage IB and II can be treated in two different ways: 1) in the case of abscesses <3 cm with no evidence of pneumoperitoneum, they should be treated using conservative medical therapy: complete bowel rest and the start of

parenteral feeding; the placement of a NGT tube in the case of nausea and vomiting, or abdominal distension; the administration of intravenous antibiotics providing empiric coverage against Gram-negative and aerobic pathogens. The first-choice antibiotics are: ampicillin–sulbactam (3 g four times daily *i.v.*), piperacillin–tazobactam (3.375 or 4.5 g four times daily *i.v.*), ticarcillin–clavulanate (3.1 g four times daily *i.v.*), ceftriaxone (1 g once daily *i.v.*) plus metronidazole (500 mg three times daily *i.v.*). The second-choice antibiotics are: ciprofloxacin (400 mg twice daily *i.v.*) plus metronidazole (500 mg three times daily *i.v.*), levofloxacin (500 or 750 mg once daily *i.v.*) plus metronidazole (500 mg three times daily *i.v.*), imipenem–cilastatin (500 mg four times daily *i.v.*), meropenem (1 g three times daily *i.v.*), doripenem (500 mg three times daily *i.v.*), and ertapenem (1 g once daily *i.v.*). Antibiotic doses should be appropriately adjusted for patients with renal insufficiency or other dose-related problems^[41]. 2) in case of abscess of >3 cm, they should be treated using the conservative medical therapy described and the positioning of PCD.

PCD can be positioned under US or CT guidance through the anterior or lateral abdominal wall, or transgluteally, transperineally, transvaginally or transanally.

The catheter is left in place until the drained material is <10 mL/24 h, but not for more than 30 days. The patients' clinical condition generally improves after 24–48 h, but emergency surgery is necessary if it worsens^[42]. PCD has a failure rate between 15% and 30%, and the rate of recurrence is 40%^[43], and higher in the case of abscesses of >5 cm^[44].

The advantages of PCD are: it allows the conservative treatment of sepsis; it reduces the risk of emergency surgery by favouring elective resection with primary colorectal anastomosis^[45].

4.4. Hinchey Stage 0 and IA

Patients in Hinchey Stage 0 and IA experience an uncomplicated attack of acute diverticulitis, and can be treated as inpatients or outpatients.

Patients with uncomplicated diverticulitis can be treated in an outpatient setting if: they can be relied on to return for a medical re-evaluation if the condition worsens; they comply with an outpatient treatment plan; the abdominal pain is not severe; they have low-grade fever (<38 °C/100.4 °F); they can tolerate oral intake; they have minimal comorbidities. Elderly and immunosuppressed patients should generally be hospitalised.

Outpatient treatment involves: the consumption of only clear liquids until a clinical improvement is clear (usually two or three days), after which the diet can be slowly normalised; the administration of oral antibiotics against Gram-negative rods and anaerobes (particularly *Escherichia coli* and *Bacteroides fragilis*) for 7–14 days; bed rest. The first-choice antibiotics are: ciprofloxacin (500 mg twice daily *p.o.*) plus metronidazole (500 mg three times daily *p.o.*), amoxicillin–clavulanate (875/125 mg twice daily *p.o.*), sulfamethoxazole–trimethoprim (800/160 mg twice daily *p.o.*) plus metronidazole (500 mg three times daily *p.o.*). For patients intolerant to metronidazole, clindamycin (400 mg three times daily *p.o.*) or moxifloxacin (400 mg once daily *p.o.*) may be an acceptable alternative. Antibiotic doses should be appropriately adjusted for patients with renal insufficiency or other dose-related problems^[46].

Outpatients should be advised to return to hospital if they feel increasing pain and fever and/or develop intolerance to fluids.

In-patients should undergo conservative therapy, including: the consumption of only clear liquids, or complete bowel rest and the start parenteral feeding if oral feeding is not tolerated; the placement of an NGT in the case of nausea and vomiting, or abdominal distension; the administration of intravenous antibiotics providing empiric coverage against Gram-negative and aerobic pathogens.

Intravenous antibiotics should be administered until the inflammation has stabilised, and pain and tenderness are decreasing (typically 3–5 days after starting treatment), after which the patient can be switched to oral antibiotics in order to complete 10–14 days of antibiotic therapy. The first-choice antibiotics are: ciprofloxacin (400 mg twice daily *i.v.* or 500 mg twice daily *p.o.*) plus metronidazole (500 mg three times daily *i.v.* or 500 mg three times daily *p.o.*), amoxicillin–clavulanate (1000/200 mg three times daily *i.v.* or 875/125 mg twice daily *p.o.*), sulfamethoxazole–trimethoprim (750/150 mg four times daily *i.v.* or 800/160 mg twice daily *p.o.*) plus metronidazole (500 mg three times daily *i.v.* or 500 mg three times daily *p.o.*). For patients intolerant to metronidazole, clindamycin (300 mg three times daily *i.v.* or 400 mg three times daily *p.o.*) or moxifloxacin (400 mg once daily *i.v./p.o.*) may be an acceptable alternative. Antibiotic doses should be appropriately adjusted for patients with renal insufficiency or other dose-related problems^[47,48].

Anticholinergic drugs and antispasmodics can decrease the pain by decreasing muscle contractions and, in cases of more persistent pain, meperidine may be used. Morphine is not indicated because it has the effect of increasing colic pressure.

Once the acute phase is over, the patients should be advised to follow a high-fibre diet because a long-term high-fibre diet can reduce the incidence of disease recurrences.

Because of the risk of the recurrence of acute diverticulitis, all patients in Hinchey Stage 0, IA, IB, II and III treated with PCD or LLD must be followed up, and need to be checked after 4–6 weeks in order to evaluate the need for surgical resection.

Conflict of interest statement

The authors report no conflict of interest.

References

- [1] World Gastroenterology Organisation. World Gastroenterology Organisation practice guidelines: diverticular disease. Milwaukee: World Gastroenterology Organisation; 2007. [Online] Available from: http://www.worldgastroenterology.org/assets/downloads/en/pdf/guidelines/07_diverticular_disease.pdf [Accessed on 25th March, 2015]
- [2] Nguyen GC, Sam J, Anand N. Epidemiological trends and geographic variation in hospital admission for diverticulitis in the United States. *World J Gastroenterol* 2011; **17**(12): 1600-5.
- [3] Etzioni DA, Mack TM, Beart RW Jr, Kaiser AM. Diverticulitis in the United States 1998-2005: changing patterns of disease and treatment. *Ann Surg* 2009; **249**(10): 210-7.
- [4] Parks TG. Natural history of diverticular disease of the colon. A review of 521 cases. *Br Med J* 1969; **4**(5684): 639-42.
- [5] Hinchey EJ, Schaal PG, Richards GK. Treatment of perforated diverticular disease of the colon. *Adv Surg* 1978; **12**: 85-109.
- [6] Wasvary H, Turfah F, Kadro O, Beaugard W. Same hospitalization resection for acute diverticulitis. *Am Surg* 1999; **65**(7): 632-5.
- [7] Vermeulen J, Lange JF. Treatment of perforated diverticulitis with generalized peritonitis: past, present and future. *World J Surg* 2010; **34**(3): 587-93.

- [8] Mayo WJ, Wilson LB, Griffin HZ. Acquired diverticulitis of the large intestine. *Surg Gynecol Obstet* 1907; **5**: 8-15.
- [9] Large JM. Treatment of perforated diverticulitis. *Lancet* 1964; **1**(7330): 413-4.
- [10] Hartmann H. [New resection's technique of the end part of the pelvic colon]. In: Thirtieth Congress of Surgery; 1921; Strasbourg, France. 1921, p. 411-3. French.
- [11] Auguste L, Borrero E, Wise L. Surgical management of perforated colonic diverticulitis. *Arch Surg* 1985; **120**(4): 450-2.
- [12] Auguste LJ, Wise L. Surgical management of perforated diverticulitis. *Am J Surg* 1981; **141**(1): 122-7.
- [13] Wigmore SJ, Duthie GS, Young IE, Spalding EM, Rainey JB. Restoration of intestinal continuity following Hartmann's procedure: the Lothian experience 1987-1992. *Br J Surg* 1995; **82**(1): 27-30.
- [14] Alizai PH, Schulze-Hagen M, Klink CD, Ulmer F, Roeth AA, Neumann UP, et al. Primary anastomosis with a defunctioning stoma versus Hartmann's procedure for perforated diverticulitis a comparison of stoma reversal rates. *Int J Colorectal Dis* 2013; **28**(12): 1681-8.
- [15] Swank HA, Mulder IM, Hoofwijk AG, Nienhuijs SW, Lange JF, Bemelman WA, et al. Early experience with laparoscopic lavage for perforated diverticulitis. *Br J Surg* 2013; **100**(5): 704-10.
- [16] Soumian S, Thomas S, Mohan PP, Khan N, Khan Z, Raju T. Management of Hinchey II diverticulitis. *World J Gastroenterol* 2008; **14**(47): 7163-9.
- [17] Durmishi Y, Gervaz P, Brandt D, Bucher P, Platon A, Morel P, et al. Results from percutaneous drainage of Hinchey stage II diverticulitis guided by computed tomography scan. *Surg Endosc* 2006; **20**(7): 1129-33.
- [18] Franklin ME Jr, Portillo G, Treviño JM, Gonzalez JJ, Glass JL. Long-term experience with the laparoscopic approach to perforated diverticulitis plus generalized peritonitis. *World J Surg* 2008; **32**(7): 1507-11.
- [19] Stone HH, Strom PR, Mullins RJ. Management of the major coagulopathy with onset during laparotomy. *Ann Surg* 1983; **197**(5): 532-5.
- [20] Moore LJ, Turner KL, Jones SL, Fahy BN, Moore FA. Availability of acute care surgeons improves outcomes in patients requiring emergent colon surgery. *Am J Surg* 2011; **202**(6): 837-42.
- [21] Stawicki SP, Brooks A, Bilski T, Scaff D, Gupta R, Schwab CW, et al. The concept of damage control: extending the paradigm to emergency general surgery. *Injury* 2008; **39**(1): 93-101.
- [22] McConnell EJ, Tessier DJ, Wolff BG. Population-based incidence of complicated diverticular disease of the sigmoid colon based on gender and age. *Dis Colon Rectum* 2003; **46**(8): 1110-4.
- [23] Young-Fadok TM, Roberts PL, Spencer MP, Wolff BG. Colonic diverticular disease. *Curr Probl Surg* 2000; **37**(7): 457-514.
- [24] Ngoi SS, Chia J, Goh MY, Sim E, Rauff A. Surgical management of right colon diverticulitis. *Dis Colon Rectum* 1992; **35**(8): 799-802.
- [25] Schoetz DJ. Diverticular disease of the colon: a century-old problem. *Dis Colon Rectum* 1999; **42**(6): 703-9.
- [26] Dharmarajan S, Hunt SR, Birnbaum EH, Fleshman JW, Mutch MG. The efficacy of nonoperative management of acute complicated diverticulitis. *Dis Colon Rectum* 2011; **54**(6): 663-71.
- [27] Binda GA, Arezzo A, Serventi A, Bonelli L, Italian Study Group on Complicated Diverticulosis (GISDIC), Facchini M, et al. Multicentre observational study of the natural history of left-sided acute diverticulitis. *Br J Surg* 2012; **99**(2): 276-85.
- [28] Dellinger RP, Levy MM, Rhodes A, Annane D, Gerlach H, Opal SM, et al. Surviving sepsis campaign: international guidelines for management of severe sepsis and septic shock: 2012. *Crit Care Med* 2013; **41**(2): 580-637.
- [29] Kafka-Ritsch R, Birkfellner F, Perathoner A, Raab H, Nehoda H, Pratschke J, et al. Damage control surgery with abdominal vacuum and delayed bowel reconstruction in patients with perforated diverticulitis Hinchey III/IV. *J Gastrointest Surg* 2012; **16**(10): 1915-22.
- [30] Perathoner A, Klaus A, Mühlmann G, Oberwalder M, Margreuter R, Kafka-Ritsch R. Damage control with abdominal vacuum therapy (VAC) to manage perforated diverticulitis with advanced generalized peritonitis—a proof of concept. *Int J Colorectal Dis* 2010; **25**(6): 767-74.
- [31] Garber A, Hyman N, Osler T. Complications of Hartmann take-down in a decade of preferred primary anastomosis. *Am J Surg* 2014; **207**(1): 60-4.
- [32] Murray JJ, Schoetz DJ Jr, Collier JA, Roberts PL, Veidenheimer MC. Intraoperative colonic lavage and primary anastomosis in nonelective colon resection. *Dis Colon Rectum* 1991; **34**(7): 527-31.
- [33] Stewart J, Diament RH, Brennan TG. Management of obstructing lesions of the left colon by resection, on-table lavage, and primary anastomosis. *Surgery* 1993; **114**(3): 502-5.
- [34] Gawlick U, Nirula R. Resection and primary anastomosis with proximal diversion instead of Hartmann's: evolving the management of diverticulitis using NSQIP data. *J Trauma Acute Care Surg* 2012; **72**(4): 807-14.
- [35] Tadlock MD, Karamanos E, Skiada D, Inaba K, Talving P, Senagore A, et al. Emergency surgery for acute diverticulitis: which operation? A National Surgical Quality Improvement Program Study. *J Trauma Acute Care Surg* 2013; **74**(6): 1385-91.
- [36] Afshar S, Kurer MA. Laparoscopic peritoneal lavage for perforated sigmoid diverticulitis. *Colorectal Dis* 2012; **14**(2): 135-42.
- [37] Myers E, Hurley M, O'Sullivan GC, Kavanagh D, Wilson I, Winter DC. Laparoscopic peritoneal lavage for generalized peritonitis due to perforated diverticulitis. *Br J Surg* 2008; **95**(1): 97-101.
- [38] Rogers AC, Collins D, O'Sullivan GC, Winter DC. Laparoscopic lavage for perforated diverticulitis: a population analysis. *Dis Colon Rectum* 2012; **55**(9): 932-8.
- [39] Toorenvliet BR, Swank H, Schoones JW, Hamming JF, Bemelman WA. Laparoscopic peritoneal lavage for perforated colonic diverticulitis: a systematic review. *Colorectal Dis* 2010; **12**(9): 862-7.
- [40] Liang S, Russek K, Franklin ME Jr. Damage control strategy for the management of perforated diverticulitis with generalized peritonitis: laparoscopic lavage and drainage vs laparoscopic Hartmann's procedure. *Surg Endosc* 2012; **26**(10): 2835-42.
- [41] Brandt D, Gervaz P, Durmishi Y, Platon A, Morel P, Poletti PA. Percutaneous CT scan-guided drainage vs. antibiotic therapy alone for Hinchey II diverticulitis: a case-control study. *Dis Colon Rectum* 2006; **49**(10): 1533-8.
- [42] Sallinen VJ, Mentula PJ, Leppaniemi AK. Nonoperative management of perforated diverticulitis with extraluminal air is safe and effective in selected patients. *Dis Colon Rectum* 2014; **57**(7): 875-81.
- [43] Kaiser AM, Jiang JK, Lake JP, Ault G, Artinyan A, Gonzalez-Ruiz C, et al. The management of complicated diverticulitis and the role of computed tomography. *Am J Gastroenterol* 2005; **100**(4): 910-7.
- [44] Gaertner WB, Willis DJ, Madoff RD, Rothenberger DA, Kwaan MR, Belzer GE, et al. Percutaneous drainage of colonic diverticular abscess: is colon resection necessary? *Dis Colon Rectum* 2013; **56**(5): 622-6.
- [45] Elagili F, Stocchi L, Ozuner G, Dietz DW, Kiran RP. Outcomes of percutaneous drainage without surgery for patients with diverticular abscess. *Dis Colon Rectum* 2014; **57**(3): 331-6.
- [46] Biondo S, Golda T, Kreisler E, Espin E, Vallribera F, Oteiza F, et al. Outpatient versus hospitalization management for uncomplicated diverticulitis: a prospective, multicenter randomized clinical trial (DIVER Trial). *Ann Surg* 2014; **259**(1): 38-44.
- [47] Morris AM, Regenbogen SE, Hardiman KM, Hendren S. Sigmoid diverticulitis: a systematic review. *JAMA* 2014; **311**(3): 287-97.
- [48] Welbourn HL, Hartley JE. Management of acute diverticulitis and its complications. *Indian J Surg* 2014; **76**(6): 429-35.