

Neonatal brain abscess: A surgical series

Artur Xhumari^{1,4}, Geldon Fejzo¹, Aida Bushati^{2,4}, Aferdita Tako²,
Valentina Tashko², Gjergji Vreto^{3,4}, Mentor Petrela^{1,4}

¹Service of Neurosurgery, UHC “Mother Teresa”, Tirana, Albania

²Service of Pediatrics, UHC “Mother Teresa”, Tirana, Albania

³Service of Imaging, UHC “Mother Teresa”, Tirana, Albania

⁴Faculty of Medicine, University of Medicine, Tirana, Albania

Corresponding author: Artur Xhumari, MD, PhD

Address: Str. Kongresi i Manastirit, 270, Tirana, Albania;

Telephone: +355692041867; E-mail: artur.xhumari@icloud.com

Abstract

Aim: To describe the neonatal cerebral abscess cases treated surgically and identify factors to a better outcome.

Methods: Retrospective study of neonatal brain abscesses surgically treated in the Service of Neurosurgery, Mother Teresa University Hospital Centre, Tirana, Albania.

Results: We found five cases of neonatal cerebral abscesses, diagnosed on a mean 5.4 weeks after birth (range: 1-8 weeks) which developed in the absence of trauma, prior surgery, mothers' disease or immune defect. The abscesses, which debuted with sepsis (4/5 of patients) and meningitis in one case, preferring periventricular localization, were surgically evacuated through burr-hole and subsequently treated with antibiotics for a 6-week period. The mortality in our casuistic was zero, but morbidity should be evaluated in longer terms. There was, on average, eight weeks delay in the diagnosis. We found that trans-fontanelle ultrasound was unnecessary, accompanied with a reluctance to perform CT/MRI which was one of the main causes for the diagnosis delay, others being mainly the late onset of the symptoms.

Conclusions: Neonatal brain abscesses are a serious and potentially life-threatening intracranial disease. There is a need for increased awareness and close collaboration amid pediatricians, neurosurgeons and neuroradiologists for earlier neuroimaging in cases of neonatal sepsis with probable cerebral involvement. Even though mortality has decreased, morbidity still remains a challenge.

Keywords: cerebral abscess, imaging, neonatal, surgery.

Introduction

Cerebral abscesses in neonates are relatively large lesions, with a non-complete capsule formation. Characterized by a rapid growth, these lesions have preferential periventricular localization.

The main etiopathogenetic cause is the complication of bacterial meningitis. Among other causes the literature reports cranial trauma, otitis media, congenital heart disease and other causes such as dermal sinus, immune problems, etc (1,2).

The most common pathogens are gram-negative organisms, such as citrobacter and Proteus. Others are Pseudomonas serrata, the golden staphylococcus, streptococcus and Klebsiella (1-4).

Neonatal abscesses are often diagnosed late due to the delayed onset of the symptoms. Usually, in neonates these lesions present with epileptic seizures, inflammatory syndrome, increased intracranial pressure and augmentation of cranial perimeter with the fontanels inflated.

Cerebral abscesses pass through four stages ranging from early cerebritis to late capsule formation. Usually these lesions begin around the end of the second week after initial infection and last from several weeks to several months. Radiologic characteristic of these lesions, resembling to those in adult age, consist of a ring-shaped enhancing lesions with perifocal edema (1,2). The differential diagnosis includes, hematoma in reabsorption, stroke, trombosed vascular malformations (1,2) - while primary and secondary cerebral tumors and demyelination focal diseases are less frequent in this age. The MR sequence of diffusion is a sensitive method for the differentiation of necrotic-cystic tumors from abscesses (1-4). Pyogenic abscesses usually are hyperintense in the diffusion sequence and ADC values lower in the ADC maps, which coincide with the restriction of water molecules in the relatively viscous material of the abscess. On the other hand, findings in solido-cystic tumors are usually the opposite; hipointense in diffusion and hiperintense and high ADC values, characteristics that coincide with the increased mobility of water molecules in these lesions (1-4). Cerebral abscesses have a high propensity to rupture in the lateral ventricles, which is the eventuality of a bad prognosis.

The current treatment for cerebral abscess involves combined medical and surgical therapy. Even though mortality has decreased, the morbidity remains still high.

The aim of this study was to increase the awareness of practitioners caring for the neonates towards brain abscess by describing the clinical characteristics, treatment and outcome of neonates with brain abscess. The objectives were to find predisposing factors associated with neonatal cerebral abscess formation, define the best imaging modality for an earlier diagnosis, best treatment strategy and how to improve the outcome of the disease.

Methods

We retrospectively studied our database from September 2011 until August 2012, and found five children treated for cerebral abscess, at the Neurosurgery Department of "Mother Teresa" University Hospital Center, Tirana, Albania.

Results

Perinatal History: There is no anomaly referred during pregnancy. As seen in Table 1, gestational period was normal in two patients (38-39 weeks) and abnormal in three of them (34-37 weeks). - Three children were born <2000 g (1800-1900g), while two were born with normal weight. - Premature rupture of membranes, which occurs more than 24 h before birth, was not registered in any case. All children had a normal, transvaginal birth. General and neurologic examination of the children was described as normal in all of the five cases.

Clinical findings: Three children were female and two males. The beginning of the symptoms occurred in all cases in the first week of birth (day 1-5). Initial manifestation of the disease was gonitis in two cases associated with sepsis, which is referred in other four cases. In one case, instead, the disease began with meningitis. Signs of the presentation were fever in three cases, in two cases macrocrania, whereas irritability was noted in a single case. None of the neonates had convulsive crisis.

Bacteriology: The bacteriologic examination in all cases returned sterile. The reason of this result was the antibiotic therapy before the settlement of the

Table 1. Patients' characteristics

Patients Characteristics	
Sex	
Male	3/5 patients
Female	2/5 patients
Birth weight	
<2000 g	3/5 patients
>2000 g	2/5 patients
Gestational weeks	
mean	36.2 weeks
range	34-39 weeks
Initial diagnosis	
Sepsis	4/5 patients
Meningitis	1/5 patients
Time of the initial symptoms (from birth)	
mean	2.2 days
range	1-5 days
Days of treatment before abscess diagnosis	
mean	12 days
range	0-35 days
Age on abscess diagnosis	
Mean	5.4 weeks
range	1-8 weeks
Presentation (signs)	
Fever	3/5 patients
Macrocrania	2/5 patients
Irritability	1/5 patient
Initial radiologic modality	
TF Ultrasound	3/5 patients
CT	2/5 patients
MRI	2/5 patients
Diagnostic Radiologic modality	
CT	4/5 patients
MRI	5/5 patients
Surgical evacuation	
Amount of purulent material evacuated, mean	54 cc
Range	30-100 cc
Bacteriologic examination	
sterile	5/5 patients

diagnosis (0-35 days, median 12 days).

Abscess localization: The localization and the number of the abscesses was initially studied with trans-fontanellar ultrasound (4/5 patients), while the diagnosis was established with head CT (4/5 cases) and confirmed by MRI (5/5 cases). One case presented bifrontal abscesses. All the abscesses were of large dimensions. One typical aspect was their periventricular localization, in direct contact with the

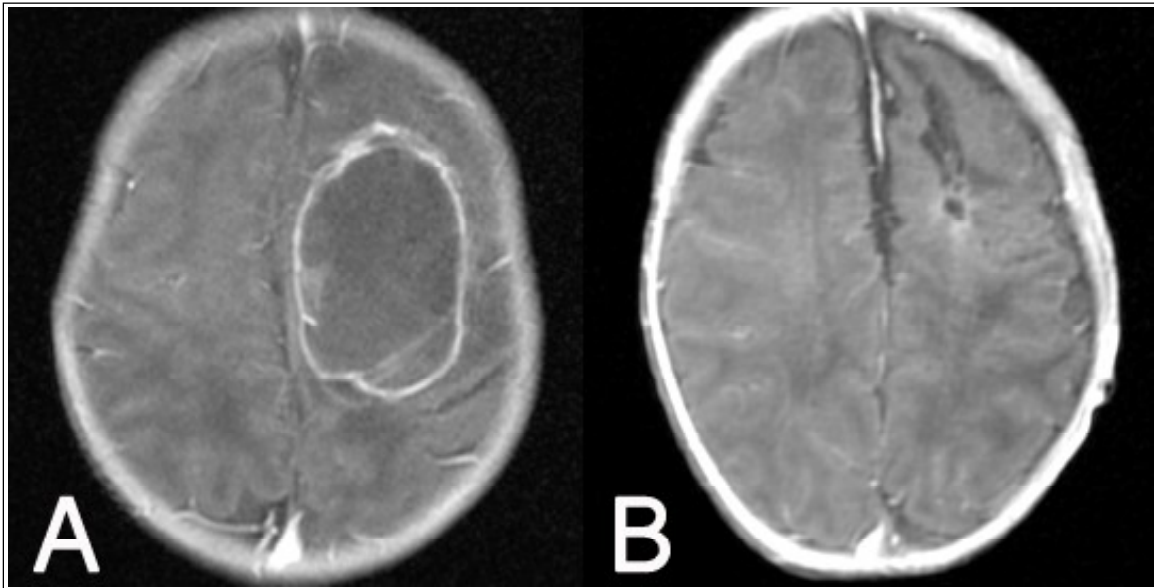
lateral ventricles.

Treatment: Abscesses were treated with surgical evacuation and antibiotics in all cases. An average of 54 cc purulent material was evacuated (30-100 cc). The antibiotic therapy included Imipenem (5/5 cases) associated with Flagyl (4/5 cases) and in one case Vankomicine. Gentamicine, instead of vancomicine was used in another case. The treatment period was six weeks in all cases.

Outcome: The postoperative course was uneventful. No death was recorded in our database. All patients were followed with head CT during antibiotics treatment and with MRI after completion of therapy. In all cases a radiologic improvement was

seen with a dramatic reduction of the lesions dimensions. Figure 1 shows the MRI images before and after surgical evacuation followed by intravenous antibiotics.

Figure 1. Pre operative magnetic resonance image (A) showing a large left fronto-parietal abscess with surrounding edema. Post operative image (B) showing only a very small residual cavity after surgical evacuation and parenteral antibiotic course



Discussion

Neonatal cerebral abscesses, for the first time described by Hinsdale in 1989, are considered a rare entity (5) but being destructive lesions, an early diagnosis with a prompt treatment is needed to avoid the important neurological sequels, which these lesions carry. The improved imaging techniques have helped settling the diagnoses, but the lack of the symptoms in this age group make these lesions with a high rate of mortality.

We looked at the gestational age and birth weight, but found that the abscess occurred equally among preterm and term neonates as well as among low birth weight and normal ones. This findings run against the common sense that a low weight and premature neonate has less competent defence mechanisms, hence is more prone to infection. More patients are needed to verify this trends we found. The responsible pathogens, reported by the literature, are gram - and are often associated with meningitis,

aspects that are not found in the abscesses of adult children (6-11). Graham and Band reported that 77% of the meningitis is caused by citrobacter, the main responsible pathogen, turning into abscesses (7). In our series, the blood and evacuated cultures turned out sterile probably because the antibiotics regime was already started. Even though the most common pathogens are known, it is essential to know the exact pathogen and antimicrobial sensitivity for a targeted treatment. Therefore we strongly advice against the current reported practice of beginning the antibiotherapy before obtaining material for culture.

The way to the CNS infection is controversial. Theoretically, the infection can follow two pathways: the hematogenous and the liquoral way. In our cases sepsis was observed in 4/5 patients, making the convincing hypothesis of a colonization of cerebral parenchima during septicemia, supported

by other studies as well (12-14). Another postulate suggests that a primary lesion is a necrotic vasculitis in the white substance, which is then invaded by the bacteria, a characteristic aspect of *Proteus* and *Citrobacter* (15). Prematurity and maternal infections are the main infections pathways, but in our database this was not reported. In the literature the propensity of these organisms to colonise water sources, incubators, and respiratory equipments has been emphasised as well. An important aspect of our study was the delay in the diagnosis, on average 8 weeks. We noticed that trans-fontanelle ultrasound was unnecessary, accompanied with a reluctance to perform CT/MRI, which was one of the main causes for the diagnoses delay, others being mainly the late onset of the symptoms. It is important to perform a neuroimaging study always when a cerebral abscess is suspected or when the probability of developing one is high, as in meningitis in neonates.

Renier et al. reported that the good prognostic factors in neonatal brain abscesses are sterile CSF, normal ventricle on CT scan, absence of seizures and early aspiration of the abscess (16). In our casuistics the mortality was zero, so confirming the postulate of Renier et al., but emphasizing the importance of early diagnoses and the treatment

through abscess evacuation. While mortality was zero, morbidity is not known, a very important aspect, which will be followed up in time by monitoring the cognitive functions as an important parameter in the quality of life. Carey et al. reported impaired learning ability in 70% of children after 6 years from surgery, postulating a worse prognosis for intellectual development if the children at the time of the diagnosis were younger (17). Longer follow-up of our series is needed to better understand the late psychological outcome.

Conclusion

If faced with a febrile syndrome in a neonate, meningitis or an abscess should be taken in consideration, because of their characteristic appearance of hiding symptoms. If fever returns, an urgent cranial CT/MRI must be performed looking towards the meningitis or the abscess. Moreover, an important clue is the close collaboration among the pediatrics, neurosurgeons and neuroradiologists. The aim is to reduce the incidence of cerebral abscess, which is reached by their early diagnosis and their successful treatment. In this way, besides reducing the mortality, the morbidity reduction will be achieved as well.

Conflicts of interest: None declared.

References

1. Barkovich AJ. Pediatric neuroimaging. Lippincott Williams & Wilkins, Philadelphia; 2000:741-4.
2. Osborn AG. Diagnostic Neuroradiology. Mosby, St. Louis; 1994:688-94.
3. Teixeira J, Zimmerman RA, Haselgrove JC, Bilaniuk LT, Hunter JV. Diffusion Imaging in pediatric central nervous system infections. *Neuroradiology* 2001;43:1031-9.
4. Basu S, Mukherjee KK, Poddar B, Goraya JS, Chawla K, Parmar VR. An unusual case of neonatal brain abscess following *Klebsiella Pneumonia* septicemia. *Infection* 2001;29:283-5.
5. Hinsdale G. Purulent encephalitis and cerebral abscess in the newborn due to infection through the umbilicus. *Am J Med Sci* 1899;118:280-3.
6. Dulac O, Diebler C, Figueroa D, Arthuis M. La scanographie dans le meningitis purulentes du nouveau-ne. *Presse Med* 1984;13:201-4.
7. Graham DR, Band JD. *Citrobacter diversus* brain abscesses and meningitis in neonates. *JAMA* 1981; 245:1923-5.
8. Hoffman HJ, Hendrick EB, Hiscox JL. Cerebral abscess in early infancy. *J Neurosurg* 1970;33:172-7.
9. Montoya F, Contal M, Sibille G, Huret C, Frerebeau P, Bonnet H. Abces du cerveau en periode neonatal. *Arch Fr Pediatr* 1987;44:35-8.
10. Munslow RA, Stovall VS, Price RD, Kohler CM. Brain abscess in infants. *J Pediatr* 1957;51:74-9.
11. Smith ML, Mellor D. *Proteus mirabilis* meningitis

- and cerebral abscess in the newborn period. Arch Dis Child 1980;55:308-10.
12. Chevie JJ, Aicardi J, Dhaussy C, Thieffry S. Les méningites purulentes du nouveauné. Arch Fr Pediatr 1968;25:849-70.
 13. Cussen LJ, Ryan GB. Hemorrhagic cerebral necrosis in neonatal infants with enterobacterial meningitis. J Pediatr 1976;71:771-6.
 14. McCracken GH, Shinefield HR. Changes in the pattern of neonatal septicemia and meningitis. Am J Dis Child 1966;112:33-9.
 15. Foreman SD, Smith EE, Ryan NJ, Hogan GR. Neonatal Citrobacter meningitis: pathogenesis of cerebral abscess formation. Ann Neurol 1984; 16:655-9.
 16. Renier D, Flandin C, Hirsch E, Hirsch JF. Brain abscesses in neonates. J Neurosurg 1988;69:877-82.
 17. Carey ME, Chou SN, French LA. Experience with brain abscess. J Neurosurg 1972;36:1-9.