

One decade of femoral neck and trochanteric hip fractures treatment in Albania: Are we doing better?

Artid Duni¹, Vilson Ruci¹, Julian Ruci¹, Leonard Lazaj¹, Lorenc Murati¹, Erjon Sejati¹

¹Service of Orthopedics and Trauma, University Trauma Hospital, Tirana, Albania.

Corresponding author: Artid Duni, MD;
Address: National Trauma Centre, Laprake, Tirana, Albania;
Telephone: +355692057764; E-mail: aduni17@yahoo.com

Abstract

Aim: Fractures of the femoral neck, femoral head and trochanteric region are among the most challenging pathologies every orthopedic surgeon has to deal with in the everyday practice, especially in a hectic tertiary trauma center. Their incidence is increasing with ageing of the population and lifestyle changes towards sedentary life and motor vehicle use.

Methods: During 2004-2014 we investigated the total number of femoral neck and trochanteric fractures treated in our facility in Tirana, Albania, in order to describe the incidence by the type of fracture (femoral neck, femoral head, transtrochanteric), the annual trend of treatment modality, the age groups affected, the hospitalization, the operability, and the mortality rate.

Results: A total number of 2180 femoral neck, femoral head and trochanteric fractures were treated in our facility during the last decade. About 49% were male patients and the mean age was 67.7 years. This constitutes 9.33% of the total number of patients treated for the same period. There were 828 (37.98%) trochanteric fracture cases, 1347 cases (61.79%) were femoral neck fractures and 5 cases (0.23%) were femoral head fractures. The modalities of treatment were as follows: 982 cases or 45% underwent partial prosthetic replacement, 704 cases or 32.29% had osteosynthesis with different forms of plates and/ or screws, 0.73% cases were treated with total hip replacement and 478 cases or 21.93% were treated conservatively. Overall, inpatient mortality was 1.33%.

Conclusion: The incidence of femoral neck and trochanteric fractures in the older age groups is increasing every year. The modalities of treatment are oriented towards modern protocols and the operability is increasing year by year. Lower hospitalization and higher operability should be our future goals in Albania.

Keywords: femoral neck, hip fracture treatment, transtrochanteric.

Introduction

Hip fractures, and especially femoral neck and trochanteric region fractures are of the most difficult pathologies to treat and often pose serious surgical challenges to any orthopedic surgeon. This task becomes more difficult with the ageing of the population, changes in lifestyle and taking into account the often-limited financial and logistic capabilities of a tertiary center of a developing country such as Albania, a former communist country in the Western Balkans which is currently undergoing a difficult process of political and socioeconomic transition towards a market-oriented economy.

We decided to investigate the treatment modalities related to age-group for each type of fracture in Tirana, Albania, in order to compare if the trend of treatment by year stands to international standards and guidelines (1,2).

Methods

This retrospective study was performed at the University Trauma Hospital of Tirana, Albania,

which is the biggest trauma facility of the country. The inpatient registries of the Emergency Department, Operating Rooms and Orthopedic Wards were used as data sources. The study period was from 2004 to 2014 and the total number of patients treated for femoral neck, femoral head, and trochanteric fractures were included in the study. The epidemiologic indexes like total incidence, age groups, gender, but also treatment modalities by year were investigated. We studied the gender and fracture pattern by age groups dividing the patients as: pediatric (under 14 years), young adults (15-40 years), middle-aged (41-60 years), old (61-80 years) and very old (over 80 years of age). In addition, hospitalization, operability and inpatient mortality were analyzed and compared by year. The data were expressed in absolute values and percentages.

Results

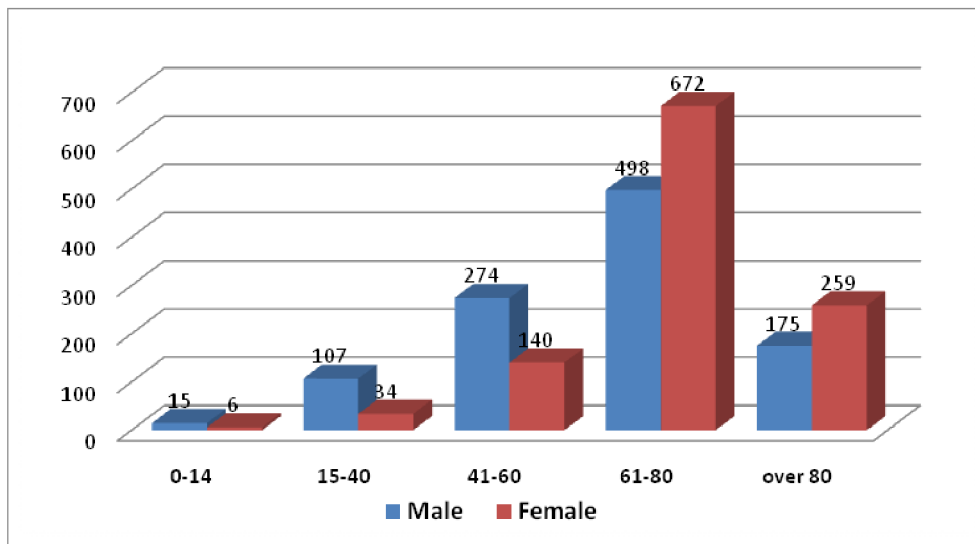
A total number of 2180 femoral neck, femoral head and trochanteric fractures were treated in our facility during the study period (Table 1).

Table 1. General epidemiological data

	Males	Females	Mean age	Age-groups				
				<15	15-40	41-60	61-80	> 80
Trochanteric	414	414	68.3	4	58	145	449	172
Femoral neck & head	655	697	67.28	17	83	269	721	262
Total	1069	1111	67.7	21	141	414	1170	434

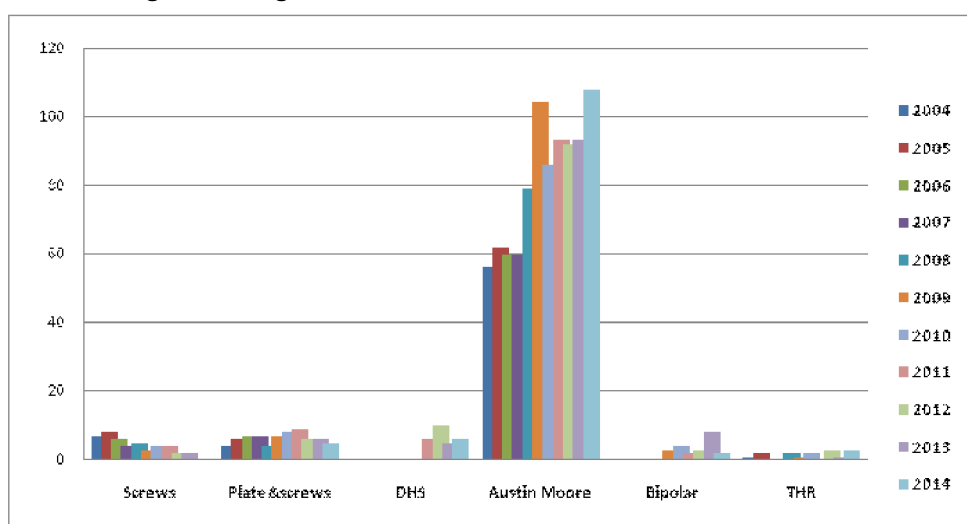
This accounts for 9.33% of all the treated cases in our facility during this period of time. The distribution by gender was nearly equal with a slight predominance of females (51%), but in different age groups we found male predominance for lower groups and significantly higher female involvement

in the upper age-groups (Figure 1). Mean age was 67.7 years. Overall, 828 cases or 37.98% were trochanteric fractures, 1347 cases or 61.79% were femoral neck fractures, and 5 cases or 0.23% were femoral head fractures.

Figure 1. Distribution of hip fractures by gender in different age-groups

Regarding the treatment the results were as follows: 982 cases or 45% underwent partial prosthetic replacement, 704 cases or 32.29% had osteosynthesis with different forms of plates and/or screws, 0.73% were treated with total hip replacement and 478 cases or 21.93% were treated conservatively. Of the 1071 operated femoral neck fractures, 45 cases (4.20%) were treated with simple screw

fixation, 69 cases (6.44%) with plate and screws, and 27 cases (2.52%) with the Harris Dynamic Hip Screw (DHS) device. On the whole, 893 cases (83.38%) were treated with Austin-Moore partial unipolar cemented endoprosthesis replacement, 22 cases (2.05%) with uncemented bipolar prosthetic replacement, and 15 cases (1.40%) underwent total hip replacement (Figure 2).

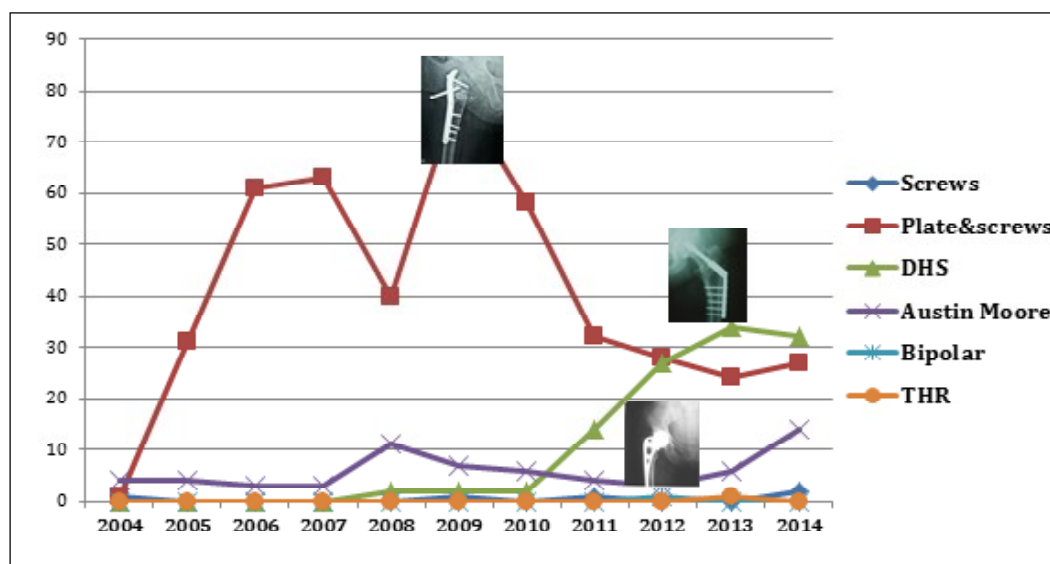
Figure 2. Surgical treatment modalities for femoral neck fractures

Regarding the surgical treatment of the trochanteric region fractures we obtained the following

results: 5 cases (0.79%) were treated with lag screws, 445 cases (70.63%) with conventional

plates and screws, 113 cases (17.94%) with the DHS fixation system, and 67 cases (10.64%) underwent different prosthetic replacements: 65 unipolar cemented replacements or 10.32%, one bipolar uncemented prosthesis or 0.16%, and one total hip replacement or 0.16% (Figure 3).

Figure 3. Surgical treatment trend for trochanteric hip fractures



Mean hospitalization time was 10.38 days starting from 14.93 days in 2004 and ending to 9.00 days in 2014. Operability rate was 78.7%, meaning 478

cases out of 2180 refused treatment or were treated conservatively. Overall inpatient mortality was 1.33% (29 hospital deaths) (Table 2).

Table 2. Hospitalization, operability and mortality by year

	2004	2005	2006	2007	2008	2009	2010	2011	2012	2013	2014
Hospitalization (days)	14.93	14.07	12.05	11.93	9.98	9.66	9.41	9.89	9.84	8.82	9.00
Operability (%)	80.43	83.82	83.54	80.12	76.06	80.62	76.58	77.46	77.78	73.47	74.81
Mortality (%)	4.35	0	1.22	1.75	3.19	0.78	1.35	0	0.89	1.22	1.50

Discussion

Looking at the general data, it is obvious that the incidence of hip fractures is increasing annually in Albania. The age distribution seems to follow the Gaussian pattern with a distinct peak at the age 60-80 years, which suggests that osteoporosis maybe their major cause (3,4). The decrease in the older age-group is probably due to the reduced level of activity for age reasons. There is a slight dominance of female sex when looking at the general pattern, but there is a significant increased

risk of fracture in older females again due to bone fragility of this age-group (5).

Regarding the options of surgical treatment, we notice significant improvement of the surgical techniques for both intra and extracapsular fractures in the course of the last decade. We are directing our treatment towards surgical options with the quickest mobilization, lower hospitalization and fewer postoperative complications as international guidelines recommend (1,2). Despite the vast

majority of femoral neck fractures being still treated with the “old” Austin-Moore prosthesis there is an increasing trend for bipolar and uncemented total hip replacements (6). The improvement is far more obvious in the treatment of trochanteric fractures. Almost every surgeon in our facility in Tirana is using the Dynamic Hip System of fixation as an efficient and modern form of surgical stabilization (7). Meanwhile, the use of intramedullary devices is in the very early stages with very few cases treated to date.

The overall hospitalization index significantly improved over the years but the operability remains very low with about one in every five cases being left unoperated and discharged from the hospital. The reasons behind this could be different, like refusing the operation from the patient or family side, vital contraindications, fear to face legal issues in the event of fatal complications from the staff, and the like. Probably, the very low mortality we report in our series is due to the low operability, as we do not have any reports from the discharged patients’ population regarding the mortality (8).

Limitations

This study has some limitations like the missing data regarding the timing of surgery as major pitfall for the treatment of those fractures. Also, subtrochanteric fractures should have been included in this study. In fact, we excluded them intentionally

Conflicts of interest: None declared.

References

1. Roberts KC, Brox WT, Jevsevar DS, Sevarino K. Management of Hip Fractures in the Elderly. *J Am Acad Orthop Surg* 2015;23:131-7.
2. NICE guidelines. The management of hip fracture in adults. NICE guidelines [CG124]; June 2011.
3. Cooper C, Campion G, Melton LJ. Hip fractures in the elderly: A world wide projection. *Osteoporosis Int* 1992;2:285-9.
4. Cummings SR, Melton LJ. Epidemiology and outcomes of osteoporotic fractures. *Lancet* 2002;359:1761-7.
5. Holt G, Smith R, Duncan K, Hutchison JD, Gregori A. Gender differences in epidemiology and outcome after hip fracture: evidence from the Scottish Hip Fracture Audit. *J Bone Joint Surg Br* 2008;90:480-3.
6. Jameson SS, Jensen CD, Elson DW, Johnson A, Nachtsheim C, Rangan A, et al. Cemented versus cementless hemiarthroplasty

because actually they are being treated like simple femoral shaft fractures and stabilized by conventional plates and screws. Finally, the missing data after the patient was discharged could influence the reported results.

Conclusions

The incidence of hip fractures in Albania follows the worldwide trend of gradual increase as the population ages and the longevity increases and the healthcare system should be aware for future challenges in this field. There is an increased risk for hip fractures for older females due to bone fragility.

If we look back to ten years before, we are doing better in Albania regarding the treatment of both types of fractures but more work needs to be done regarding the newest treatment options like cephalomedullary or gamma nail devices in order to increase their use especially for trans and subtrochanteric fractures (9,10).

We should do our best to increase the operability in Albania despite the potential higher rate of postoperative mortality.

Acknowledgement: The authors would like to thank the nursing staff of the operating room, the personnel of the orthopedic wards and the statistics unit for their precious help during the realization of this study.

- for intracapsular neck of femur fracture-A comparison of 60,848 matched patients using national data. *Injury* 2013;44:730-4.
7. Regazzoni P, Riedi T, Winqvist R, Allgöwer M. *The Dynamic Hip Screw Implant System*. Springer; 2012.
 8. Brauer CA, Coca-Perrillon M, Cutler DM, Rosen AB. Incidence and Mortality of Hip Fractures in the United States. *JAMA* 2009;302:1573-9.
 9. Park SY, Yang KH, Yoo JH, Yoon HK, Park HW. The treatment of reverse obliquity intertrochanteric fractures with the intramedullary hip nail. *J Trauma* 2008;65:852-7.
 10. Robinson CM, Houshian S, Khan LA. Trochanteric-entry long cephalomedullary nailing of subtrochanteric fractures caused by low-energy trauma. *J Bone Joint Surg Am* 2005;87:2217-26.