

Case Report

VARIANT ORIGIN OF LEFT INFERIOR PHRENIC ARTERY

Madhumita Datta ^{*1}, Enakshi Ghosh ², Ritaban Sarkar ³, Hindol Mondal ⁴.

^{*1} Demonstrator of Department of Anatomy, ESI Medical College, Joka, Kolkata, India.

² Assistant Professor, Department of Anatomy, R. G. Kar Medical College, Kolkata. India.

³ Former Resident, Department of Anaesthesiology, Medical College, Kolkata, India.

⁴ Former Resident, Department of Pharmacology, Medical College, Kolkata, India.

ABSTRACT

Background: The inferior phrenic artery is seen as an important source of collateral arterial supply to hepatocellular carcinoma, the hepatic artery being the main source. Other pathologic conditions, such as diaphragmatic or hepatic bleeding due to trauma or surgery and bleeding resulting from gastroesophageal problems (Mallory-Weiss tear and gastroesophageal cancer) may also be related to inferior phrenic artery. We present here a case of left inferior phrenic artery taking origin from left gastric artery, showing significance of such variation.

Case Report: This was found during routine dissection of abdomen in a 60 yrs old adult male cadaver in the department of anatomy, R. G. Kar Medical College.

Observations: The variation was observed in the origin of left phrenic artery. It was seen that left phrenic artery took its origin from left gastric artery. Further distribution of left phrenic artery was normal. Right phrenic artery arose normally from abdominal aorta.

Conclusion: Considering the significance of inferior phrenic artery in transcatheter chemo- embolization of hepatocellular carcinoma and gastroesophageal bleeding, the knowledge of the variant origin of inferior phrenic artery is very important not only for the anatomists, but also for the radiologists and the surgeons.

KEY WORDS: Left inferior phrenic artery, Right inferior phrenic artery, Left gastric artery, Hepatocellular carcinoma, Transcatheter chemo-embolization, Gastroesophageal bleeding.

Address for Correspondence: Dr. Madhumita Datta, Demonstrator of Department of Anatomy, ESI Medical College, Joka, Kolkata, India. **E-Mail:** madhumitaanatomy@yahoo.com

Access this Article online

Quick Response code



DOI: 10.16965/ijar.2015.350

Web site: International Journal of Anatomy and Research
ISSN 2321-4287
www.ijmhr.org/ijar.htm

Received: 30 Dec 2015

Peer Review: 30 Dec 2015

Revised: None

Accepted: 18 Feb 2016

Published (O): 31 Jan 2016

Published (P): 31 Jan 2016

BACKGROUND

The inferior phrenic artery (IPA) usually originates between the middle of the 12th thoracic and 2nd lumbar vertebrae [1]. It normally takes origin from aorta or celiac artery, and less frequently from renal, hepatic or left gastric arteries [2]. The inferior phrenic arteries constitute a pair of important vessels; supplying multiple organs including the diaphragm, adrenal gland, esophagus, stomach, liver, inferior vena cava, and retroperitoneum [3]. The right and left

inferior phrenic arteries (RIPA and LIPA) give rise to ascending (anterior), descending (posterior), superior and middle suprarenal branches. The ascending branch of RIPA passes behind the inferior vena cava and gives inferior vena caval and diaphragmatic branches. Behind the esophagus, the ascending branch of LIPA divides into a larger anterior trunk and a smaller posterior trunk. The anterior trunk supplies the dome of diaphragm and the region of the gastroesophageal junction. The LIPA may give

rise to a small number of branches that serve to supply the superior pole of the spleen and the proximal portion of the stomach [4]. Potentially, IPA can communicate with internal mammary artery, intercostals artery, musculophrenic artery, pericardiophrenic artery and other systemic vessels of the thorax [1].

The RIPA and LIPA have been known for their provision of extrahepatic collaterals to hepatocellular carcinoma (HCC). In a case of hepatic arterial occlusion or in cases where the hepatoma is close to the bare area of liver, IPA angiography is done. Selective transcatheter arterial chemoembolization (TACE) from IPA is preferred. In case where proximal IPA is used for TACE, complications such as pleural effusion, basal atelectasis, weakness of diaphragm, and gastroesophageal ulcerations can occur [5]. There have been reports of gastroesophageal bleeding and Mallory-Weiss tear due to bleeding from LIPA [6]. During our dissection of abdomen, it was seen that LIPA took its origin from left gastric artery (LGA). This type of variation of origin of LIPA is rarely found in literature till now.

CASE REPORT

The variation was found during routine dissection of abdomen of an adult formalin fixed cadaver, aged approximately 60 yrs, in the department of anatomy of R. G. KAR Medical college and Hospital. After removal of the lesser omentum, the proximal part of abdominal aorta and its branches were traced out. Later, during tracing of branches of celiac trunk, this variation was found. After that, the stomach was removed for better viewing of distribution of LIPA.

It was seen that left inferior phrenic artery (LIPA) took its origin from left gastric artery (LGA). Further course and distribution of LIPA was normal. On the right side, RIPA arose normally from abdominal aorta. No other vascular variation was present in that body.

RESULTS AND DISCUSSION

Modern anatomy textbooks offer few details of the anatomy of the inferior phrenic arteries [7]. Several authors reported the variations of origin of IPA. Most of that cases, it was observed that IPA took variant origin from celiac trunk and renal artery, but very rarely from LGA and others. Pulakunta T et al, in 2007 during their study of 32 cadavers, observed that, IPA arose from LGA in one case (3.125%) [2]. In 2007, Gwon DI et al in their study, observed IPA arose from LGA in 3.7% of cases [8]. Another study done by Pick JW and Anson BJ in 1990 among 200 cadavers, revealed variant origin of IPA from LGA in 2.3% of cases [1]. According to Loukas M et al, RIPA in 3% of cases and LIPA in 2% of cases arose from LGA. This study was done among 300 cadavers without HCC [4]. Kim HC et al reported a case in a series of 23 patients in which the ascending branch of LIPA arose from LGA [9]. In their angiographic study, Tanaka R et al reported 13 patients (1.7%) with LIPA arising from left hepatic artery or LGA [10]. In a very recent study, done by Gurses AI et al among 26 cadavers showed, RIPA in one case arose from LGA and LIPA in six cases had different source of origin [11].

Embryologically celiac trunk and IPA are derived from six pairs of ventral splanchnic branches.

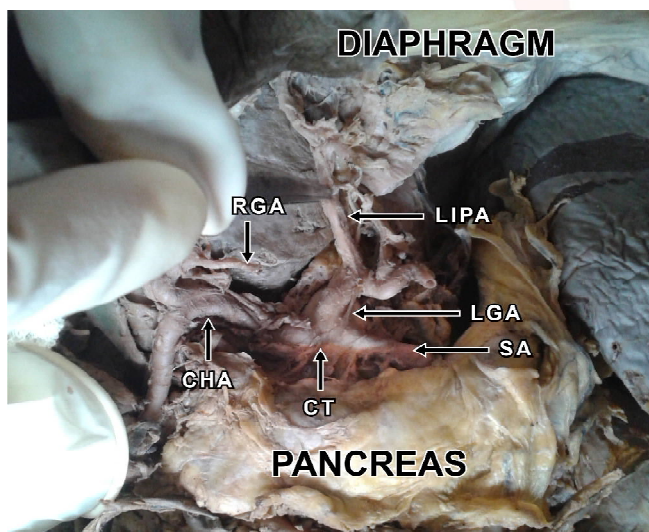


Fig. 1: Left inferior phrenic artery arising from left gastric artery. Stomach was removed to show the origin of the left inferior phrenic artery.

LIPA- Left Inferior Phrenic Artery; LGA- Left Gastric Artery; SA- Splenic Artery; CHA- Common Hepatic Artery; RGA- Right Gastric Artery; CT- Celiac Trunk.

During fetal development, these branches span and disappear, however the persistence of longitudinal channels between these primitive vessels may lead to vascular variations [12].

CONCLUSION

All interventionalists associated with TACE of HCC or gastroesophageal bleeding management using embolization need to be aware of this variant anatomy of IPA to prevent nontarget embolization. Radiologists also must be familiar to this variation of IPA anatomy so that proper detection and correct intervention can be initiated when needed. Considering the importance of knowledge regarding the origin and course of IPA and paucity of information presently available concerning this variation, our study seemed important as it can provide valuable additional data to contemporary anatomical literature.

ABBREVIATIONS

IPA- Inferior phrenic artery

RIPA- Right inferior phrenic artery

LIPA- Left inferior phrenic artery

LGA- Left gastric artery

HCC- Hepatocellular carcinoma

TACE- Transcatheter chemo embolization

ACKNOWLEDGEMENTS

We sincerely thankful to all faculty members of the department of anatomy, R. G. KAR Medical college, and Dr. Pramila Tirkey for their guidance and kind cooperation for conducting this study.

Conflicts of Interests: None

REFERENCES

- [1]. Pick JW, Anson BJ. The inferior phrenic artery: origin and suprarenal branches. *Anat Rec.* 1940;78:413-427.
- [2]. Pulakunta T, Potu BK, Gorantla VR, Rao MS, Madhyastha S, Vollala VR. The origin of the inferior phrenic artery: a study in 32 South Indian cadavers with review of the literature. *J. vasc. Bras.* 2007;6(3):225-230.

- [3]. Topaz O, Topaz A, Polkampally PR, Damiano T, King CA. Origin of a common trunk for the inferior phrenic arteries from the right renal artery: a new anatomic vascular variant with clinical implications. *Cardiovasc Revasc Med.* 2010; 11(1):57-62.
- [4]. Loukas M, Hullett J, Wagner T. Clinical anatomy of the inferior phrenic artery. *Clin Anat.* 2005;18(5):357-365.
- [5]. Hieda M, Toyota N, Kakizawa H et al. The anterior branch of left inferior phrenic artery arising from the right inferior phrenic artery: an angiographic and CT study. *Cardiovasc Intervent Radiol.* 2009;32:250-254.
- [6]. Carsen GM, Casarella WJ, Spiegel RM. Transcatheter embolization for treatment of Mallory-Weiss tears of the oesophagogastric junction. *Radiology.* 1978;128(2):309-313.
- [7]. Baker RJ, Fischer JE. *Mastery of Surgery.* 4th ed., Philadelphia, Lippincott Williams and Wilkins. 2001; p.691-692.
- [8]. Gwon DI, Ko GY, Yoon HK, Sung KB, Lee JM, Ryu SJ, Seo MH, Shim JC, Lee GJ, Kim HK. Inferior phrenic artery: Anatomy, Variations, Pathologic Conditions, and Interventional Management. *Radiographics.* 2007;27(3):687-705.
- [9]. Kim HC, Chung JW, An S, Seong NK, Jae HJ, Cho BH et al. Left phrenic artery feeding hepatocellular carcinoma: angiographic anatomy using C – Arm CT. *AJR Am J Roentgenol.* 2009;193:288-294.
- [10]. Tanaka R, Ibukuro K, Akita K. The left inferior phrenic artery arising from left hepatic artery or left gastric artery : radiological and anatomical correlation in clinical cases and cadavers dissection. *Abdomen imaging.* 2008;33:328-333.
- [11]. Gurses AI, Gayretli O, Kale A et al. Inferior Phrenic Arteries and Their Branches, Their Anatomy and Possible Clinical Importance: An Experimental Cadaver Study. *Balkan Med J.* 2015;32(2):189-195.
- [12]. Standring S. *Gray's Anatomy. The Anatomical Basis Of Clinical Practice.* 40th ed., Philadelphia, Elsevier Churchill Livingstone. 2008;1177-1181.

How to cite this article: Madhumita Datta, Enakshi Ghosh, Ritaban Sarkar, Hindol Mondal. VARIANT ORIGIN OF LEFT INFERIOR PHRENIC ARTERY: A CASE REPORT. *Int J Anat Res* 2016;4(1):1851-1853. **DOI:** 10.16965/ijar.2015.350