

A MORPHOMETRIC STUDY OF OCCIPITAL CONDYLES AND FORAMEN MAGNUM IN ADULT SKULL BASE IN WESTERN MAHARASHTRA REGION OF INDIA

Vishal Ramesh Jasuja ^{*1}, Prasad G. Kulkarni ², Shabana M.Borate ³, Silky R. Punyani ⁴.

^{*1} Assistant professor, Department of Anatomy, People's College of Medical Sciences & Research Centre, People's University, Bhanpur, Bhopal, India.

^{2,3} Associate professor, Department of Anatomy, Grant Government Medical College & Sir JJ Group of Hospitals, JJ Marg, Nagpada, Mumbai, India.

⁴ Senior lecturer, Department of Oral Medicine and Radiology, People's Dental Academy, People's University, Bhanpur, Bhopal, India.

ABSTRACT

Background: The base of the skull has foramina and bony features that bear significant anatomical and surgical importance, foramen magnum and occipital condyles being two such important anatomical entities. Hence a clear understanding of their position, anatomy and dimensions is necessary. With this aim in mind the study was designed to: a) determine the distances between the anterior and posterior bony points of occipital condyles and assess the variation on the right and left side b) determine the dimensions of foramen magnum c) the differences of these measurements between the male and female genders.

Materials and Methods: 100 (male-59; female-41) dry adult human skulls were obtained from the Dept. of Anatomy and Forensic Medicine & Toxicology of Grant Medical College in Mumbai, India. A millimetric sliding vernier caliper was used to measure the distances. The statistical analysis was done using the statistical package Graph Pad Prism 5 software.

Results: The mean axial length of the occipital condyle (ALOC) was found out to be greater on the left side as compared to the right but the difference was not statistically significant. The measurements were greater in the male skulls than the female skulls, for both the sides and the difference was statistically significant. The anterior intercondylar distance was found to be higher in female skulls but the difference between the genders was statistically not significant. The average anteroposterior diameter of foramen magnum (ADFM) was greater in the male skulls; the difference between the genders was statistically not significant. As opposed to this the transverse diameter (TDFM) was found to be greater in the female skulls but the difference was statistically not significant.

Conclusions: The study gives an insight about these dimensions in a subset of population in the western Maharashtra region of India. Further studies with larger sample size are required to validate these findings and its applicability in a clinical scenario.

KEY WORDS: Skull Base, Morphometry, Foramen Magnum, Occipital Condyles.

Address for Correspondence: Dr. Vishal Ramesh Jasuja, C-14 Senior MIG, PCMS Campus, People's University, Bhanpur, Bhopal, India. Mobile: +919685355774 **E-Mail:** vishaljasuja1@gmail.com

Access this Article online

Quick Response code



DOI: 10.16965/ijar.2015.349

Web site: International Journal of Anatomy and Research
ISSN 2321-4287
www.ijmhr.org/ijar.htm

Received: 26 Dec 2015 Accepted: 18 Jan 2016
Peer Review: 26 Dec 2015 Published (O): 31 Jan 2016
Revised: None Published (P): 31 Jan 2016

INTRODUCTION

The bony skeleton of the head, the skull is the most complex osseous structure in the body. The posterior part of the cranial base is largely formed by the occipital bone. Prominent features here, are the foramen magnum, occipital condyles, jugular foramen, mastoid notch, squamous part of occipital bone upto the external occipital protuberance along with the superior nuchal lines, hypoglossal canals and condylar canals. The foramen magnum lies in an anteromedian position and leads into posterior cranial fossa. Anteriorly, the margin of the foramen magnum is slightly overlapped by the occipital condyles which project down to articulate with the superior articular facets on the lateral masses of the atlas [1]. The dimensions of the foramen magnum and the axial / antero-posterior lengths of the occipital condyles are very important factors for surgical exposure, such as in cases of tumour resection from foramen magnum area [2-4]. So also axial lengths of the right and the left occipital condyles and the anterior intercondylar distance are of a great dimensional importance, especially during the exposure of the vertebral artery and the resection of the occipital condyles, as in cases of transcondylar surgical approaches to reach the lesions at the ventrolateral clivus and jugular foramen [5-7]. The floor of the cranium is the template on which the face is constructed and thus finds eminent place in the face reconstruction techniques [8].

Cranial base morphometry and its importance has been a topic of considerable research. Paleoanthropologists have used the knowledge of the skull including its base to chalk out the basic differences between the pre-historic and the modern man [8]. The assessment of sex from the skeletal remains also involves considerations of several aspects of their skeletal morphology [9]. It goes without saying the immense importance of accurate measurements of cranial base landmarks in neurosurgical procedures. With this backdrop the present study was designed to perform a morphometric analysis of the foramen magnum and occipital condyles, two of the most prominent structures in the cranial base.

Aims and Objectives: Our study was designed to : A) Perform a morphometric analysis of the occipital condyles by measuring the axial lengths of the occipital condyles (ALOC) on the right and the left sides, comparing them and measuring the anterior intercondylar distance (AICD). B) Determine the anteroposterior and transverse diameter of the foramen magnum and the foramen magnum index (FMI). C) Determine the differences of these measurements in male and female skulls.

MATERIALS AND METHODS

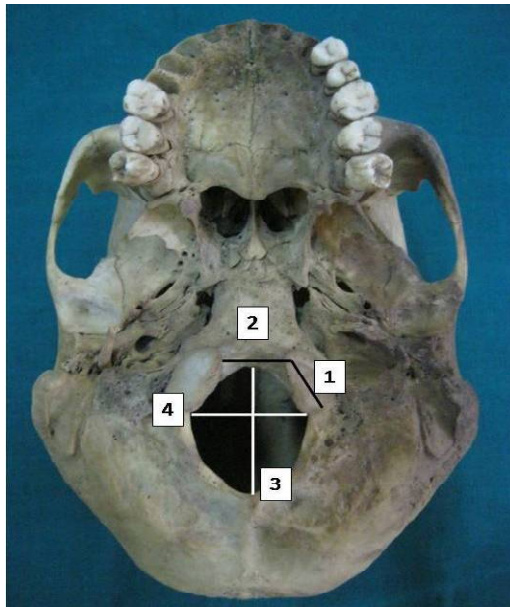
100 dry adult human skulls (59 males and 41 females) were obtained from teaching skeletal collections & medico-legal samples of the bones at the departments of Anatomy and Forensic Medicine, Grant Government Medical College, Mumbai. The determination of skull sex was performed by considering the classic anatomic characteristics as described by Mukherjee J. B [10].

The measured distances were: (Fig. 1)

- Axial Length Of The Occipital Condyles (ALOC): calculated between the anterior and the posterior tips of the occipital condyles.
- Anterior Intercondylar Distance (AICD): measured between the anterior tips of the occipital condyles.
- Anteroposterior Diameter Of Foramen Magnum (ADFM): between basion and opisthion.
- Transverse Diameter Of Foramen Magnum (TDFM): between outermost lateral points of foramen magnum.
- Foramen magnum index (MI): calculated by dividing the anteroposterior diameter of foramen magnum (ADFM) with the transverse diameter of foramen magnum (TDFM).

The parameters were measured with a sliding vernier caliper in mm. scale. Photographs of the skull base were captured with a digital camera. The statistical analysis was done using the statistical package GraphPad Prism 5 software. The p value of < 0.05 was considered as significant for all the tests applied. The mean values of the different parameters were compared by using unpaired t-test. To determine the relationship between the studied parameters, Pearson correlation coefficient was calculated.

Fig. 1: Measurements at the base of the skull: 1) The axial length of the occipital condyles (ALOC). 2) The anterior intercondylar distance (AICD). 3) The anteroposterior diameter of foramen magnum (ADFM). 4) The transverse diameter of foramen magnum (TDFM).



RESULTS AND DISCUSSION

Table 1: Minimum, maximum, and mean \pm standard deviation values of the parameters.

Parameter	Total (100 skulls)			Male (59 skulls)	Female (41 skulls)
	Min	Max	Mean \pm S.D.	Mean \pm S.D.	Mean \pm S.D.
ALOC Rt	15.4	28.2	22.72 \pm 2.21	23.47 \pm 2.02	21.64 \pm 2.03
ALOC Lt	17.3	29	22.86 \pm 2.19	23.55 \pm 2.33	21.87 \pm 1.51
AICD	11.5	27.5	18.59 \pm 2.96	18.23 \pm 2.80	19.11 \pm 3.15
ADFM	26	40	34.13 \pm 2.73	34.24 \pm 3.13	33.97 \pm 2.04
TDFM	21	35	27.82 \pm 3.32	27.61 \pm 3.32	28.12 \pm 3.33
MI	0.91	1.82	1.24 \pm 0.16	1.25 \pm 0.17	1.22 \pm 0.14

Table 2: The statistical inference of results.

Result	P value	Inference
ALOC Lt > ALOC rt	0.65	Significant
ALOC Male skulls > ALOC Female skulls (both sides)	< 0.0001	Significant
AICD Female skulls > AICD Male skulls	0.15	Significant
ADFM Male skulls > ADFM Female skulls	0.63	Not significant
TDFM Female skulls > TDFM Male skulls	0.45	Not significant
MI Male skulls > MI Female skulls	0.32	Not significant

Occipital Condyles: The mean axial length of the occipital condyle (ALOC) was found to be greater on the left side (22.86 \pm 2.19mm) as compared to the right (22.72 \pm 2.21mm) but the difference was not statistically significant

($p=0.65$). The measurements were greater in the male skulls than female skull for both the sides and the difference was statistically significant ($p<0.0001$ for both sides). The average anterior intercondylar distance was found to be 18.59 \pm 2.96. It was greater in females (19.11 \pm 3.15) as compared to males (18.23 \pm 2.80) but the difference was statistically not significant ($p=0.15$). There was a significant association between the ALOC on the right side with that of the ALOC on the left side in total skulls ($p<0.0001$ and $r=0.732$). This data is comparable with those of the earlier studies. Lang reported that axial length of the occipital condyle on the right side ranged from 15 to 27 mm, with an average of 22.9 mm, whereas on the left side, it ranged from 15 to 29 mm, with a mean value of 22.9 mm [11]. Aynur Emine Cicekcibasi et al showed that the right ALOC ranged from 20 to 31.5 mm, with an average of 24.36 mm, whereas on the left it ranged from 18.3 to 31 mm, with a mean value of 24.01 mm [12]. The differences between the results were possibly due to racial variations in the cranial morphometrics of the different studied populations. The insignificant difference between the right and left axial lengths of our studied samples agreed with those obtained by Lang [11] and Aynur Emine Cicekcibasi et al [12], who also did not find significant bilateral differences in their samples. The present study observation of the ALOC in the male skulls, being significantly greater than that in the female skulls, was in accordance with the study of Aynur Emine Cicekcibasi et al [12]. It is worth mentioning that the axial length of occipital condyles is of a great dimensional importance, especially during the exposure of the vertebral artery and the resection of the occipital condyles. Lang [11] in his study reported that the anterior intercondylar distance ranged between 16 mm to 30 mm with a mean value of 23.6 mm whereas Aynur Emine Cicekcibasi et al [12] observed that AICD varied from 10.5 mm to 20.3 mm; with the mean \pm SD of 16.09 \pm 1.93 mm in the male skulls and 14.68 \pm 1.80 mm in the female skulls. The difference was statistically significant ($p=0.016$). Thus the insignificant findings of the present study disagree with those of Aynur Emine Cicekcibasi et al [12] in regard to the gender differences of

the AICD. It has been stated that the sagittally inclined and medially protuberant occipital condyles (AICD becomes short) requires much more bony resection than otherwise during surgeries of the cranial base.

Foramen Magnum: The average anteroposterior diameter of foramen magnum (ADFM) and transverse diameter of the foramen magnum (TDFM) in the total sample was 34.13 ± 2.73 mm and 27.82 ± 3.32 mm respectively. Though ADFM was greater in the male skulls (34.24 ± 3.13), the difference between the genders was statistically not significant ($p=0.63$). As opposed to this the TDFM was found to be greater in the female skulls but the difference was statistically not significant ($p=0.45$). In our study the mean foramen magnum index (ADFM/TDFM) in 100 skulls was 1.24. The mean foramen magnum index in the male skulls ($n=59$) was (1.25 ± 0.17). While in the female skulls ($n=41$) the mean foramen magnum index came to be (1.22 ± 0.14). Thus the mean foramen magnum index was more in the male skulls than the female skulls, but the difference was not statistically significant ($p=0.32$).

Muthukumar et al reported the anteroposterior diameter of foramen magnum as 33.3 mm (27-39 mm) and width as 27.9 mm (23-32 mm) [13]. Kizilkanat et al observed the sagittal and transverse diameters of the foramen magnum to be 34.8 ± 2.2 mm & 29.6 ± 2.4 mm respectively [14]. Ivan Claudio Suazo Galdames et al reported maximum transverse diameter in males and females as 30.6 ± 2.5 mm and 29.5 ± 1.9 mm respectively (p value of 0.001) [15]. They documented the maximum anteroposterior diameter in males and females as 36.5 ± 2.6 mm / 35.6 ± 2.5 mm (p value of 0.008.)

Khalil Awadh Murshed et al had stated that the sagittal and transverse diameters of the foramen magnum were significantly greater in males than in females ($p<0.001$). They also suggested that the foramen magnum size had a low discriminating power and could accurately classify the gender only in 66.5% skulls [16]. Philipp Gruber et al determined relationship between the individual stature and the foramen magnum diameters. Only a moderate positive correlation between the transverse and sagittal diameter of the foramen magnum was found. It

was emphasised that the foramen magnum size could not be used as reliable indicator for stature estimation [17]. Tubbs R. Shane et al took digital images of the foramen magnum from an inferior view. These images were studied using a computer-assisted image analysis system. It was noted that the mean anteroposterior diameter of foramen magnum was 3.1 cm, and the mean horizontal diameter was 2.7 cm [18].

The mean ADFM in the present study was greater than that in the studies of Muthukumar et al [13], Tubbs R. Shane et al [18] but it was less than that observed by Kizilkanat et al [14]. Similarly, the mean TDFM in the present study was greater than that reported by Tubbs R. Shane et al [18] but was less than that observed by Muthukumar et al [13], Kizilkanat et al [14]. It was seen that the ADFM in the present study, being greater in the male skulls matched with the studies of Khalil Awadh Murshed et al [16], Ivan Claudio Suazo Galdames et al [15], though our results were statistically not significant. In contradiction to any of the previously conducted studies, our study found the TDFM to be greater in the female skulls, but the difference was statistically not significant.

Foramen Magnum Index (MI) is calculated by dividing antero-posterior length of foramen magnum with the width. It is said that the foramen magnum index determines the shape of the foramen magnum, which plays a vital role on bone removal during skull base surgery. A lesion located anterior to the brain stem would require more extensive bone removal in a patient with an oval foramen than a similar lesion in a circular foramen. Out of 100 skulls 71% were found to have the foramen magnum index equal to or more than 1.2. Our results were similar to those reported by Muthukumar et al [13] & Kizilkanat et al [14].

Table 2 summarizes the statistical inference of differences obtained for the studied parameters

CONCLUSION

A guideline about the approximate distances between the important bony points related to cranial neurovascular routes is very important. Our study was conducted to provide information on the bilateral and the gender morphological differences of the occipital

condyles and dimensions of the foramen magnum in 100 adult skulls. The findings of the present study give us an insight into the related dimensions which can be a useful guide in cranial base surgery. Further studies with larger samples sizes and utilizing other bony landmarks such as the jugular foramen and mastoid process with the help of computer assisted analysis can provide a more accurate and comprehensive understanding of the skull base morphometry. So also it would help in providing knowledge of possible anatomical variations associated with this region. Hence the need of similar such studies is validated.

ABBREVIATIONS

ALOC- Axial length of the occipital condyles

AICD- Anterior intercondylar distance measured between the anterior tips of the occipital condyles.

ADFM- Anteroposterior diameter of foramen magnum

TDFM- Transverse diameter of foramen magnum

MI- Foramen magnum index

Conflicts of Interests: None

REFERENCES

- [1]. Standring Susan, Berkovitz Barry KB. Head and Neck. In: Gray's Anatomy The Anatomical basis of clinical practice. 40th edition. Elsevier Churchill Livingstone; 2008:409-417.
- [2]. Dowd GC, Zeiller S, Awasthi D. Far lateral transcondylar approach: Dimensional anatomy. Neurosurgery 1999; 45:95-99.
- [3]. George B, Lot G. Anterolateral and posterolateral approaches to the foramen magnum: technical description and experience from 97 cases. Skull base surgery 1995; 5:9-19.
- [4]. George B, Lot G, Boissonnet H. Meningioma of the foramen magnum: A series of 40 cases. Surg Neurol 1997; 47:371-379.
- [5]. Babu RP, Sekhar LN, Wright DC. Extreme lateral transcondylar approach: Technical improvements and lessons learned. J Neurosurg 1994; 81:49-59.
- [6]. George B, DeMantos C, Cophignon J. Lateral approach to the anterior portion of the foramen magnum. Surg Neurol 1988; 29:484-490.
- [7]. Heros RC. Lateral suboccipital approach for vertebral and vertebrobasilar artery lesions. J Neurosurg 1986; 64:559-562.
- [8]. D'Aloisio D, Pangrazio-Kulbersh V. A comparative and correlational study of the cranial base of North American blacks. Am J Orthod Dentofacial 1992; 102:449-455.
- [9]. Rude J, Mertzluft O. Correlation coefficients in human skulls: Significant sexual differences. Anthropologischer Anzeiger 1987; 45:371-375.
- [10]. Mukherjee JB. Personal identification: sex difference in bones. In: Forensic medicine and toxicology. 3rd edition. Academic publishers; 2007:116-118.
- [11]. Lang J. Skull Base and Related Structures D Atlas of Clinical Anatomy. (Translation into English by Juliane Kemmer). Schattauer Verlagsgesellschaft mbH. Stuttgart, 1995.
- [12]. Aynur Emine Cicekcibasi, Khalil Awadh Murshed, Taner Zuylan, Muzaffer Seker, Isik Tuncer. A morphometric evaluation of some important bony landmarks on the skull base related to sexes. Turk journal of medical sciences 2004; 34: 37-42.
- [13]. Muthukumar N, Swaminathan R, Venkatesh G, Bhanumathy SP. A morphometric analysis of the foramen magnum region as it relates to the transcondylar approach. 2005 Aug; 147 (8): 889-895. Epub 2005 Jun 9.
- [14]. Kizilkanat, Emine Dondu. Morphometry of the hypoglossal canal, occipital condyle, and foramen magnum. Neurosurgery Quarterly: September 2006; 16(3): 121-125.
- [15]. Ivan Claudio Suazo Galdames, Priscilla Perez Russo, Daniela Alejandra Zavando Matamala & Ricardo Luiz Smith. Sexual dimorphism in the foramen magnum dimensions. Int. journal of morphology 2009; 27(1):21-23.
- [16]. Khalil Awadh Murshed, Aynur Emine Cicekcibasi, Isik Tuncer. Morphometric evaluation of the foramen magnum and variations in its shape: A study on computerized tomographic images of normal adults. Turk journal of medical sciences 2003; 33:301-306.
- [17]. Philipp Gruber, Maciej Henneberg, Thomas Boni, Frank J. Ruhl. Variability of human foramen magnum size. The anatomical record: Advances in integrative anatomy and evolutionary biology 2009 November; 292(11):1713-1719.
- [18]. Tubbs R Shane; Griessenauer, Christoph J. ; Loukas, Marios; Shoja, Mohammadali M.; Cohen-Gadol, Aaron A. Morphometric analysis of the foramen magnum: An anatomic study. Neurosurgery 2010 February; 66(2):385-388.

How to cite this article: Vishal Ramesh Jasuja, Prasad G. Kulkarni, Shabana M. Borate, Silky R. Punyani. A MORPHOMETRIC STUDY OF OCCIPITAL CONDYLES AND FORAMEN MAGNUM IN ADULT SKULL BASE IN WESTERN MAHARASHTRA REGION OF INDIA. Int J Anat Res 2016;4(1):1846-1850. DOI: 10.16965/ijar.2015.349