

VARIATIONS IN ATTACHMENTS AND NERVE SUPPLY OF THIRD HEAD OF BICEPS BRACHII: A STUDY IN SOUTH INDIAN POPULATION

Hima Bindu Nalluri ^{*1}, Parimala Sirikonda ², Vasanta Leela ³.

^{*1} Associate Professor, Department of Anatomy, Bhaskar Medical College, Hyderabad, Telangana, India.

² Assistant Professor, Department of Anatomy, Bhaskar Medical College, Hyderabad, Telangana, India.

³ Professor, Department of Anatomy, Deccan College of Medical Sciences, Hyderabad, Telangana, India.

ABSTRACT

Background: Biceps brachii muscle normally has two heads; the long head and the short head. Sometimes it has a third head or supernumerary head. Variations in the attachments of the third head of biceps brachii are clinically important.

Aim: This study was undertaken to evaluate the incidence, attachments, relations and nerve supply of the third head of biceps brachii in a South Indian Population.

Material and methods: Both the upper limbs of 40 formalin-fixed cadavers (80 upper limbs) were studied for the possible presence of supernumerary heads of biceps brachii. The anterior compartment of arm was dissected and the biceps brachii muscle was exposed. The attachments, relations and nerves supplying biceps brachii, were delineated.

Results: It was found that Biceps brachii had two heads in 36 cadavers. A third head was observed in 4 cadavers. It was bilateral in one cadaver and unilateral in three cadavers. This third head of biceps brachii arose from the coracoid process along with its short head, bilaterally, in one cadaver. It originated from the medial surface of the shaft of humerus at the insertion of coracobrachialis, in left upper limb of one cadaver. The third head originated from the shaft of humerus along with the medial fibers of brachialis in the right upper limb of one cadaver; and both from shaft of the humerus and medial intermuscular septum in the right upper limb of another cadaver. In three cases it was innervated by the musculo-cutaneous nerve. In one case it was innervated by the branches of the median nerve, where the musculo-cutaneous nerve was absent. All the three heads fused before the formation of bicipital tendon and inserted into the radial tuberosity. But in one case, a few fibers of the third head inserted into the bicipital aponeurosis.

Conclusion: In our study the incidence of third head was 10%. In published literature, its incidence varies from 0.18% to 21.5% in different populations. Variation in the attachments of third head of biceps brachii is important in surgical interventions, neurovascular compression syndromes and unexplained pain syndromes in arm and forearm regions.

Key words: Biceps brachii, Third head of biceps, Supernumerary head, Median nerve compression, Brachial artery compression, Absent musculo-cutaneous nerve.

Address for Correspondence: Dr. Hima Bindu Nalluri, Associate Professor, Department of Anatomy, Bhaskar Medical College, Amdapur X Road, Yenkapally, Moinabad, Ranga Reddy, Hyderabad, Telangana 500075, India. **E-Mail:** nalluribindu@gmail.com

Access this Article online

Quick Response code



DOI: 10.16965/ijar.2015.337

Web site: International Journal of Anatomy and Research
ISSN 2321-4287
www.ijmhr.org/ijar.htm

Received: 10 Dec 2015

Peer Review: 10 Dec 2015

Revised: None

Accepted: 02 Jan 2016

Published (O): 31 Jan 2016

Published (P): 31 Jan 2016

INTRODUCTION

Biceps brachii, a muscle of anterior compartment of arm has been described as having a long head originating from the supra-glenoid tubercle and glenoid labrum and a short head from the coracoid process of the scapula. The two heads join to form a common bicipital tendon distally, and insert into the posterior rough part of radial tuberosity and a bicipital aponeurosis which merges with the deep fascia of forearm [1]. This is the only flexor of the arm crossing the elbow and acting at both shoulder and elbow joints. Both heads are innervated by the musculocutaneous nerve, the nerve of the anterior compartment of arm. It is supplied by vascular branches from anterior circumflex humeral artery and brachial artery.

Biceps brachii is the most common muscle to show anatomical variations in its morphology and number of heads [2]. Most frequent is the presence of third head and sometimes it may have four to seven heads [2-3]. The incidence of third head of biceps brachii varies from 0.18% to 21.5% in different populations [4]. The accessory head of biceps brachii may originate from coracoid process, tendon of pectoralis major, head of humerus or from the shaft of humerus [5]. It's origin from the shaft of humerus which is commonly called as 'humeral head of biceps brachii' is the most common variation [6,7].

From the clinical point of view, muscle anomalies may also be difficult to differentiate from tumors. High median nerve and brachial artery compression around elbow joint has been encountered in cases of lower origin of third head of biceps brachii [8]. Further knowledge of variations in the attachment of supernumerary heads of biceps brachii is clinically important in pre-operative diagnosis, surgical interventions, neurovascular compression syndromes and unexplained pain syndromes in arm and forearm regions. In the present study we elucidate the incidence, attachments, nerve supply and relations of the third head of biceps brachii in a South Indian population. We also discuss its clinical and functional significance.

MATERIALS AND METHODS

This study was carried out on 40 formalin-fixed

cadavers during routine gross anatomy dissections for the undergraduate students over a period of five years (from 2010 to 2015) in the Department of anatomy, Bhaskar Medical College, Hyderabad, India. A longitudinal incision was made on the anterior aspect of both arms extending from the acromion process to a midline point 2.5 cm below the elbow joint. The incision was extended horizontally at both ends of the initial longitudinal incision. The skin was reflected carefully along with the subcutaneous fat and fascia. The biceps brachii was exposed completely and its proximal and distal attachments were delineated. The presence of accessory heads, their attachments and nerve supply were recorded. The relation of median nerve and brachial artery to the accessory head was also recorded.

RESULTS

Biceps brachii had two heads in 36 cadavers. In all the upper limbs, the long head originated from the supra-glenoid tubercle and short head from the coracoid process of the scapula. The third head was observed in four cadavers, bringing its overall incidence to 10%. It was bilateral in one cadaver and this originated from the coracoid process along with the short head of biceps brachii (Fig. 1). It was unilateral in three cadavers (left side in one and right side in two). It originated from the middle of the anteromedial surface of the shaft of humerus, where coracobrachialis was inserted in one left upper limb (Fig. 2). The brachial artery was partially deep to the third head in these two cases. The accessory third head originated from the medial surface of the shaft of humerus along with medial fibers of brachialis and also from the medial intermuscular septum in right upper limb of one cadaver (Fig. 3a). In this, the median nerve and brachial artery passed below the tunnel formed by the third head of biceps where its fibers crossed from medial to lateral to join with the rest of muscle to form the bicipital tendon (Fig. 3b). The third head originated from the antero medial surface of the humerus in common with medial fibers of the brachialis in right upper limb of one cadaver. In this case, a few fibers of the third head inserted into the bicipital aponeurosis and crossed anterior to the median nerve and brachial artery (Fig. 4a). In

this case, the third head was innervated by the branches of the median nerve since the musculocutaneous nerve was absent and was replaced by the branches of the median nerve (Fig. 4b). In the remaining three cases, the third head was innervated only by the musculo-cutaneous nerve. The third head was supplied by the

branches of brachial artery in all cases. All the three heads fused before the formation of bicipital tendon and inserted into the radial tuberosity in all cases and in one case few fibers of third head inserted into the bicipital aponeurosis in addition to the bicipital tendon.

Fig. 1: Third head of biceps brachii originating from the coracoid process along with the short head and joining the other two heads before the formation of bicipital tendon. (1. Long head of Biceps brachii (BB), 2. Short head of BB, 3. Third head of BB, 4. Brachial artery, 5. Median nerve)




Fig. 2: Third head originating from the middle of the antero-medial surface of the shaft of the humerus at the level of insertion of coracobrachialis. (1. Long head of Biceps brachii (BB), 2. Short head of BB, 3. Third head of BB, 4. Brachial artery, 5. Median nerve)




Fig. 3a: Third head of biceps brachii originating from the antero-medial surface of the shaft of the humerus and medial intermuscular septum.




Fig. 3b: Third head was dissected from the medial inter muscular septum to show the median nerve and brachial artery underneath the third head. (1. Long head of Biceps brachii (BB), 2. Short head of BB, 3. Third head of BB, 4. Brachial artery, 5. Median nerve, 6. Musculocutaneous nerve, 7. Brachialis)

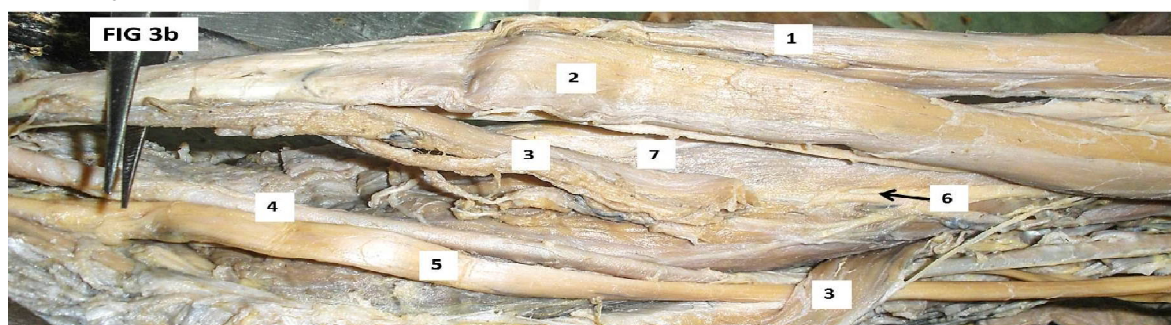
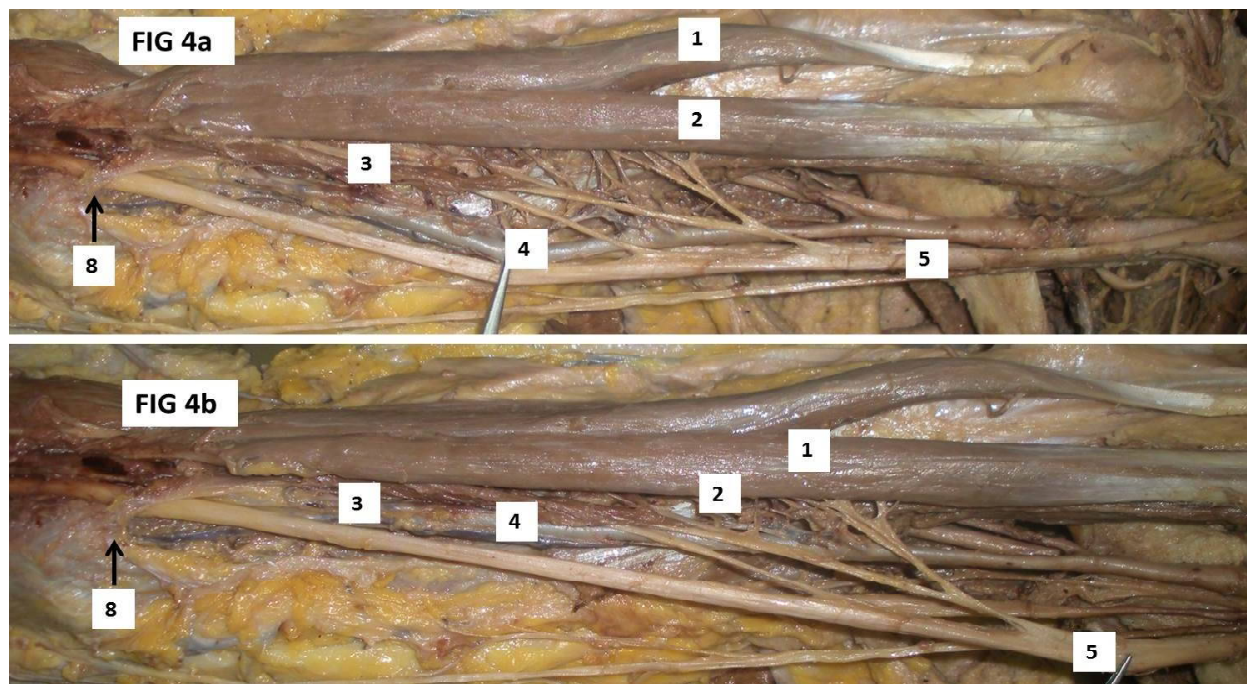


Fig. 4a & Fig. 4b: Third head of biceps brachii originating from the antero-medial surface of the shaft of the humerus and few fibres of it inserting into the bicipital aponeurosis. The musculocutaneous nerve was absent and all muscles of the anterior compartment were innervated by branches from the median nerve. (1. Long head of Biceps brachii (BB), 2. Short head of BB, 3. Third head of BB, 4. Brachial artery, 5. Median nerve, 8. Bicipital aponeurosis)



DISCUSSION

Biceps brachii muscle frequently shows variations in its number of heads and morphology [9]. Absence of either short head or long head of biceps brachii is very rare [10]. We found no cadavers with absent short or long head of biceps, in our study.

Supernumerary heads of biceps brachii have been described in the literature and may vary from three to seven heads [2,3]. The incidence of third head of biceps brachii varies among populations, such as Chinese (8%), European whites (10%), African blacks (12%), Japanese (18%), South African blacks (21%), South African whites (8%), Colombians (38%), Nepalese (12.5), & North Indian population (2.3%) [4,9-12]. The incidence of four-headed biceps brachii is low and varies from 0.18 – 2.75% [6]. In the present study, incidence of third head of biceps brachii was 10%.

Supernumerary heads of biceps brachii may arise from the articular capsule of shoulder joint, lesser tubercle, tendons of pectoralis major or minor, greater tubercle, shaft of the humerus or lateral and medial lips of bicipital groove [2,5,9,13-16]. Rodriguez et al studied 350 arms and classified supernumerary heads of biceps brachii as superior, infero-medial and inferolat

eral heads based on their origin. According to them, superior head was rare and may originate from lesser tubercle, external lip of bicipital groove, undersurface of pectoralis major, anterior surface capsule of shoulder joint, or deltoid muscle [10]. In the present study, we did not encounter such origin of the third head of biceps brachii.

Inferomedial humeral head was the most frequent supernumerary head and may originate from the humerus at the level of insertion of coracobrachialis, from the medial intermuscular septum or the brachialis muscle. The supernumerary head may join the biceps brachii muscle belly, biceps tendon or the bicipital aponeurosis. This head may present usually medial or deep to the median nerve and brachial artery. But the third head may present superficial to them and may produce clinical entrapment syndromes [2]. In the present study, three cases belong to this category of the third head of biceps brachii. In one case it originated from the medial surface of the shaft of the humerus at the insertion of coracobrachialis. In this case it was anterior to the brachial artery. In one case the third head originated from the medial surface of shaft of humerus along with the brachialis muscle and also from the

medial intermuscular septum. In this case, the median nerve and brachial artery were in the tunnel formed by the crossing of fibers of third head from medial intermuscular septum to the bicipital tendon. These fibers may cause compression of the neurovascular bundle. In one case the third head originated from the humeral shaft in common with brachialis. In this some fibers joined the bicipital tendon and some inserted into the bicipital aponeurosis. Those fibers which joined bicipital aponeurosis crossed over the median nerve and brachial artery.

Inferolateral head is the least common supernumerary head and has not been reported in the majority of studies. It originated from the lateral intermuscular septum between the insertion of deltoid and the origin of brachioradialis or from the lateral supracondylar ridge [17]. Rodriguez et al observed muscle bellies resembling infero-medial head in lateral ante-cubital fossa. They did not consider these bellies as part of the biceps brachii as they are innervated by the branches from the radial nerve rather than from musculo cutaneous nerve [10]. We did not observe any such muscle bellies in our study.

A supernumerary head originated from the coracoid process or pectoralis minor was considered as duplication or segmentation of the short head of biceps brachii [18]. In the present study we report a similar origin of third head from the coracoid process along with the short head of biceps brachii and fused with the other two heads before formation of bicipital tendon. This was a rare variation of biceps third head which was considered as duplication of short head of biceps brachii and was not reported earlier in any of the major studies on the supernumerary heads of biceps brachii.

The presence of supernumerary heads of biceps brachii has been associated with the variations of the musculocutaneous nerve or connections between median nerve and musculocutaneous nerve [2,10,14]. The musculocutaneous nerve or its connection with the median nerve usually pass deep to the third head or may be superficial to it or may have no relation to it. In the present study, the musculo cutaneous nerve was deep to the third head in three cases. These three cases were each innervated by a branch

from musculocutaneous nerve. Minor [19] described five types of variations in the course and connections of median and musculocutaneous nerves. Type 5 was considered as absence of musculocutaneous nerve where its fibers pass along with the lateral root of median nerve, and so the median nerve supplies all the muscles innervated by the musculocutaneous nerve [19]. Some reported an absence of musculo-cutaneous nerve associated with the presence of third head of biceps brachii. In these cases branches of the median nerve supplied all muscles of anterior compartment of arm including the third head of biceps brachii [20,21]. In the present study, one case showed absence of musculocutaneous nerve associated with the presence of third head of biceps brachii. In this case, all muscles of anterior compartment were innervated by branches from the median nerve including the third head which was similar to type 5 variation of musculocutaneous nerve described by Minor [19].

The third head of biceps brachii probably derived from muscles of the anterior compartment because of its similar innervation and relationship. "Notably, humans, in contrast to other primates lack long head of coracobrachialis" [22-24]. In those cases in which the third head arises from the insertion area of coracobrachialis, it is possible that it represents the long head of coracobrachialis, the ancestral hominoid condition [3, 22-24]. As Dobson found in *Cercopithecus*, the long head of coracobrachialis may find an insertion onto the radial tuberosity in common with biceps brachii [3, 25]

The biceps brachii is known for its powerful flexion at elbow and supination of forearm. Presence of the supernumerary heads of biceps brachii would increase its kinematics. Therefore from the applied anatomical point of view, its third head increases its power of flexion and supination [26]. The supernumerary heads of biceps brachii may cause compression of the neurovascular bundle of the anterior compartment of arm depending on their attachments and course of fibers. These abnormal fibers may cause entrapment of the median nerve and cause nerve compression syndromes [27].

Therefore, knowledge of the variations is important in surgical manipulations of the arm and in

diagnosing nerve impairments. Any abnormalities in the course or distribution of the nerves may cause accidental injuries during fractures or any surgical procedures of the arm [28]. In the present study, two cases had abnormal course of third head fibers over the median nerve and brachial artery where they may compress these structures. In one case all muscles of anterior compartment of arm were innervated by median nerve replacing musculocutaneous nerve. Usually median nerve would not give branches in the anterior compartment. This is important in the surgical management of any conditions of anterior compartment such as fractures or tumors.

CONCLUSION

The knowledge about variations in the attachments and nerve supply of the third head of biceps brachii is important to the surgeons, traumatologists, clinicians and anatomists as they vary in different individuals and groups, and may cause confusion and iatrogenic injuries of the nerves during surgical procedures. Though the supernumerary heads may increase the power of biceps brachii, they may cause nerve entrapment syndromes especially, when they pass over the neurovascular bundle forming a tunnel. By such inferences, one should carefully evaluate the muscles and nerves of the anterior compartment of arm in diagnostic and management requirements for unexplained pain syndromes of arm and forearm.

Conflicts of Interests: None

REFERENCES

- [1]. Johnson D, Ellis H. Pectoral girdle and upper limb. Gray's anatomy, 39th edition, Elsevier Churchill Livingstone. 2005:853.
- [2]. Nakatani T, Tanaka S, Mizukami S. Bilateral four headed biceps brachii muscles: the median nerve and brachial artery passing through a tunnel formed by a muscle slip from the accessory head. Clin Anat 1998;11:209-12.
- [3]. Asvat R, Candler P, Sarmiento EE. High incidence of third head of biceps brachii in south African population. J.Anat. 1993;182:101-4.
- [4]. Cheema P, Singla R. Low incidence of the third head of the biceps brachii in the North Indian population. Journal of Clinical diagnostic and research. 2011;5(7):1323-1326.
- [5]. Sargon MF, Tuncal DE, Celik HH. An unusual origin for the accessory head of biceps brachii muscle. Clin.Anat. 1996;9:160-2.

- [6]. Khaledpour C. Anomalies of the biceps muscle of the arm. Anat. Anz. 1985;158:79-85.
- [7]. Kopuz C, Sancak B, Ozbenli S. On the incidence of the third head of the biceps brachii in Turkish neonates and adults. Kaibogaku Zasshi. 1999;74(3):301-5.
- [8]. Nayak SR, Ashwin K, Madhan KSJ, Latha VP, Vasudha S, Merin MT. Four headed biceps and triceps brachii muscle with neurovascular variation. Anat Sci Intl. 2008; 83:107-11.
- [9]. Bergman RA, Thompson SA, Afifi AK. Catalogue of human variation. Munich: Urban and Schwarzenberg. 1984;27-30.
- [10]. Rodriguez NM, Vazquez T, Choi D, Parkin I, Sanudo JR. Supernumerary humeral heads of the biceps brachii muscle revisited. Clin Anat. 2003;16:197-203.
- [11]. Abu Hijleh MF. Three headed biceps brachii muscle associated with duplicated musculo cutaneous nerve. Clin Anat. 2005;18:376-9.
- [12]. Poudel PP, Bhattarai C. A study on the supernumerary heads of the biceps brachii muscle in Nepalese population. Nepal Med Coll J. 2009;11(2):96-9.
- [13]. Vollala VR, Nagabhooshana S, Bhat SM, Potu BK, Rodrigues V, Pamidi N. Multiple arterial, neural and muscular variations in upper limb of a single cadaver. Rom J Morphol embryol. 2009;50:129-35.
- [14]. Kosugi K, Shibata S, Yamashita H. Supernumerary head of biceps brachii and branching pattern of musculo cutaneous nerve in Japanese. Surj Radiol Anat. 1992;14:175-85.
- [15]. El Nagggar MM, Zahir FI. Two bellies of the coracobrachialis muscle associated with a third head of the biceps brachii muscle. Clin Anat. 2001; 14:379-82.
- [16]. Donmez BO, Demirel BM, Ozsoy V, Utuk A, Sarikcioglu. Variations of the supernumerary head of the biceps brachii: two case reports and literature review. Anatomy. 2010;4:63-66.
- [17]. Wolf-Heidegger G. Contribution a l'etude de anomalies des muscles biceps brachial et brachial anterieur. Arch Anat Histol Embryol.1937;23:207-217.
- [18]. Stolowsky A. Drei Seltene Anomalies des M. biceps brachii. Anat Heft. 1899;12:299-334.
- [19]. Le Minor JM. A rare variant of the median and musculo cutaneous nerves in man. Archives Anatomy Histology Embryology.1992;73:33-42.
- [20]. Arora L, Dingra R. Absence of musculocutaneous nerve and accessory head of biceps brachii: A case report. Indian J Plast Surg. July-December 2005;38(2):145-6.
- [21]. Abuel - Makarem SM, Ibrahim AF, Darwish HH. Absence of musculocutaneous nerve associated with a third head of biceps brachii muscle and entrapment of ulnar nerve. Neuroscience. 2007;12(4):340-42.
- [22]. Wood J. On a group of varieties of the muscles of the human neck, shoulder and chest. Philosophical transactions of the Royal Society, London. 1870;160:83-116.

- [23]. Primrose A. The anatomy of the Orang-utang (Simian satyrus). Transcripts of the Royal Society, London. 1899;6:507-598.
- [24]. Sonntage CF. On the anatomy, physiology and pathology of the Chimpanzee. Proceedings of the zoological society, London. 1923;23:323-429.
- [25]. Dobson GE. Notes on the anatomy of Cercopithecus callitrichus. Proceedings of the zoological society, London. 1881;812-818.
- [26]. Kumar H, Das S, Rath G. An anatomical insight into the third head of biceps brachii muscle. Bratisl.Lek.Listy. 2008;109:76-8.
- [27]. Warner JP, Palleta GA, Warren RF. Accessory head of the biceps brachii, case report demonstrating clinical relevance. Clin. Ortho. Res. 1992;280:179-81.
- [28]. Roberts WH. Anomalous course of the median nerve medial to the trochlea and anterior to the medial epicondyle of the humerus. Anat. Anz. 1992;174:309-11.

How to cite this article:

Hima Bindu Nalluri, Parimala Sirikonda, Vasanta Leela. VARIATIONS IN ATTACHMENTS AND NERVE SUPPLY OF THIRD HEAD OF BICEPS BRACHII: A STUDY IN SOUTH INDIAN POPULATION. Int J Anat Res 2016;4(1):1795-1801. DOI: 10.16965/ijar.2015.337