

CADAVERIC STUDY ON THE ORIGIN OF THE APPENDICULAR ARTERY

Nirmaladevi M ^{*1}, Sudha Seshayyan ².

^{*1} Associate Professor, PSG Institute of Medical Sciences & Research, Coimbatore, Tamilnadu, India.

² Director, Institute of Anatomy, Madras Medical College, Chennai, Tamilnadu, India.

ABSTRACT

The vermiform appendix is a part of large intestine, situated in right iliac fossa. It is a vestigial organ in humans. This study was done 50 adult cadavers and spontaneously aborted fetal specimens. The anatomical variations were photographed, tabulated and compared with previous studies. Bacterial infection of appendix known as appendicitis is an emergency condition in all age groups. This is treated by removal of it known as appendicectomy. Detailed knowledge about the normal and variant anatomy is important for the surgeons during the surgery. The anatomical knowledge is also useful to the radiologist for diagnosing the appendicular artery in angiograms.

KEY WORDS: Vermiform Appendix, Vestigial, Appendicectomy.

Address for Correspondence: Dr. Nirmaladevi M, Associate Professor, Department of Anatomy, PSG Institute of Medical Sciences & Research, Peelamedu, Coimbatore, Tamilnadu - 641 004, India. Ph: +919865621490, Fax: 0422 2594400

E-Mail: nimmi1971@yahoo.com, drnirmaladevianatomy@gmail.com

Access this Article online

Quick Response code



DOI: 10.16965/ijar.2015.329

Web site: International Journal of Anatomy and Research
ISSN 2321-4287
www.ijmhr.org/ijar.htm

Received: 03 Dec 2015 Accepted: 19 Dec 2015
Peer Review: 03 Dec 2015 Published (O): 31 Jan 2016
Revised: None Published (P): 31 Jan 2016

INTRODUCTION

The appendix is a narrow tube like structure lying in the right iliac fossa. It is part of large intestine and its base is attached to the posterolateral surface of the caecum just below ileocaecal junction, the tip is free and it may be present in retrocaecal, subcaecal, pre/post ileal or pelvic positions. It resembles worms and that's why known as vermiform appendix. The mesentery of appendix is known as mesoappendix and the appendicular artery runs in it. The appendix develops from the midgut of the intestinal loop so its arterial supply is received from superior mesenteric artery. Superior mesenteric artery arises from the abdominal aorta at the level of first lumbar vertebra.

The appendicular artery arises from the inferior division of ileocolic artery which is the terminal

branch of superior mesenteric artery. The appendicular artery runs behind the terminal ileum and enters the mesoappendix usually up to the tip but sometime it lies on the appendicular wall if the mesoappendix is short. The base of the appendix has anastomosis from the recurrent branch of appendicular artery and a branch from the posterior caecal artery. Accessory appendicular arteries may arise from the superior division of ileocolic artery or posterior caecal branch or directly from the ileocolic artery [1, 2].

Inflammation of appendix is known as appendicitis and usually it is an acute condition affecting the young adults, common cause of acute abdomen. Since the appendicular artery is an end artery and also it's close proximity with the appendicular makes it more susceptible to

thrombosis during inflammation. This reduces the blood supply to the tip and the cause for gangrene and rupture. Appendicectomy is the treatment of choice for appendicitis. If the surgery is delayed it leads to complications like rupture, haemorrhage, perforation & shock. During surgery sound knowledge of the origin of appendicular artery, its variations and accessory appendicular arteries is very important to avoid complications.

MATERIALS AND METHODS

A total number of 50 human specimens were studied for the origin of appendicular artery. The specimens were, numbered, preserved in formalin and the arteries of the intestines were identified. The appendix and its mesoappendix were identified and dissected carefully to find out the appendicular artery. All the specimens were photographed and documented.

OBSERVATIONS

In the 50 specimens studied the appendicular artery was present in 49 specimens and was absent in one case which may be due to appendicectomy. Among the 49 specimens, in 42 specimens single appendicular artery was arising from the inferior division of the ileocolic branch, In 2 specimens they were arising from the posterior caecal branch of ileocolic artery.

Double appendicular arteries were seen in 5 specimens, in 3 cases the appendicular arteries were arising from inferior & superior divisions of ileocolic artery (Fig. 1).

In 2 cases the appendicular arteries were arising from inferior division & anterior caecal branch of ileocolic artery (Fig. 2)

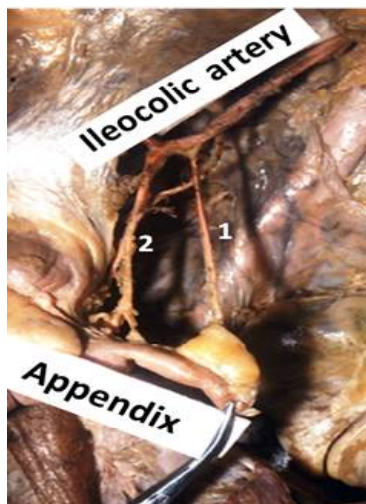


Fig. 1: Double appendicular arteries. 1 from superior division and 2 from inferior division of ileocolic artery.

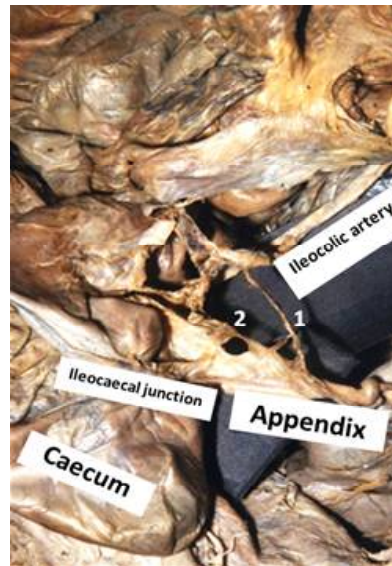


Fig. 2: Double appendicular arteries 1 from inferior division and 2 from anterior caecal branch of ileocolic artery.

DISCUSSION

The variations in the origin of appendicular artery were studied by many authors as they are not uncommon. In the present study 50 specimens were dissected and the origin of the appendicular artery were found, photographed, documented and compared with the findings by authors in previous studies.

According to Pitynski et al (1992) and Aridom B et al. (2012), the appendix was supplied by single branch from the ileocolic branch of superior mesenteric artery in human fetuses [3,4]. In the present study 44 out of 50 specimens the appendix was supplied by single branch from ileocolic artery.

Williams PL, Warwick R (1980) and Susan stadring (2005) described in their text book that the appendicular artery originates from the inferior division of ileocolic branch of superior mesenteric artery [5,1]. In the present study in 42 specimens the origin was from the inferior division of ileocolic branch.

In their study of the appendicular artery Beaton et al (1953), Ranganathan (2002) and Shenoy (2009) found that the appendicular artery takes its origin from the posterior caecal branch of ileocolic artery [6-8]. In the present study the same finding was found in 2 specimens.

Kelly HA, Hurdon E (1905), Shah MA, Shah M (1946), Solanke TF (1968) and Michels NA (1963) described that the appendicular artery may arise as a single branch or double / accessory branches from ileocolic branch [9-12]. In the present study in 5 out of 50 cases double

appendicular arteries were found (Fig. 1 & 2).

CONCLUSION

The origin of the appendicular artery and the variations were studied in the present study. Out of 50 specimens studied 44 specimens had single appendicular artery and in 5 specimens there was double appendicular artery. The idea about the variant origin will help radiologists in identifying the accessory branches if present. The knowledge about the normal and accessory origin is very important for the surgeons during abdominal and laparoscopic surgeries. This knowledge will help in preventing undue haemorrhage and complications.

Conflicts of Interests: None

REFERENCES

- [1]. Susan standing. Gray's Anatomy, anatomical basis of clinical practice. 39th ed. Churchill Livingstone, 2005:1189-1190.
- [2]. Hollinshed WH. Anatomy for Surgeons. Vol.2, 1956; p.492-95.
- [3]. Pitynski K, Skawina A, Gorezyca J, Kitlinski M, Kitlinski Z. Arterial vascularization of the Vermiform appendix in human fetus. *Folia Morphol(Warsz)* 1992;51(2):159-64.
- [4]. ArindomBanergy, Anil kumar, ArunabhaTapadar, M Prany. Morphological variations in the Anatomy of caecum and appendix- A cadaveric Study. *National journal of clinical Anatomy*. 2012;1:30-35.
- [5]. Williams PL, Warwick R. Gray's Anatomy. 36thed. New York, NY: Churchill Livingstone Inc; 1980.
- [6]. Beaton, Anson, Swigart, Johnson. Quoted by B. J. Anson and W. G. Maddock in Callender's. *Surgical Anatomy*. Philadelphia: Saunders.1953;3 ed:478.
- [7]. Ranganathan T S. A Textbook of Human Anatomy, 2002; 6th ed., S Chand & Company Ltd; p. 330.
- [8]. Shenoy K R. Manipal Manual of Surgery. The Appendix. 2009; 3rd ed., CBS Publishers & Distributors; pp. 666-667.
- [9]. Kelly HA, Hurdon E. The Vermiform Appendix and its Diseases. Philadelphia: W. B. Saunders. 1905:189.
- [10]. Shah MA, Shah M. The arterial supply of the vermiform appendix. *Anat. Rec.* 1946;95:457-60.
- [11]. Solanke TF. The blood supply of the vermiform appendix in Nigerians. *JAnat.* 1968; 102:353-361.
- [12]. Michels NA. The variant blood supply to the small and large intestine. *J. Int Coll Surg* 1963;39:127.

How to cite this article:

Nirmaladevi M, Sudha Seshayyan. CADAVERIC STUDY ON THE ORIGIN OF THE APPENDICULAR ARTERY. *Int J Anat Res* 2016; 4(1):1769-1771. DOI: 10.16965/ijar.2015.329