

STUDY OF ANATOMICAL VARIATIONS IN THE ORIGIN OF SUPERIOR THYROID ARTERY

Shivaleela C ^{*1}, Anupama D ², Lakshmi Prabha Subhash R ³.

^{*1} Assistant Professor, Department of Anatomy, Sri Siddhartha Medical College Tumkur, Karnataka, India.

² Associate Professor, Department of Anatomy, Sri Siddhartha Medical College Tumkur, Karnataka, India.

³ Professor and Head, Department of Anatomy, Sri Siddhartha Medical College Tumkur, Karnataka, India.

ABSTRACT

Background: The thyroid gland is one of the ductless glands located in front and on the sides of the trachea opposite C5, C6, & C7 vertebra. The superior thyroid artery (STA) is the branch of the external carotid artery, and arises from the anterior surface of the external carotid just below the level of the greater cornua of the hyoid bone. The knowledge of these variations in the origin of STA is important for various surgical procedures in the radical neck dissection, thyroidectomy, and catheterization, reconstruction of aneurysm, carotid endarterectomy and interventional radiology.

Materials and methods: This study was conducted on 42 cadavers of known age and sex in the department of anatomy Sri Siddhartha Medical College, Tumkur Karnataka, India.. The specimens were studied by gross anatomical dissection.

Results: In our study the site of origin of superior thyroid artery from external carotid was 76.19%, 21.43% of the cases the origin was from the common carotid bifurcation and 2.38% of the cases the origin was from common carotid artery. In our study, in 88.9% of the cases the level of the origin of the superior thyroid artery was above the upper border of the cartilage and in 11.90% of the cases the origin of the superior thyroid artery was at the upper border of the cartilage. In our study the distance from upper pole of the thyroid gland to the level where external laryngeal nerve turn medially from Superior thyroid artery was more than one centimeter in 73.80% and in 26.19% of the cases the distance was less than one centimeter.

Conclusion: A profound knowledge of the anatomic characteristics and variation of the superior thyroid artery such as its origin, course and branching patterns is an important value for a safe attempt in suitable position for catheterization and approach for surgeons in planning and performing procedure in neck region. The knowledge of relationship of superior thyroid artery to external superior laryngeal nerve is very important for surgeons during thyroid surgeries to avoid injuries to above nerves while ligating superior thyroid artery.

KEY WORDS: Superior thyroid artery, Carotid artery, Thyroid.

Address for Correspondence: Dr. Shivaleela C, Assistant Professor of Anatomy, Sri Siddhartha medical college, Tumkur, Karnataka, India PIN- 572107 **E-Mail:** drshivaleela83@yahoo.co.in

Access this Article online

Quick Response code



DOI: 10.16965/ijar.2015.327

Web site: International Journal of Anatomy and Research
ISSN 2321-4287
www.ijmhr.org/ijar.htm

Received: 03 Dec 2015

Peer Review: 03 Dec 2015

Revised: None

Accepted: 19 Dec 2015

Published (O): 31 Jan 2016

Published (P): 31 Jan 2016

INTRODUCTION

The thyroid gland is one of the ductless glands located in front and on the sides of the trachea

opposite C5, C6, & C7 vertebra. The gland varies from H to U shape and is formed by two elongated right and left lobes connected by a

median isthmus. Thyroid gland is the largest endocrine gland and plays an important role in the maintenance of the basal metabolic rate of the body and is highly vascular endocrine gland. The superior thyroid artery normally takes its origin from the external carotid artery. The superior thyroid artery (STA) is the branch of the external carotid artery, and arises from the anterior surface of the external carotid just below the level of the greater cornua of the hyoid bone. It descends along the lateral border of thyrohyoid to reach the apex of the lobe of the thyroid gland. It is medially related to the inferior constrictor muscle, while the external laryngeal nerve often posteromedial, and therefore at risk when the artery is being ligatured. The superior thyroid artery supplies the thyroid gland, infrahyoid strap muscles, the upper part of the larynx, middle region of sternocleidomastoid and cricothyroid [1]. Past studies have reported the incidence of origin of the superior thyroid artery from the common carotid artery in 5-45% cases [2]. The superior thyroid artery also takes part in the formation of important collateral circulation between the external carotid arteries that become important in cases of occlusion of unilateral common carotid artery [3].

The knowledge of these variations in the origin of STA is important for various surgical procedures in the radical neck dissection, thyroidectomy, and catheterization, reconstruction of aneurysm, carotid endarterectomy and interventional radiology.

MATERIALS AND METHODS

This study was conducted on 42 cadavers of known age and sex in the dissection laboratory, department of anatomy, Sri Siddhartha Medical College, Tumkur Karnataka, India. The cadavers were embalmed through carotid arterial perfusion or femoral arterial perfusion. The specimens were studied by gross anatomical dissection. A skin incision made from chin to sternum in midline, and the flap of skin reflected inferolaterally and platysma reflected upward. The fat and fascia removed from the margins of the sternocleidomastoid. Now the sternocleidomastoid retracted and the deep fascia removed from the anterior belly of diaphragm to expose

the infrahyoid muscles. Fat and fascia removed from the area between the posterior belly of diaphragm and the superior belly of omohyoid to expose the carotid triangle. This exposed common carotid and internal carotid arteries medial to it and the external carotid artery anteromedial to the internal carotid artery. Expose the External carotid artery and its branches. The Superior thyroid artery was the lowest branch in the triangle.

The data collected during dissection on both sides includes the site of origin of superior thyroid artery, the level of the origin of the superior thyroid artery in relation to upper border of lamina of thyroid cartilage and Relation of External superior laryngeal nerve to the superior thyroid Artery i.e. Distance from upper pole of the thyroid gland to the level. External superior laryngeal nerve turns medially from Superior thyroid artery was measured using digital vernier caliper.

RESULTS

In our study the site of origin of superior thyroid artery from external carotid artery (Fig. 1) was 76.19%, 21.43% of the cases the origin was from the common carotid bifurcation (Fig. 2) and 2.38% of the cases the origin was from common carotid artery (Fig. 3 & 4), (Table 1). In our study, in 88.9% of the cases the level of the origin of the superior thyroid artery was above the upper border of the cartilage and in 11.90% of the cases the origin of the superior thyroid artery was at the upper border of the cartilage. In our study there were no cases which had the origin below the upper border of the cartilage (Table 2).

Fig. 1: Origin of superior thyroid artery from external carotid artery (right side).




Fig. 2: Origin of superior thyroid artery from the bifurcation of common carotid artery.(right side).

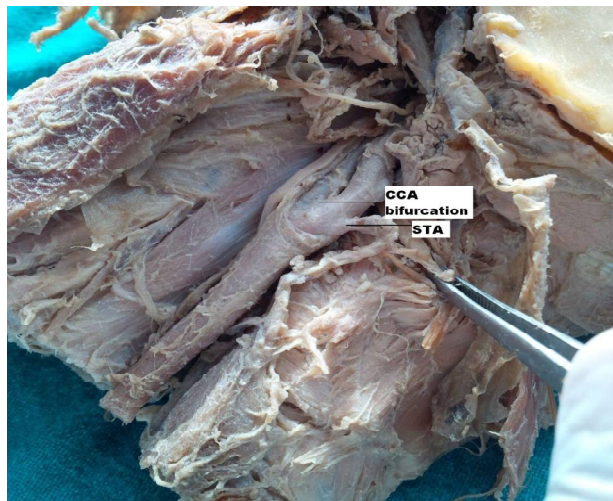


Fig. 3: Origin of superior thyroid artery from common carotid artery (right side)

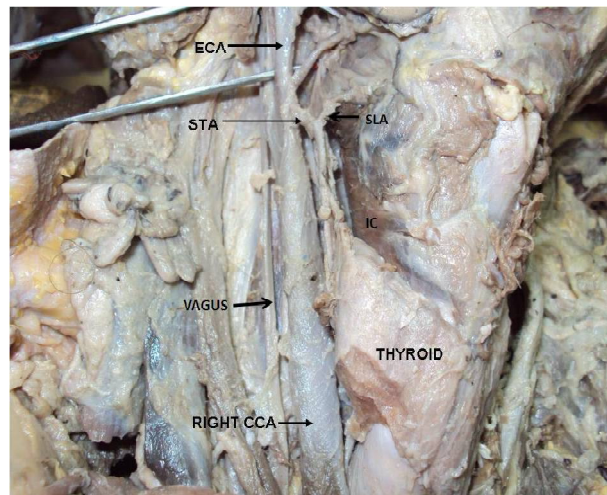


Fig. 4: Origin of superior thyroid artery from common carotid artery (left side).

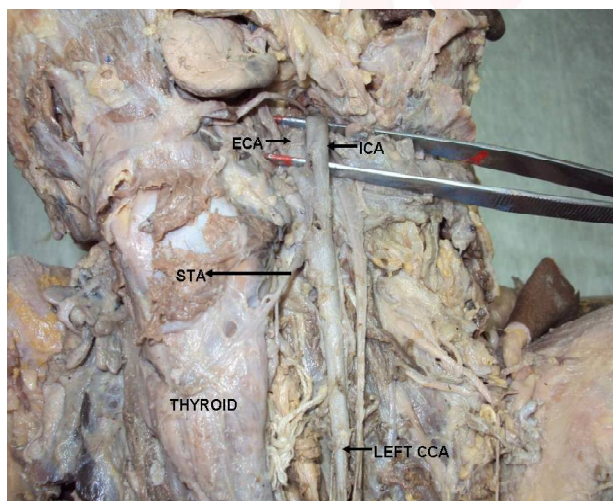


Table 1: Site of the origin of the superior thyroid artery (STA).

Site of origin of STA	Right side (n=42) (%)	Left side (n=42) (%)	Total (n=84) (%)
External Carotid Artery	33(78.57)	31 (73.80)	64 (76.19)
Common Carotid Bifurcation	08 (19.04)	10 (23.80)	18 (21.43)
Common Carotid Artery	01 (02.38)	01(02.38)	02 (02.38)

Table 2: Level of the origin of the superior thyroid artery in relation to upper border of thyroid cartilage.

Level of the origin	Right side (n=42) (%)	Left side (n=42) (%)	Total (n=84) (%)
Above the upper border of cartilage	38 (90.47)	36 (85.71)	74 (88.09)
At the upper border of cartilage	4 (09.52)	6 (14.28)	10 (11.90)
Below the upper border of cartilage	-	-	-

DISCUSSION

The superior thyroid artery is the main source of artery to the thyroid gland, upper part of

larynx and neck region. It arises from external carotid artery (ECA) just below the greater horn of the hyoid bone. It then runs downward from its origin and gives a branch, the superior laryngeal artery that pierces the thyrohyoid membrane along with internal laryngeal nerve. It also gives an infrahyoid branch, a branch to the sternocleidomastoid and a crico-thyroid branch [4]. It may also arise from the Common carotid artery or from the bifurcation of Common carotid artery. Less frequently the STA arises from subclavian artery (SCA) or as a common trunk with the lingual and facial branches of ECA. Rarely The Superior thyroid artery may be absent [5-7].

In present study, the superior thyroid artery took its origin from external carotid artery in 76.19% cases, from carotid bifurcation in 21.43% cases and from common carotid artery in 2.38% cases. The level of the origin of the superior thyroid artery in relation to upper border of thyroid cartilage is important and it has been reported in previous studies (Table 3). During a thyroid surgery Sir William Blizzard ligated Superior thyroid artery on one side for the first time at London hospital, but lost his patient due to secondary haemorrhage [12]. In the surgical literature Catell & Phillips & Gorski have discussed the danger of injuring atypically originating or branching of Superior thyroid artery during operation of thyroid glands [13,14].

It is also important to know possible variations in patterns of origin, courses, and branching pattern of the STA during surgical procedures in the neck region, such as during emergency

cricothyroidotomy, radical neck dissection, carotid catheterization, reconstruction of aneurysm and carotid endarterectomy. Knowledge of the surgical anatomy of the STA ensures maintaining a bloodless surgical field during major radical neck dissection surgeries to minimize postoperative complications [15]. Lack of knowledge of possible variations could lead to fatal errors during surgical procedures in the neck region.

Table 3: Shows comparison of site of origin of STA in various studies.

Site of origin of STA	External Carotid Artery	Common Carotid Artery	Carotid Bifurcation
Takkallapalli Anitha et al (2011) [8]	59%	21%	19%
Lucev (2000) [9]	30%	47.50%	22.50%
Banna M et al (1990) [10]	68%	10%	22%
Abhijeet Joshi et al (2014) [11]	66.67%	1.51%	31.81%
Present study	76.19%	2.38%	21.43%

CONCLUSION

A profound knowledge of the anatomic characteristics and variation of the superior thyroid artery such as its origin, course and branching patterns is an important value for a safe attempt in suitable position for catheterization and approach for surgeons in planning and performing procedure in neck region. During radical neck surgery, the most feared complication is the rupture of the superior thyroid artery and its branches. Iatrogenic injury can be avoided with this knowledge as well as possible anatomic and pathological variation that may exist. The knowledge of relationship of superior thyroid artery to external superior laryngeal nerve is very important for surgeons during thyroid surgeries to avoid injuries to above nerves while ligating superior thyroid artery.

Conflicts of Interests: None

REFERENCES

- [1]. Standring, S. (Ed). Gray's Anatomy: The Anatomical Basis of Clinical Practice 40th ed. NewYork Churchill Livingstone.2008;1279-80
- [2]. Smith SD, Benton RS. A rare origin of superior thyroid artery. *Acta Anat* 1978;101:91-3.
- [3]. Macchi C, Catini C. The anatomy and clinical importance of the collateral circle between the external carotid arteries through an anastomosis between the superior thyroid arteries. *Ital J Anat Embryol* 1993;98:197-205.
- [4]. Standring S, Ellis H, Healy JC, Johnson D, William A, Collins P, eds. *Gray's Anatomy: The Anatomical Basis of Clinical Practice*. 39th Ed., London, Elsevier, Churchill Livingstone. 2005;543-547.
- [5]. Mehta V, Suri RK, Arora J, Rath G, Das S. Anomalous superior thyroid artery. *Kathmandu Univ Med J (KUMJ)*. 2010 Oct- Dec;8(32):429-31.
- [6]. Morigyl B, Sturm W, Absence of three regular thyroid arteries replaced by an unusual lowest thyroid artery: A case report. *Surg Radiol Anat* 1996;18:147-50.
- [7]. Vandana Mehta, Rajesh.K.Suri, Jyoti Arora, Gayatri Rath, Srijit Das Anomalous (absent) Superior Thyroid Artery. *Kathmandu Univ Med J* 2010;8(32):426-8.
- [8]. Takkallapalli Anitha, Dattatray Dombe, Krishnamurthy Asha, Sanjay Kalbande, Clinically relevant variations of the superior thyroid artery: An anatomic guide for neck surgeries, *Int J Pharm Biomed Sci* 2011;2(2):51-54.
- [9]. Lucev-N, Babinac D, Maric I, Drescik I, Variations of the great arteries in the carotid triangle. *Otolaryngol Head and Neck Surgery* 2000;122:590-591.
- [10]. Banna M, Lasjaunias P. The arteries of the lingual thyroid: angiographic findings and anatomic variations. *Am J Neuro-radiol* 1990;11:730-732.
- [11]. Abhijeet Joshi, Sumit Gupta, V H Vaniya Anatomical variation in the origin of superior thyroid artery and it's relation with external laryngeal nerve. *National journal of medical research*. 2014;4(2):138-41.
- [12]. Blizzard, sir W Quoted by sir James Berry, *The Thyroid Gland*, Churchill 1901.
- [13]. Cattell RB, Philips ES. Anomalous superior thyroid artery; a finding during resection of carotid body tumor. *Post Grad Med*, 1949;5:137.
- [14]. Gorski M, Przegł Lek, 1970;7:271. Ozgur Z, Govsa F, Ozgrs T. Assessment of origin of characteristics of the front branches of ECA. *J Cranio Fac Surg* 2008;19:1159-1166.

How to cite this article:

Shivaleela C, Anupama D, Lakshmi Prabha Subhash R. STUDY OF ANATOMICAL VARIATIONS IN THE ORIGIN OF SUPERIOR THYROID ARTERY. *Int J Anat Res* 2016;4(1):1765-1768. DOI: 10.16965/ijar.2015.327