

DEFICIENT SACRAL HIATUS CAUSE MECHANICAL LOW BACK PAIN: A RADIOLOGICAL STUDY

Ganesh Elumalai ^{*1}, Malarvani Thangamani ², Sanjoy Sanyal ¹, Palani Kanagarajan ³.

^{*1} Department of Anatomy & Neuroscience, Texila American University, Georgetown, South America.

² Department of Anatomy, National Medical College, Birgunj, Nepal.

³ Department of Community Medicine, Texila American University, Georgetown, South America.

ABSTRACT

Objectives: The study was designed to identify whether there is any association between the variations of sacral hiatus with low back pain (LBP) using the pelvic radiographs of the LBP patients.

Methods: One hundred and fifty digital radiographs include age group of patients between 15 to 50 years of both male and female patients were included in this study. Out of which 100 digital radiographs were of patients with history of LBP positive and 50 digital radiographs are from the LBP negative persons. The morphometry of radiographs were measured using Image-J software and then the measurements of LBP positive radiographs were compared with the measurements of radiographs with LBP negative persons.

Results: In 86 % of LBP negative radiographs, the sacral hiatus was inverted -U shape and in 14 % the sacral hiatus was inverted -V shape. Deficient dorsal wall of the sacrum was not observed in LBP negative radiographs. The apex of the sacral hiatus in LBP negative radiographs was observed the most at S4 level. Deficient dorsal wall was found in 3 % (1% in Partial and 2% in complete) patients presented with LBP positive. Absence of sacral hiatus, a rare phenomenon was observed in 2% of cases in LBP positive radiographs. The apex of the sacral hiatus in the LBP positive patients observed at the S3 level were 52 % and 34 % in S2 level respectively

Conclusion: The patients with LBP positive radiographs had a higher percentage of deficient dorsal walls in comparison to the LBP negative radiographs.

KEY WORDS: Sacral Hiatus, Deficient dorsal wall, Low Back Pain, Lumbo-Pelvic Radiographs.

Address for Correspondence: Dr. Ganesh Elumalai, Department of Anatomy & Neuroscience, Texila American University, Georgetown, South America. **E-Mail:** physiovesalius@gmail.com

Access this Article online

Quick Response code



DOI: 10.16965/ijar.2015.326

Web site: International Journal of Anatomy and Research
ISSN 2321-4287
www.ijmhr.org/ijar.htm

Received: 02 Dec 2015

Peer Review: 02 Dec 2015

Revised: None

Accepted: 19 Dec 2015

Published (O): 31 Jan 2016

Published (P): 31 Jan 2016

INTRODUCTION

The sacrum is a large triangular bone. The word sacrum means "Sacred" in Latin. In English it is the large heavy bone at the base of the spine. The name is derived from the Latin word, "sacred" a translation of the Greek word hieron (osteon), meaning sacred or strong bone. The Romans called the bone, the "Os Sacrum" which literally meant the "Holy bone". In Greek "hieron" meant not only sacred but also a "Temple".

It was in the sense that in its bony concavity laid the sacred organs of procreation, the ovaries and uterus [1,2]. The sacrum is placed between the two innominate bones and forms Postero-superior wall of the pelvic cavity. The opening present at the caudal end of sacral canal is known as sacral hiatus. It is formed due to the failure of fusion of laminae of the fifth (occasionally 4th) sacral vertebra. It is located inferior to the 4th (or 3rd) fused sacral spines or

lower end of median sacral crest [3,4].

Deficiency of bone in the region of sacral hiatus is covered by Superficial and deep posterior sacrococcygeal ligaments which are attached to the margins and floor respectively [5].

The sacral hiatus shows variations in the development [6] leading to highly placed gap in the midline, sometimes there may be incomplete fusion of the laminae of all the sacral vertebrae leading to a midline gap. This leads to decreased surface area for the attachment of extensor muscle at the back which may lead to painful conditions of the back [7]. Two thirds of the adult population is at least once in their life affected by back pain. This pain, as is usually described by the patients, stands in closer sense for complaints of the lower lumbar spine and/or of the lumbo-sacral transition [8]. Caudal analgesia is used during surgical procedures in urology, proctology, general surgery, obstetrics & gynecology and orthopaedics. It is also used for three dimensional colour visualization of lumbosacral epidural space [9-12]. As the sacral hiatus is the passage for 5th sacral and coccygeal nerves it is used for caudal epidural anaesthesia for operations of sacral dermatome [13-15].

And the reliability and success of caudal epidural anaesthesia depends upon anatomical variations of sacral hiatus [16-18]. The lower termination of the dural sac and high placed apex of the sacral hiatus are the two factors posing real danger[19].

The aim of the present study is to find out the correlation between the anatomical variations of sacral hiatus and mechanical low back pain with radiology of Low Back Pain (LBP) patients.

MATERIALS AND METHODS

One hundred and fifty digital radiographs includes age group of patients between 15 to 50 years of both male and female patients were obtained from the department of Imaging & Radio-diagnosis in the Teaching Hospital of National Medical College, Birgunj, Parsa , Nepal

Radio-diagnosis in the Teaching Hospital of National Medical College, Birgunj, Parsa , Nepal region. Out of which 100 digital radiographs were of patients with history of LBP and 50 digital radiographs are from the LBP negative persons. Radiographs from the age group of patients less than 15 years and more than 50 years were excluded. The radiographs obtained from the patients with other spinal deformities, who have undergone any spinal surgery, pregnant ladies and obese patients with pot bellies were excluded from this study.

The morphometry of sacral hiatus was studied by measuring the following parameters in all the digital radiographs:

- The shape of sacral hiatus was noted by naked eye appearance.
- Level of apex of sacral hiatus was noted with respect to sacral vertebra.
- Level of base of sacral hiatus was noted with respect to sacral vertebra.
- The length, antero-posterior width & transverse width of sacral hiatus were measured using the Image-J software.

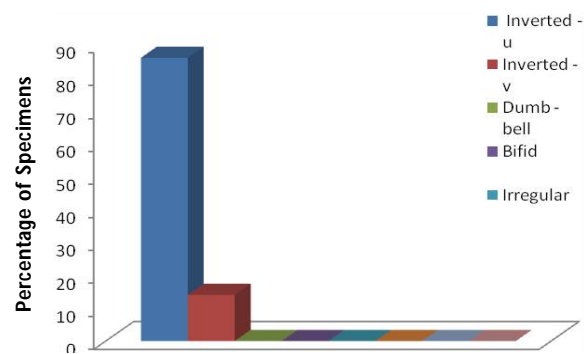
The measurements were then recorded by using tables and graphs [20,21].

OBSERVATIONS

1. IN LOW BACK PAIN NEGATIVE PERSONS

Shape of the sacral hiatus: In 86% of cases the shape of sacral hiatus was Inverted-U.

Graph 1: Shape of sacral hiatus in X-ray of Low Back Pain Negative Sacra.



Different shapes of Sacral Hiatus in X-ray of Low Back Pain Negative Sacra

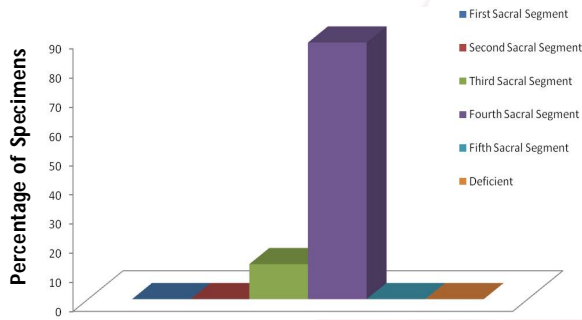
FEATURES	Different shapes of Sacral Hiatus in X-ray of Low Back Pain Negative Sacra							
	Inverted U-Shaped	Inverted V-Shaped	Dumb - bell Shaped	Bifid Shaped	Irregular Shaped	Partial Deficient	Complete Deficient	Absent
Percentage of Specimens	86	14	0	0	0	0	0	0

Table 1: Shape of sacral hiatus in X-ray of Low Back Pain Negative Sacra.

While in the remaining 14% of cases the shape was Inverted-V where both the shapes are considered as normal.

Apex of the sacral hiatus: In 88% of cases the apex of the sacral hiatus lies at the level of fourth sacral segment and in the remaining 12% of cases it was found at the level of third sacral segment.

Graph: 2: Level of Apex of Sacral Hiatus in X-ray of Low Back Pain Negative Sacra.



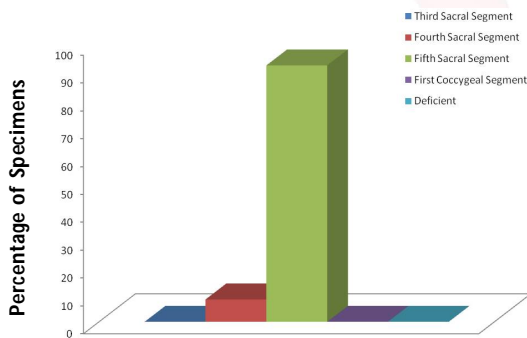
Level of Apex of Sacral Hiatus in X-ray of Low Back Pain Negative Sacra

Table 2: Level of Apex of Sacral Hiatus in X-ray of Low Back Pain Negative Sacra.

FEATURES	Level of Apex of Sacral Hiatus in X-ray of Low Back Pain Negative Sacra					
	First Sacral Segment	Second Sacral	Third Sacral	Fourth Sacral	Fifth Sacral Segment	Deficient
Percentage of Specimens	0	0	12	88	0	0

Base of the sacral hiatus: In 92% of cases the base of the sacral hiatus was present at the fifth sacral segment and in 8% of cases it was found at the fourth sacral segment level.

Graph 3: Level of Base of Sacral Hiatus in X-ray of Low Back Pain Negative Sacra.



Level of Base of Sacral Hiatus in X-ray of Low Back Pain Negative Sacra

Table 3: Level of Base of Sacral Hiatus in X-ray of Low Back Pain Negative Sacra.

FEATURES	Level of Base of Sacral Hiatus in X-ray of Low Back Pain Negative Sacra				
	Third Sacral Segment	Fourth Sacral Segment	Fifth Sacral Segment	First Coccygeal Segment	Deficient
Percentage of Specimens	0	8	92	0	0

Length of the sacral hiatus: The length of the sacral hiatus ranged from 14mm to 22mm in the x-ray of Low Back Pain negative cases.

Transverse width of sacral hiatus: The transverse width of sacral hiatus was found to vary between 18mm to 26mm in the Low Back Pain negative cases.

Antero posterior width of sacral hiatus: In the x-ray of Low Back Pain negative cases the Antero-Posterior width of sacral hiatus varied between 4mm to 8mm

2. IN LOW BACK PAIN POSITIVE PATIENTS

Shape of the sacral hiatus: There were many variations seen in the x-ray of Low Back Pain Positive patients. In only 39% of cases the shape of sacral hiatus was Inverted-U and in 30% of cases it was Inverted-V. In 3% it was dumb-bell in shape and in 2% of cases it was bifid shape. The shape of sacral hiatus was irregular in about 21% of patients. The dorsal wall of sacral canal was partially deficient in 1 case and completely deficient in 2 cases. Absence of sacral hiatus, a rare phenomenon was observed in 2% of cases only.

Fig. 1: Radiology of LBA Positive patients Sacra shows Inverted - U shaped Hiatus.

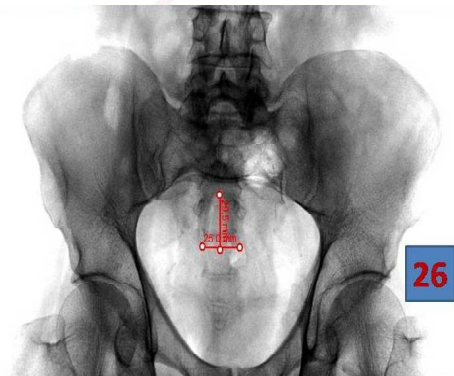


Fig. 2: Radiology of LBA Positive patients Sacra shows Inverted - V shaped Hiatus.

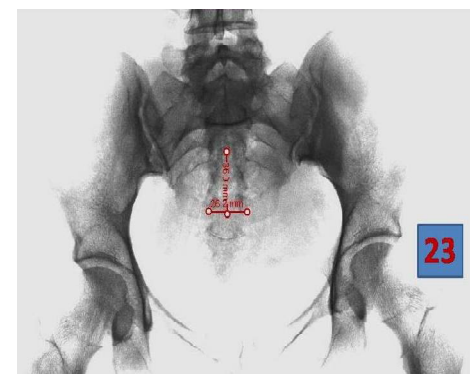

Fig. 3: Radiology of LBA Positive patients Sacra shows Dumb - Bell shaped Hiatus.

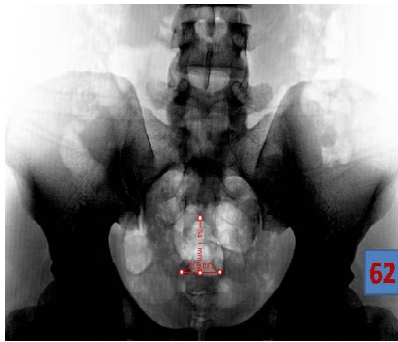


Fig. 4: Radiology of LBA Positive patients Sacra shows Bifid shaped Hiatus.

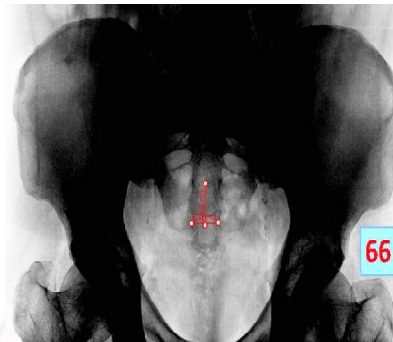

Fig. 5: Radiology of LBA Positive patients Sacra shows Irregular shaped Hiatus.

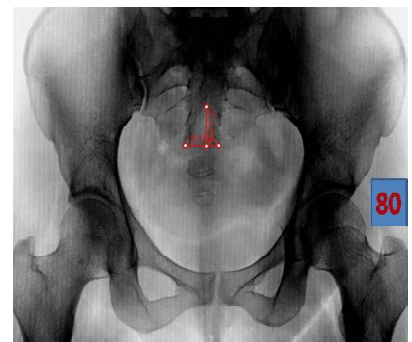


Fig. 6: Radiology of LBA Positive patients Sacra shows Partial Deficient Dorsal wall.

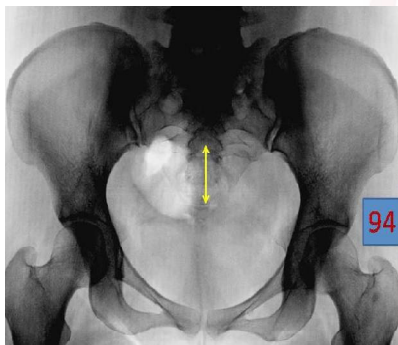


Fig. 7: Radiology of LBA Positive patients Sacra shows Complete Deficient Dorsal wall.

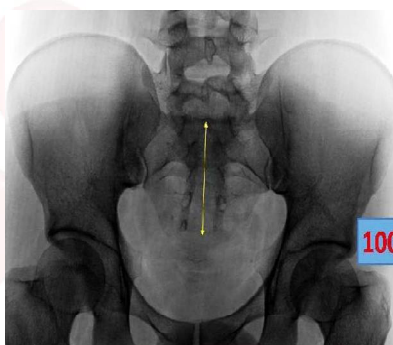
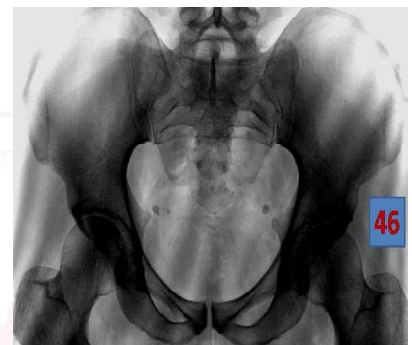
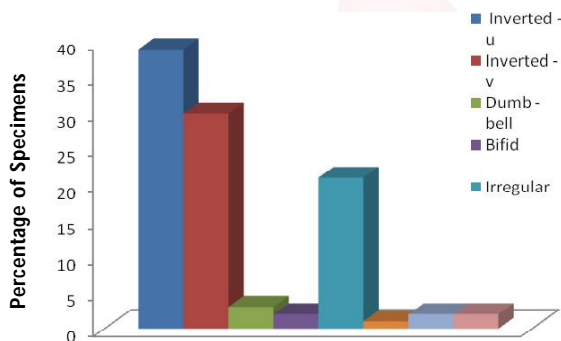


Fig. 8: Radiology of LBA Positive patients Sacra shows Absent Sacral Hiatus.



Graph 4: Shape of sacral hiatus in X-ray of Low Back Pain Positive Sacra.



Different shapes of Sacral Hiatus in X-ray of Low Back Pain Positive Sacra

Apex of the sacral hiatus: The level of apex varied between S4 to S2 level. In 2% of cases the sacral hiatus was completely obliterated and the lower end of the sacral canal was closed due to bony over growth. In 3% of cases the dorsal wall of sacral canal was deficient and so the level of apex of sacral hiatus could not be ascertained in them. In 34% of cases, the apex was found at the second sacral segment. In 52% of cases, the apex was found to be present at the third sacral segment. In 9% of cases the apex extended up to fourth sacral segment.

FEATURES	Different shapes of Sacral Hiatus in X-ray of Low Back Pain Positive Sacra							
	Inverted U Shaped	Inverted V Shaped	Dumb - bell Shaped	Bifid Shaped	Irregular Shaped	Partial Deficient	Complete Deficient	Absent
Percentage of Specimens	39	30	3	2	21	1	2	2

Table 4: Shape of sacral hiatus in X-ray of Low Back Pain Positive Sacra.

Fig. 9: Radiology of LBA Positive patients Sacra shows Apex of Hiatus at S2 Level.

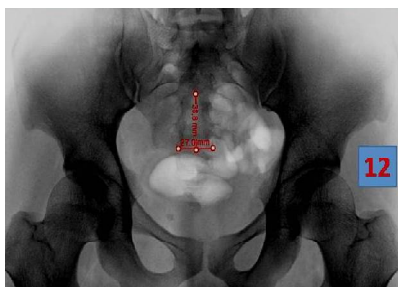


Fig. 10: Radiology of LBA Positive patients Sacra shows Apex of Hiatus at S3 Level.

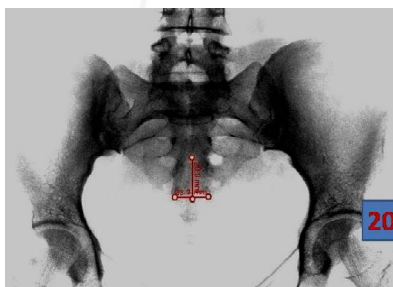
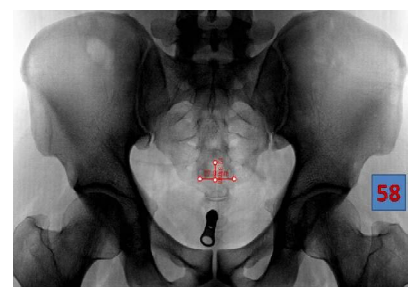
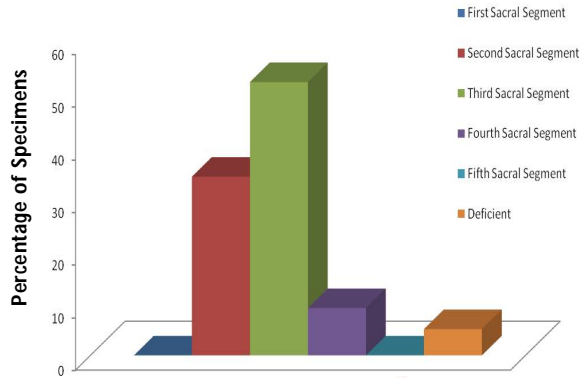


Fig. 11: Radiology of LBA Positive patients Sacra shows Apex of Hiatus at S4 Level.



Graph 5: Level of Apex of Sacral Hiatus in X-ray of Low Back Pain Positive Sacra.



Level of Apex of Sacral Hiatus in X-ray of Low Back Pain Positive Sacra

FEATURES	Level of Apex of Sacral Hiatus in X-ray of Low Back Pain Positive Sacra					
	First Sacral Segment	Second Sacral	Third Sacral	Fourth Sacral	Fifth Sacral Segment	Deficient
Percentage of Specimens	0	34	52	9	0	5

Fig. 12: Radiology of LBA Positive patients Sacra shows Base of Hiatus at S3 Level.

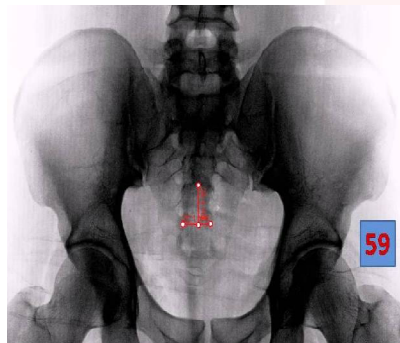


Fig. 13: Radiology of LBA Positive patients Sacra shows Base of Hiatus at S4 Level.

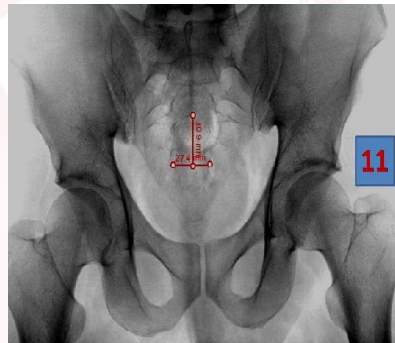
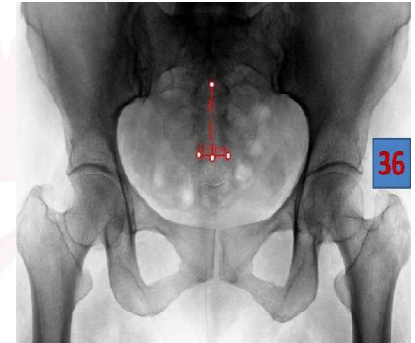
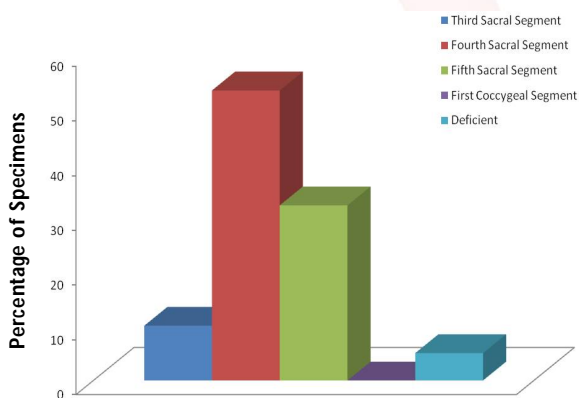


Table 5: Level of Apex of Sacral Hiatus in X-ray of Low Back Pain Positive Sacra.

Fig. 14: Radiology of LBA Positive patients Sacra shows Base of Hiatus at S5 Level.



Graph 6: Level of Base of Sacral Hiatus in X-ray of Low Back Pain Positive Sacra.



Level of Base of Sacral Hiatus in X-ray of Low Back Pain Positive Sacra

Table 6: Level of Base of Sacral Hiatus in X-ray of Low Back Pain Positive Sacra.

FEATURES	Level of Base of Sacral Hiatus in X-ray of Low Back Pain Positive Sacra				
	Third Sacral	Fourth Sacral	Fifth Sacral Segment	First Coccygeal	Deficient
Percentage of Specimens	10	53	32	0	5

Base of the sacral hiatus: The level of base was found to vary between third sacral segment and fifth sacral segment. In 5% of cases, the base could not be noted due to deficient dorsal wall in 3 cases and absence of sacral hiatus in 2 cases. In 53% of cases the base was found at the level of fourth sacral segment. In 32% it was found to lie at the level of fifth sacral segment and in 10% of cases at the third sacral segment level.

Length of the sacral hiatus: The length of sacral hiatus ranged from 12mm to 51mm in Low Back Pain Positive patients.

Transverse width of sacral hiatus: The transverse width varied between 14mm to 32mm in Low Back Pain Positive cases.

Antero posterior width of sacral hiatus: The antero-posterior width of sacral hiatus was found to vary between 3.7mm to 15mm in Low Back Pain Positive patients.

DISCUSSION

The detailed morphometric study of sacral hiatus is of great relevance, since this route is frequently utilized for caudal epidural anaesthesia. The variations of sacral hiatus may also lead to mechanical low back pain

A. Shape of sacral hiatus: The above data were compared with the radiographs of the patients

with Low Back Pain positive radiographs with the Low Back Pain negative radiographs. In this study, the most common shape obtained was Inverted-U which was 39% and Inverted-V which was 30%, Dumb-bell shape was 3% and Bifid shape was 2% which is similar to the study reported by Nagar SK [22]. in which it is 1.5%. Absence of sacral hiatus was only 2% in x-ray study. Irregular shape (21%) was higher compared to the study of Nagar SK [22]. (14.1%) but lower to the study of previous worker Vishal kumar et al [23] which has 30%.

B. Apex of the sacral hiatus: The apex was most commonly found at the third sacral segment in 52% of cases which is very high when compared to study conducted by Vishal kumar et al [23] which had only 9.6%. The next highest percentage obtained was at the level of second sacral segment (34%) which is also very high when compared to all the other previous studies. The level of apex was found at the fourth sacral segment in only 9% of cases. In no cases the level of apex was found at the fifth sacral segment which is the same as that of the radiological study conducted by Vishal kumar et al [23].

C. Base of the sacral hiatus: The level of base was mostly found at the fourth sacral segment in 53% of cases which is high compared to all the studies. In the above data the level of base was found most commonly at the fifth sacral segment of which the highest is 93.3% in the study done by Rajapur parashuram [24] and it is only 32% in the present radiographic study. Only in 1% of dry sacra the base was at the level of coccyx which is very low when compared to the study done Nagar SK [22]. in 16.3% of sacra.

D. Length of the sacral hiatus: The length of sacral hiatus measured in the radiographic study varied between 12mm to 51mm which is high compared to the present study. The values of this radiographic study is somewhat similar to the study done by Rajapur parashuram [24] in which it varied between 4mm to 51mm.

E. Transverse width of sacral hiatus: The transverse width of sacral hiatus varied between 14mm to 32mm in Low Back Pain Positive radiographs which is higher than all the previous studies.

F. Antero posterior width of sacral hiatus: The antero-posterior width of sacral hiatus ranged from 3.7mm to 15mm in radiological study which is somewhat similar to the study conducted by Nagar SK [22]. in which it ranged from 2mm to 14mm but it is high compared to the other studies conducted by Trotter et al (0mm to 11mm) [25,26], Rajapur parashuram (1.5mm to 8.5mm) [24] and Vinod kumar et al (0mm to 12mm) [27].

CONCLUSION

There are anatomical variations in the sacral hiatus and the understanding of these variations may improve the success of caudal epidural anaesthesia which was reported by various workers in the previous studies.

In the present study, the anatomical variations of the sacral hiatus have been examined for it being one of the important causes for mechanical low back pain in the middle age. So, in order to find out the relation between mechanical low back pain and anatomical variations of sacral hiatus, measurements of sacral hiatus regarding its shape, level of apex & base, length, transverse width & antero-posterior width were taken in x-rays of both Low Back Pain Positive and Low Back Pain Negative persons.

The Low Back Pain Positive patients showed a wide range of anatomical variations in the sacral hiatus which may be the reason for the same. These variations of sacral hiatus due to developmental malformations (i.e. incomplete fusion of the laminae of the sacral vertebrae) may lead either to highly placed apex or sometimes even deficient dorsal wall (partial or complete). This leads to the decreased surface area for the attachment of extensor muscles of the back and so even a mild stress to these muscles will make it strain more and will result in painful conditions of the back i.e. mechanical low back pain.

Mechanical low back pain which occurs due to this cause can be overcome or prevented by practising certain exercises such as spinal extension exercise regularly to strengthen these extensor back muscles.

Conflicts of Interests: None

REFERENCES

- [1]. Sugar O. How the sacrum got its name. *Jama and Archives* 1987; 257(15):1.
- [2]. The Sacrum – The Holy Bone, Oct 2003.
- [3]. Standring S. *Gray's Anatomy*, 39th Ed, Elsevier Churchill Livingstone, London, 2005; p: 731 & 749-754.
- [4]. Datta AK. *Essentials of human osteology*, 1st Ed, Current Books International, Calcutta, 1997;53.
- [5]. Ernest J Frazer. *Anatomy of the Human skeleton*. J and A Churchill Ltd, London, 1914;37-42.
- [6]. Letterman GS, Trotter M. Variations of the male sacrum: Their significance in caudal analgesia. *Surg. Gynecol. Obstet* 1944;78(5):551-555.
- [7]. Brailsford JF. Deformities of lumbosacral region of spine. *Br J Surg*1929; 16: 562-627. Published Online: December 6 2005 8:16AM. DOI: 10.1002/bjs.1800166405.
- [8]. Newell RLM. In *Gray's Anatomy. The Anatomical Basis of Clinical Practice*. 39th edition: Churchill Livingstone, London, 2005; pp. 1430-1431..
- [9]. Saberski L, Kitahata L. Direct visualization of lumbosacral epidural space through the sacral hiatus. *Anaesth Analg* 1995;80:839-840.
- [10]. Chen PC, Tang STF, Hsu, et al. Ultrasound guidance in caudal epidural needle placement. *Anaesthesiology* 2004;101:181-184.
- [11]. Esses SE, Botsford DJ: *Surgical Anatomy and Operative Approaches to the sacrum*, in Frymoyer JW, Ducker TB, Hadler NM et al(eds): *The Adult Spine: principles and practise*, 2nd Ed. Philadelphia: Lippincott-Raven, 1997;2:2329-2341.
- [12]. Estin D, Cohen AR. Caudal agenesis and associated caudal spinal cord malformations. *Neurosurg Clin N Am* 1995;6:377-391.
- [13]. Lanier VS, Mcknight HE, Trotter M. Caudal analgesia: An experimental and anatomical study. *American journal of Obstetrics and Gynaecology* 1944;47(5):633-641.
- [14]. N.Senoglu, et al. Landmarks of the sacral hiatus for caudal epidural block: An Anatomical study. *British Journal of Anaesthesia* 2005;95(5):692-695.
- [15]. David L Brown. *Regional Anaesthesia and Aalgnesia*, Saunders and Company, 1986;346-347.
- [16]. Thompson JE. An Anatomical and Experimental study of sacral anaesthesia. *Ann. Surg* 1917;66:718-727.
- [17]. Edwards WB, Hingson RA. Continuous caudal anaesthesia in obstetrics. *American Journal of Surgery* 1942;57:459-464.
- [18]. Sekiguchi M, Yabuki S, Satoh K, Kikuchi S. An Anatomical study of the sacral hiatus: A basis for successful caudal epidural block. *Clinical journal of pain* 2004;20(1):51-54.
- [19]. Hollinshead WH. *Anatomy for Surgeons*. 2nd Ed, Harper and Row publishers, Philadelphia, 1969;176-180.
- [20]. Bernard Rosner. *Fundamentals of Biostatistics*, 5th Ed, Duxbury, 2000.
- [21]. Venkataswamy Reddy. *Statistics fir mental health care research*, NIMHANS publication, India, 2002.
- [22]. Nagar SK. A study of sacral hiatus in dry human sacra. *Journal of Anatomical Society of India* 2004;53(2):18-21.
- [23]. Vishal kumar et al. Sacral hiatus in relation to low back pain in South Indian population: Anatomico – Radiological study. *Bratisl Lek Listy* 2009;110(7):436-441.
- [24]. Rajapur parashuram. *Morphometrical study of sacral hiatus using isolated dry human sacra: Dissertation* 2008.
- [25]. Trotter M. and Letterman GS. Variations of the female sacrum: Their significance in continuous caudal anaesthesia. *Surg. Gynecol. Obstet* 1944;78(4):419-424.
- [26]. Trotter M. Variations of the sacral canal: Their significance in the administration of caudal analgesia. *Anaesth. Analg* 1947;26(5):192-202.
- [27]. Vinod kumar et al. Morphometrical study of sacral hiatus. *Journal of Anatomical society of India* 1992;41(1):7-13.

How to cite this article:

Ganesh Elumalai, Malarvani Thangamani, Sanjoy Sanyal, Palani Kanagarajan. DEFICIENT SACRAL HIATUS CAUSE MECHANICAL LOW BACK PAIN: A RADIOLOGICAL STUDY. *Int J Anat Res* 2016;4(1):1758-1764. DOI: 10.16965/ijar.2015.326