

## AN ANATOMO-IMAGISTIC STUDY OF INTERSPHENOIDAL SINUS SEPTUM

T. S. Guga Priya <sup>1</sup>, N. Vinay Kumar <sup>\*2</sup>, Arun T. Guru, S. D. NalinaKumari <sup>4</sup>.

<sup>1</sup> Associate Professor, Department of Anatomy, Chennai Medical College Hospital and Research Centre, Irungalur, Trichy, Tamilnadu, India.

<sup>\*2</sup> Associate Professor, Department of Anatomy, Government Medical College, East Yakkara, Palakkad, Kerala, India.

<sup>3</sup> Assistant Professor, Department of Radiodiagnosis, Chennai Medical College Hospital and Research Centre, Irungalur, Trichy, Tamilnadu, India.

<sup>4</sup> Professor and Head, Department of Anatomy, Chennai Medical College Hospital and Research Centre, Irungalur, Trichy, Tamilnadu, India.

### ABSTRACT

**Introduction:** Asymmetrically divided sphenoid sinuses exhibits a variety of variation in the formation of inter sinus septum. Previously reported range of incidence of single midline inter-sphenoid sinus septum is from 18.2% to 95%. Many studies have reported differing incidences of laterally placed septum, accessory septa, multiple septa, transverse septa and no septum in the sphenoid sinuses. Termination of inter-sphenoid septum either into internal carotid canal or into optic canal had also been shown in many studies with possibilities of high risk complications related to such termination of septum. Only limited data is available in Indian ethnicity about the variations in presentation of inter-sphenoid sinus septum compounded by the relative high frequency of occurrence of endoscopic trans sphenoid microsurgeries. Hence, this study was done to observe variations occurring in septum of sphenoid sinuses.

**Materials and Methods:** A retrospective CT analysis of images obtained from 114 patients diagnosed with sinusitis during a specific study period was done by two independent observers. The age of the patients ranged from 16-60 years of both sexes. Patients with history of prior sinus or sphenoid surgery, facial trauma, obscured sphenoid sinus pathology were excluded.

**Results:** Single inter sphenoid sinus septum was seen in 83.3%. Out of this Midline, right deviation, left deviation were observed in 11.4%, 33.9% and 21.9% respectively. In 16.7% images, accessory /multiple septum were noticed. While, absent inter sphenoid septum and transverse septum were noted each in 0.8% of images studied. The termination of inter sinus septum to internal carotid canal occurred in 27.3% and into optic canal in 48% of all images studied.

**Conclusion:** This study concluded that the variation in presentation of inter-sphenoid septum and its termination at internal carotid artery canal or optic canal need to be pre operatively evaluated by surgeons for considering risk of septal resection during Trans sphenoid endoscopic surgeries.

**KEY WORDS:** Sphenoid sinus, Septum, Inter-sphenoid septum, Trans sphenoid endoscopic.

**Address for Correspondence:** Dr. N. Vinay Kumar, Associate Professor, Department of Anatomy, Government Medical College, East Yakkara, Palakkad-678013, Kerala, India.

**E-Mail:** [vinaydr1981@gmail.com](mailto:vinaydr1981@gmail.com)

### Access this Article online

#### Quick Response code



DOI: 10.16965/ijar.2016.133

**Web site:** International Journal of Anatomy and Research  
ISSN 2321-4287  
[www.ijmhr.org/ijar.htm](http://www.ijmhr.org/ijar.htm)

Received: 03 Feb 2016      Accepted: 18 Feb 2016  
Peer Review: 05 Feb 2016    Published (O): 29 Feb 2016  
Revised: 15 Feb 2016        Published (P): 29 Feb 2016

## INTRODUCTION

The complex sphenoid bone that forms a segment of skull base contains within it a pair of sinuses divided by a bony septum. There occurs pneumatization of these sinuses asymmetrically between 3-15 years of postnatal life [1-3]. This asymmetrical pneumatization has been claimed to be the reason for shifting away of inter- sphenoid sinus septum from midline position [4].

A single inter sinus septum in sphenoid sinus had been reported by many studies with a wide variation of incidence of 18.2-95% (5-33). Meanwhile, many literatures have noted inter- sphenoid septum that is of midline with either right or left deviation [7-12, 26,27,31,34]. Complete or incomplete accessory / multiple septum in the sphenoid sinuses had also been reported with differing percentage of incidences [9,13,15,20,21,25,27,28,30,31,32]. Also, studies have shown absence of inter sinus septum [9,20,26,27,28,31,33], while a couple of studies have contradicting reports of transverse or a horizontal septum in sphenoid sinus [31,35].

The optic canal or the internal carotid artery canal have been indicated as the common site of termination of the laterally deviated single septum or one among the multiple para median septum [4,15,18,20,22,26,27,28,29,31,33]. This inter -sphenoid septum with such a spectrum of variations have been considered as an anatomical landmark in trans sphenoid microsurgeries [15,19,20,21]. But, a recent study questioned the rationale of having this highly variable structure as a landmark in endoscopic skull based surgeries [36]. The variations of sphenoid sinus septum had been claimed to differ with racial differences [20] and gender differences [15, 37]. This contradicting literature claims coupled with paucity of Indian data, warranted this study about anatomical variations of inter-sphenoid septum using archived CT scan images.

## MATERIALS AND METHODS

A retrospective data from the archives of Department of Radio diagnosis at our medical college hospital were collected and used in this study after Institutional Ethical clearance. Dual

slice CT images from 114 cases with a diagnosis of sinusitis that were taken 3 months prior to study commencement period were analysed using RADIANT DICOM viewer. Analysis of these CT images belonging to patients aged between 16 to 60 years of both sexes obtained by Wipro GE model 5114671/2 machine were done independently by two observers. Patients with history of prior sinus or sphenoid surgery, facial trauma, obscured sphenoid sinus pathology were excluded from this study.

## RESULTS

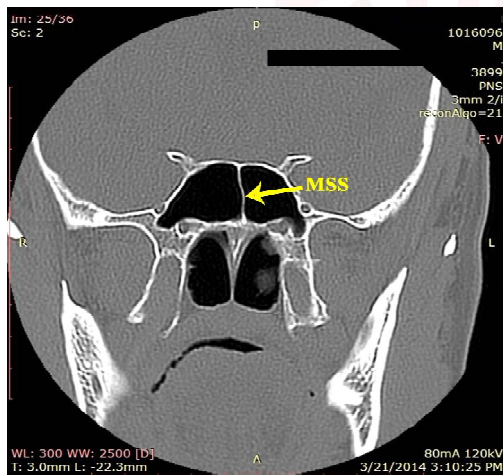
**Table 1:** Incidence of single, accessory, multiple and absent Inter-sphenoid sinus septum.

Study Author	Single Inter-sphenoid sinus septum (%)	Absent inter-sphenoid sinus septum (%)	Accessory/Multiple inter sphenoid septa (%)
Hardy (1979) [5]	75	25	-
Renn & Rhoton (1975) [6]	68	28	-
Kinnman et al (1977) [7]	42	-	-
Elwany et al (1983) [8]	-	-	76
Banna & Olutola (1983) [9]	61	11.4	18
Szolar et al (1994) [12]	77	-	-
Sirikci et al (2000) [14]	38	-	20
Abdulla et al (2001) [15]	-	-	81.8
Sareen et al (2005) [16]	20	-	80
Kazkayasi et al (2005) [17]	19.5	-	-
Hamid et al (2008) [20]	71.6	10.8	8.7
Idowu et al (2009) [21]	95	-	50/48.3
Miranda et al (2009) [22]	23.8	-	-
Zada et al (2011) [25]	18.5	-	29
Fasunla et al (2012) [26]	88.2	2.7	4.5
Eldan et al (2012) [27]	-	2	19.4/3.2
Tarek et al (2014) [28]	70	13.2	6.4/8.3
Manisha et al (2014) [29]	27	13.3	20
Seddighi et al (2014) [30]	28.1	-	71.9
Battal et al (2014) [31]	64.3	1.3	20.1/14
Lupascu et al (2014) [32]	38	-	47
Dundar et al (2014) [33]	90.7	2.2	6.8
Present study	83.3	0.8	16.7

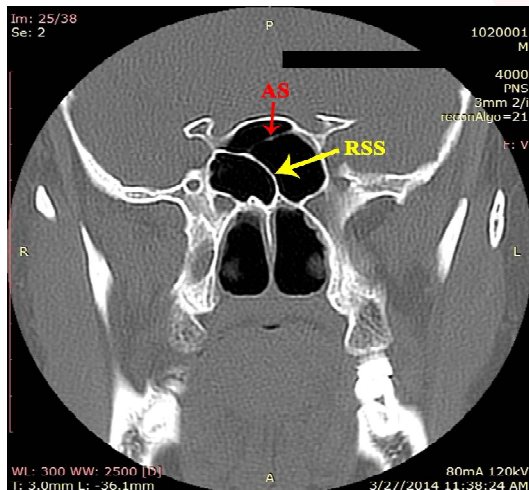
A single inter sphenoid septum was observed in 83.3% of the images studied. Out of that, only in 11.4% showed the septum in the midline, (FIG. 1) while the rest exhibited deviation of septum either to the right or the left side. The right deviation of inter sphenoid septum was observed to be dominant with 33.9% incidence while the

left deviated septum was seen in 21.9% images. (FIG. 2, 3). A horizontal septum in the sphenoid sinus was noted in a single image accounting for 0.8% (FIG. 4). Para median or lateral septum was noted in 14.5% images (FIG. 5). Multiple septum and or accessory septum were seen in 16.7% (FIG 2, 3). Absence of inter sphenoid septum was observed in 0.8% of images studied (FIG. 6). On studying the termination pattern of inter sphenoid septum into the surrounding, the septum that is complete from anterior to posterior was considered as main septum leaving the incomplete septa in images having multiple septa. It was found that the septum terminated in three different ways. The commonest pattern of termination happened to be into the optic canal which was seen in 48 % (FIG. 7), followed by 27.3 % into the internal carotid artery canal (FIG. 8). The less frequent method of termination was into the lateral bony wall which was noted in 13.3% of images studied.

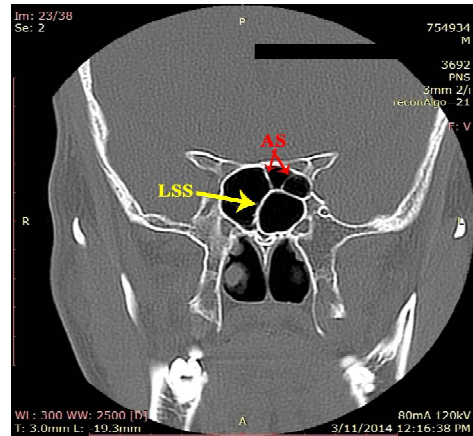
**Fig. 1:** Showing Middle Sphenoidal Septum (MSS).



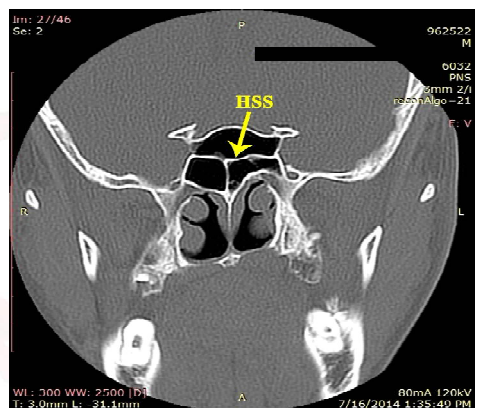
**Fig. 2:** Showing Right deviated Sphenoidal Septum (RSS) with on accessory septum (AS).



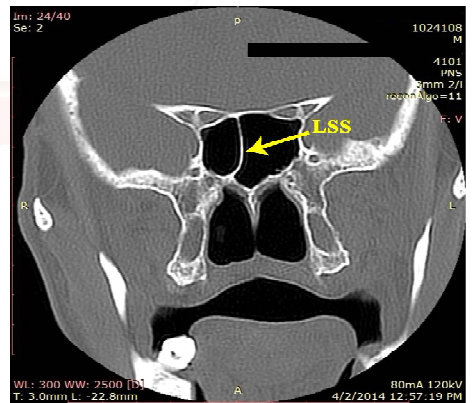
**Fig. 3:** Showing Left deviated Sphenoidal Septum (LSS) with two accessory septum (AS)



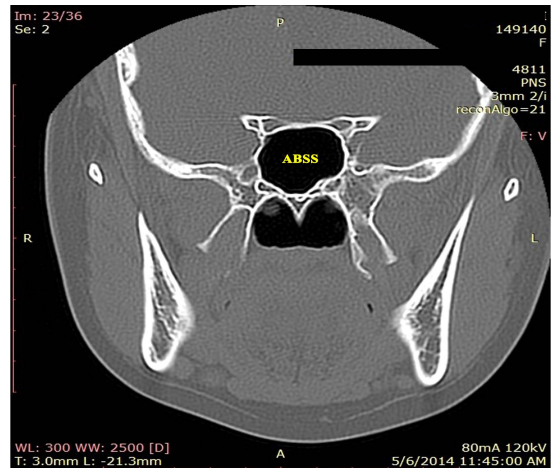
**Fig. 4:** Showing Horizontal Sphenoidal Septum (HSS).



**Fig. 5:** Showing Lateral Sphenoidal Septum (LSS).

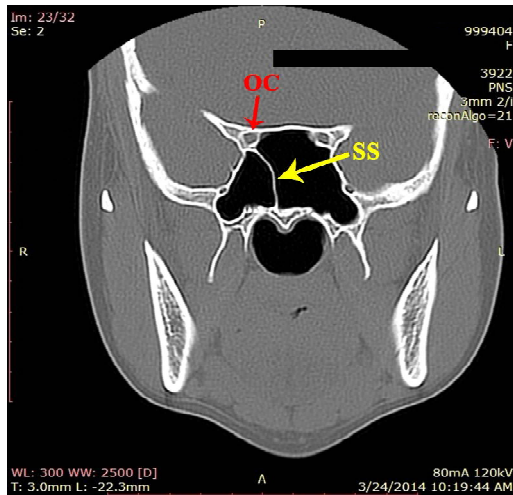


**Fig. 6:** Showing Absent Sphenoidal Septum (ABSS).

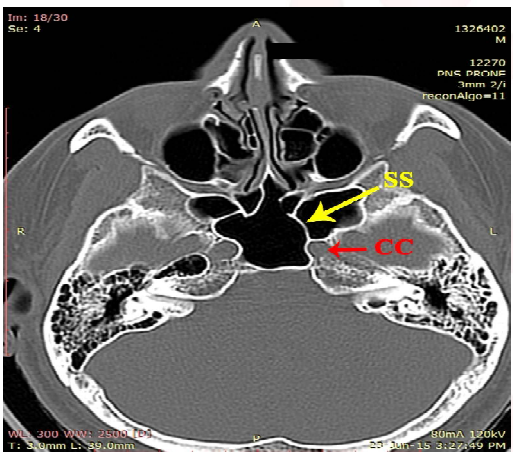




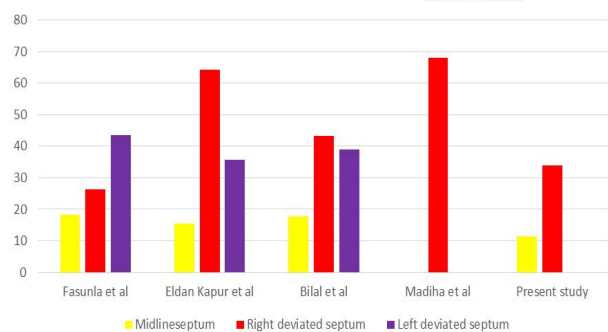
**Fig. 7:** Showing Sphenoidal Septum (SS) inserted to Optic Canal (OS).



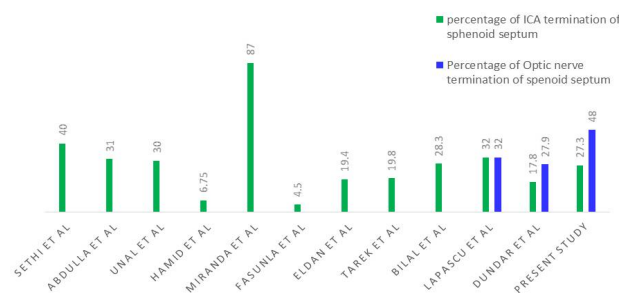
**Fig. 8:** Showing Sphenoidal Septum (SS) inserted to Carotid Canal (CC)



**Graph 1:** Percentage comparison of various positions of inter sphenoid septum.



**Graph 2:** Percentage incidence of different terminations of inter sphenoid septum.



## DISCUSSION

Sphenoid sinus with surrounding vital structures like internal carotid artery, optic nerve is known to have varied pneumatization [1-3]. The inter sphenoid sinus septum had been studied extensively due to its surgical importance in Trans sphenoidal endo surgeries [15,19,20,21].

A single septum that divides the sphenoid into two cavities had been reported by a lot of studies with varying incidence (Table1) [5-33]. Studies have noticed that the single septum rarely occurs in midline, but deviated commonly to either of one side [7-12, 26,27,31,34]. Two previous studies showed right deviated septum predominantly [27,31], when compared to another study that claimed left deviation to be dominant. In the Present study, 34 cases showed right deviated septum as dominant with 43.3 % incidence (Graph: 1). Occurrence of accessory and /or multiple inter sphenoid septum varies from as low as 4.5% till 81.8% and the present study also shows a low incidence of 16.7% (Table 1). Even though the absence of inter sphenoid septum similar to this study had been reported previously [9, 20, 26, 27,28,31,33], there also exist a few studies that had never encountered absence of inter sinus septum [14, 30]. (Table1) The presence of transverse inter sphenoid sinus septum had been reported to be in 7.5% by a study [35], which is of higher incidence compared to the present study's 0.8%. But there is another study that contradicts these findings by not visualizing any transverse septum [31].

The mode of termination of inter sphenoid septum whether single or multiple was observed to end either in the optic nerve canal or internal carotid artery canal or into the lateral wall [4,15,18,20,22,26,27,28,29,31,33] Out of these three patterns of termination the lateral wall termination seen in 13.3% in the present study was similar to incidences noted in two other studies [28,29]. Even though, the termination into internal carotid artery canal had been shown as the common and very high risk pattern in many of the studies [4,22, 25, 32], the present study claims termination into optic canal as the common mode with incidence of 48% (Graph:2). The influence of race and gender upon the

variations in the number, position and deviation, termination had been discussed by a few studies [20, 37]. By considering the study that had statistically proven the insignificance of gender in influencing the occurrence of variations in sphenoid septum, the present study has not concentrated on this gender difference during analysis [15].

A cadaveric study put forth that anatomical variations like shifting of sphenoid septum away from midline or absent septum as reason for disadvantage during trans sphenoidal approach of sellar floor surgeries [6]. While a cluster of reports consider the inter sphenoid sinus septum as a landmark during trans sphenoid endoscopic surgery where in the septum is removed to have an optimal exposure for approaching structures in and around sphenoid sinus [15, 19, 20, 21]. But a recent study questioned the practicality of keeping this highly variant structure as a landmark [36]. In spite of opposing views, the present study considers that the presentation of the inter sphenoid septum needs to be evaluated in Indian ethnicity, pre operatively so as to avoid iatrogenic injury to vital structures during septal resection.

## CONCLUSION

The spectrum of anatomical variations that are possible in number, position, deviation, termination of inter sphenoid sinus septum irrespective of gender and age differences, emphasizes the need for detailed knowledge of these features pre operatively. Also this detailed information may aid the surgeon to plan and limit the surgery intra operatively.

**Conflicts of Interests: None**

## REFERENCES

- [1]. Rice DH, Schaefer SD, Anatomy of the Paranasal Sinuses. In: Rice DH, Schaefer SD Endoscopic Paranasal Sinus Surgery. 2004; Lippincott Williams & Wilkins, 3rd edn 48-50.
- [2]. Van Cauwenberge P, Sys L, De Belder T et al. Anatomy and physiology of the nose and the paranasal sinuses. Immunol Allergy Clin North Am. 2004; 24(1):1-17.
- [3]. Kronomer KA, Mcalister WH. Sinusitis and its imaging in the paediatric population. Pediatr Radiol. 1997; 27:837-46.
- [4]. Sethi DS, Stanley RE, Pillay PK. Endoscopic anatomy of the sphenoid sinus and sella turcica. J Laryngol Otol. 1995; 109(10):951-5.
- [5]. Hardy J. The transsphenoidal surgical approach to the pituitary. Hosp Pract. 1979; 14(6):81-89.
- [6]. Renn WH, Rhoton Jr AL. Microsurgical anatomy of the sellar region. J Neurosurg. 1975; 43:288-98.
- [7]. Kinnman, J. Surgical aspects of the anatomy of the sphenoidal sinuses and the sella turcica. J Anat. 1977; 124(Pt 3): 541
- [8]. Elwany S, Yacout YM, Talaat M, El-Nahass M, Gunied A, Surgical Anatomy of The Sphenoid Sinus The Journal of Laryngology and Otology 1983; 97:227-41.
- [9]. Banna M, Olutola PS. Patterns of pneumatization and septation of the sphenoidal sinus. J Can Assoc Radiol. 1983; 34(4):291-3.
- [10]. Ouaknine GE, Hardy J. Microsurgical anatomy of the pituitary gland and the sellar region. 2. The bony structures. Am Surg. 1987; 53(5):291-7.
- [11]. Scuderi AJ, Harnsberger HR, Boyer RS. Pneumatization of the paranasal sinuses; normal features of importance to the accurate interpretation of CT scans and MR images. AJR Am J Roentgenol 1993; 160:1101-4.
- [12]. Szolar D, Preidler K, Ranner G, et al. The sphenoid sinus during childhood: Establishment of normal developmental standards by MRI. Surg Radiol Anat 1994; 16:193-8.
- [13]. Samy Elwany, Ibraheim Elsaied, Hossam Thabet, Endoscopic anatomy of the sphenoid sinus The Journal of Laryngology and Otology February 1999; 113:122-26.
- [14]. Sirikci A, Bayazit YA, Bayram M, Mumbuc S, Gungor K, Kanhkama M. Variations of sphenoid and related structures. Eur Radiol 2000; 10: 844-848.
- [15]. Abdullah BJ, Arasaratnam S, Kumar G, Gopala K. The sphenoid sinuses: computed tomography assessment of septation, relationship to the internal carotid arteries, and sidewall thickness in the Malaysian population. J HK Coll Radiol. 2001; 4:185-188.
- [16]. Sareen D, Agarwal AK, Kaul JM, Sethi A, Study of sphenoid sinus anatomy in relation to endoscopic surgery, Int J Morphol, 2005, 23(3):261-266.
- [17]. Kazkayasi, M., Karadeniz, Y. & Arikan, O.K. Anatomic variations of the sphenoid sinus on computed tomography. Rhinology. 2005; 43(2): 109-14.
- [18]. Unal B, Bademci G, bilgili YK, batay F, Avci E. Risky Anatomic variations of sphenoid sinus for surgery. Surg. Radiol. Anat. 2006; 28:195-201.
- [19]. Davoodi M, Saki N, Saki G, Rahim F. Anatomical variations of neurovascular structures adjacent sphenoid sinus by using CT scan. Pak J Biol Sci 2008; 12(6):522-5.
- [20]. Hamid O, El Fiky L, Hassan O, et al. Anatomic variation of the sphenoid sinus and their impact on trans-sphenoid pituitary surgery. Skull Base 2008;18:9-16.
- [21]. Idowu OE, Balogun BO, Okoli CA. Dimensions, septation, and pattern of pneumatization of the sphenoidal sinus. Folia Morphol. 2009; 68(4):228-232.

- [22]. Fernandez-Miranda JC, Prevedello DM, Madhok R, Morera V, Barges-Coll J, Reineman K, Snyderman CH, Gardner P, Carrau R, Kassam AB, Sphenoid septations and their relationship with internal carotid arteries: anatomical and radiological study, *Laryngoscope*, 2009, 119(10):1893–1896.
- [23]. Jaworek JK, Troc P, Chrzan R, Sztuk S, Urbanik A, Walocha J. Anatomic variations of the septation within the sphenoid sinus on CT scan images -an initial report. *Przegl Lek.* 2010; 67(4): 279-83.
- [24]. Li SL, Wang ZC, Xian JF. Study of variations in adult sphenoid sinus by multislice spiral computed tomography. *Zhonghua Yi Xue Za Zhi.* 2010; 90(1):2172–2176.
- [25]. Zada, G., Agarwalla, P.K., Mukundan, Jr S.,Dunn, I., Golby, A.J. & Laws, Jr E.R. The neurosurgical anatomy of the sphenoid sinus and sellar floor in endoscopic trans sphenoidal surgery: Clinical article. *Journal of neurosurgery.* 2011; 114(5):1319-1330.
- [26]. Fasanla AJ, Ameye SA, Adebola OS, Ogbola G, Adeleye AO, Adekanmi AJ. Anatomical Variations of the Sphenoid Sinus and Nearby Neurovascular Structures Seen on Computed Tomography of Black Africans. *East and Central African journal of surgery.*2012; 17(1):57-64.
- [27]. Eldan Kapur , Adnan Kapidžić , Amela Kulenović , Lana Sarajlić , Adis Šahinović ,Maida Šahinović .Septation of the Sphenoid Sinus and its Clinical Significance. *International Journal of Collaborative Research on Internal Medicine & Public Health.* 2012;4 (10):1793-1802.
- [28]. Tarek H. ELKammash, Moanes M. Enaba Akram M. Awadalla. Variability in sphenoid sinus pneumatization and its impact upon reduction of complications following sellar region surgeries. *The Egyptian Journal of Radiology and Nuclear Medicine.* 2014; 45: 705–714.
- [29]. Manisha S. Chougule, Daksha Dixit .A cross-sectional study of sphenoid sinus through gross and endoscopic dissection in north Karnataka, India. *Journal of Clinical and Diagnostic Research.* 2014 ;04[cited:2014 Nov 12]:4 AC01-AC05.
- [30]. Afsoun Seddighi, Amir Saied Seddighi, Omid Mellati, ahangir Ghorbani, Nasim Raad, Mohammad Mehdi Soleimani. Sphenoid Sinus: Anatomic Variations and Their Importance in Transsphenoid Surgery *International Clinical Neuroscience Journal.* 2014; Vol 1(1):31-34.
- [31]. Bilal Battal, Sinan Akay , Bülent Karaman, Salih Hamcan, Veysel Akgün, Sebahattin Sari, Uður Bozlar, Mustafa Tapar. The relationship between the variations of sphenoid sinus and nasal septum. *Gülhane Tıp Derg* 2014;56: 232-237.
- [32]. Lupascu M, Comsa Gh. I, Zainea.V. Anatomical variations of the sphenoid sinus - a study of 200 cases. *ARS Medica Tomitana .* 2014; 2(77):57-62.
- [33]. Dündar R, Kulduk E, Soy FK, Aslan M, Kılavuz AE, Sakarya EU, Yazıcı H, Eren A. Radiological evaluation of septal bone variations in the sphenoid sinus. *J Med Updates.* 2014; 4(1):6-10.
- [34]. Madiha.A.EL Sayed, Alaa. A. raouf. Endoscopic anatomy of the sphenoid Air sinus. *Bull.Alex.Fac. Med.*2007;43(7).
- [35]. Vidya CS, Keshav Raichurkar. Anatomic variation of Sphenoid sinus in Mysore based population: CT scan Study. *Int J Anat Res* 2015; 3(4):1611-1614. DOI: 10.16965/ IJAR.2015.300
- [36]. Justin Poirier, Donald Lee, Neil Duggal, Brian W. Rotenberg. The Intersphenoid Sinus Septum: An Impractical Anatomic Landmark in Transsphenoidal Endoscopic Pituitary Surgery. *Skull Base.* 2011; 21(S 01); A066. DOI: 10.1055/s-2011-1274241
- [37]. Filho BC, Pinheiro-Neto CD, Weber R, Voegels RL. Sphenoid sinus symmetry and differences between sexes. *Rhinology.* 2008; 46(3):195-199.

#### How to cite this article:

T. S. Guga Priya, N. Vinay Kumar, Arun T. Guru, S. D. Nalina Kumari. AN ANATOMO-IMAGISTIC STUDY OF INTERSPHENOIDAL SINUS SEPTUM. *Int J Anat Res* 2016;4(1):2015-2020. DOI: 10.16965/ijar.2016.133