

VARIATIONS IN BRANCHING PATTERN OF PROFUNDA FEMORIS ARTERY AND ITS CIRCUMFLEX BRANCHES

Pretty Rathnakar ^{*1}, Vinay Kumar V ², Remya Vinod ³, Beena Nandan ⁴.

^{*1} Assistant Professor, Department of Anatomy, K.S.Hegde Medical Academy, NITTE University, Mangalore, Karnataka, India.

² Associate Professor, Department of Anatomy, K.S.Hegde Medical Academy, NITTE University, Mangalore, Karnataka, India.

³ Lecturer, Department of Anatomy, K.S.Hegde Medical Academy, NITTE University, Mangalore, Karnataka, India.

⁴ Associate Professor, Department of Anatomy, Academy of Medical Sciences, Pariyaram, Kannur District, Kerala, India.

ABSTRACT

Background: Accurate knowledge about the anatomical variations of origin of profunda femoris artery, medial and lateral circumflex femoral artery are important for clinicians for performing surgeries around the aforesaid vessels.

Materials and Methods: The present study was done on 73 lower limbs (38 right and 35 left side) available in the department of Anatomy. The branching pattern of profunda femoralis, medial and lateral circumflex femoral artery were studied. The branching pattern was categorized into different types. The type 1a, the lateral circumflex femoral artery branched distal to the medial circumflex femoral artery and type 1b, the medial circumflex femoral artery branched distal to the lateral circumflex femoral artery. They are grouped under the type 1c, if both the circumflex femoral arteries, were found branching at the same level. Subtype 2a, if the lateral circumflex femoral artery is branching from the profunda femoris artery and the medial circumflex femoral artery is branching from the femoral artery. Type 2b, if the medial circumflex femoral artery is branching from the profunda femoris artery and the lateral circumflex femoral artery is branching from the femoral artery. In type 3, both the lateral and medial circumflex femoral arteries were branching from the femoral artery.

Results: The mean distance between the mid inguinal point and origin of profunda femoris artery from femoral artery was 4.33cms and in majority of specimens the profunda femoris artery originated posterolaterally to femoral artery. In the present study, the type 1a was observed in 57.53% of specimens, type 1b in 4.11% of specimens. The type 1c was not at all seen in any of the specimens. The type 2a was found in 24.65% specimens, type 2b was observed in 9.58% specimens and type 3 in 4.11% of cases.

Conclusion: Knowledge of the variations of the site of origin and course of PFA and its circumflex branches is of diagnostic significance and is important in various surgical procedures and reduces chances of peri-operative complications.

KEY WORDS: Artery, Femoral, Profunda femoris, Circumflex.

Address for Correspondence: Dr. Pretty Rathnakar, Assistant Professor, Department of Anatomy, K.S.Hegde Medical Academy, NITTE University, Mangalore, Karnataka, India.

E-Mail: prettyshrinath@gmail.com

Access this Article online

Quick Response code



DOI: 10.16965/ijar.2016.114

Web site: International Journal of Anatomy and Research
ISSN 2321-4287
www.ijmhr.org/ijar.htm

Received: 20 Jan 2016 Accepted: 08 Feb 2016
Peer Review: 21 Jan 2016 Published (O): 29 Feb 2016
Revised: None Published (P): 29 Feb 2016

INTRODUCTION

Femoral artery (FA) is a continuation of external iliac artery arising posterior to the inguinal ligament, midway between anterior superior iliac spine and the pubic symphysis [1]. This is the point where its pulsations can be felt and can be used for catheterisation in procedures like angiographies and for cannulations to place arterial line (second only to radial artery) [2]. The Profunda Femoris artery (PFA) is a large branch which arises laterally from femoral artery, 3.5 cm distal to the inguinal ligament. It gives two main branches Lateral Circumflex Femoral Artery (LCFA) and Medial Circumflex Femoral Artery (MCFA) [1]. Apart from FA, even PFA can be used for haemodialysis. The branches of PFA are used in thigh flaps as vascular pedicle during breast reconstruction surgeries following mastectomies. Flap necrosis following reconstruction surgeries can be prevented by knowing the variations in the branching pattern of PFA [3].

The accurate knowledge of the branching pattern of MCFA is needed when performing trochanteric & intertrochanteric osteotomies. The MCFA supplies blood to the head and neck of femur, to the adductor muscles and to fatty tissue in the acetabular fossa. This knowledge helps to prevent iatrogenic vascular necrosis of femoral head in reconstructive surgery of the hip and fixation of acetabular fractures through the posterior approach [4,5].

The knowledge about the branching pattern of FA and its vascular system is essential to the cardiologists and radiologists, as this arterial system is often assessed in procedures like coronary angioplasty. The knowledge about anatomical variations in this arterial system including the MCFA and LCFA may prevent the intraoperative bleeding. Since, the combined study of the variations in the origin and branching pattern of the PFA, MCFA & LCFA are rare in literature. The present study was undertaken.

MATERIALS AND METHODS

In the present study 73 lower limbs (38 right and 35 left side) available in the department of Anatomy were studied. After careful dissection, the femoral triangle was exposed and PFA and its branches were identified. The distance of

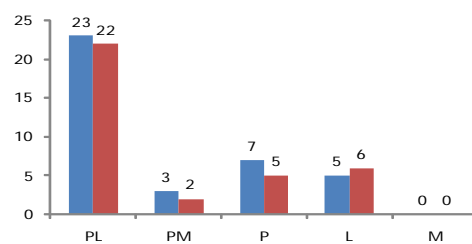
origin of PFA from mid-inguinal point (DP) was measured using digital vernier callipers. The direction and branching pattern of PFA from FA was noted and then classified as per classification by Vasquez et al., [6]. The type 1 has both LCFA and MCFA branching from the PFA. In Type 1a, the LCFA branched distal to the MCFA and in type 1b, the MCFA branched distal to the LCFA. Type 1c, both circumflex arteries were branching at the same level. In type 2, one among the circumflex femoral arteries is branching from the femoral artery (FA) and the other one from the PFA. Subtype 2a, the LCFA was branching from the PFA and the MCFA was branching from the FA. In type 2b, the MCFA was branching from the PFA and the LCFA was branching from the FA. In type 3, both LCFA and MCFA were branching from the FA.

RESULTS

Table 1: Frequency of occurrences of different subtypes of branching pattern of PFA.

Type	Right side (n=38)	Left side (n=35)	Total (n=73)
1a	22 (57.89%)	20 (57.14%)	42 (57.53%)
1b	1 (2.63%)	2 (5.71%)	3 (4.11%)
1c	0 (0.00%)	0 (0.00%)	0 (0.00%)
2a	9 (23.68%)	9 (25.71%)	18 (24.65%)
2b	4 (10.52%)	3 (8.57%)	7 (9.58%)
3	2 (5.26%)	1 (2.85%)	3 (4.11%)

Graph 1: Bar chart showing direction of origin of PFA from FA.

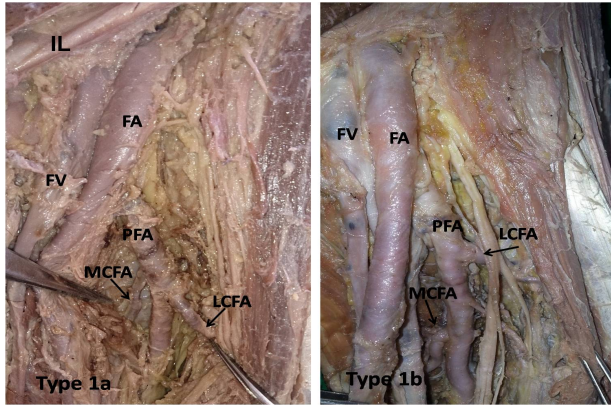


PL - posterolateral, PM - posteromedial, P - posterior, L -lateral, M – medial. Blue bar- right side, Brown bar- left side.

The mean DP observed was 4.33cms and the range 2.5 to 7cms. The minimum DP was observed on the right side (2.5cm) and maximum DP was observed on the left side (7cm). In majority of the specimens the DP was between 4.1 to 5cms and PFA originated posterolaterally (60.52% on right side and 62.85% on left side). The Type 1a branching predominated (57.53%) followed by type 2a

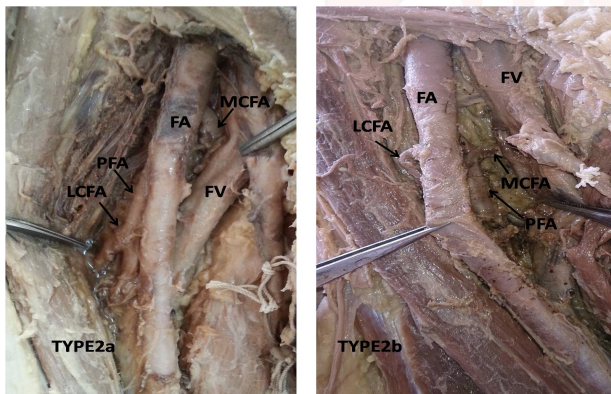
(24.65%). We didn't observe Type 1c branching pattern in any specimens in the present study (Table 1).

Fig 1: Origin of LCFA and MCFA from PFA. Type 1a: LCFA branched distal to MCFA (57.53%), type 1b: MCFA branched distal to LCFA (4.11%).



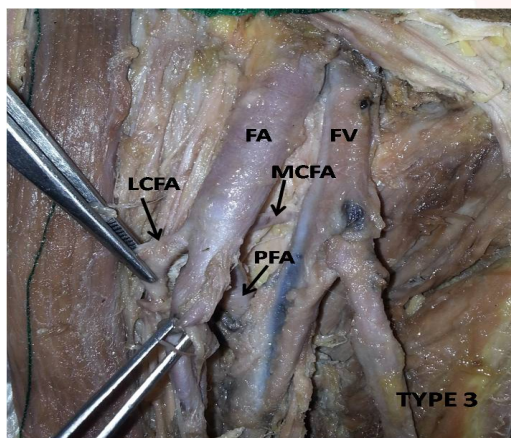
FA- Femoral artery, PFA- Profunda Femoris artery, LCFA –lateral circumflex femoral artery, MCFA- medial circumflex femoral artery.

Fig. 2: Type 2a: LCFA branches from PFA and MCFA from FA (24.65%), Type 2b : MCFA branches from PFA and LCFA from FA (9.58%).



FA- Femoral artery, PFA- Profunda Femoris artery, CFA –lateral circumflex femoral artery, MCFA- medial circumflex femoral artery.

Fig. 3: Type 3: The LCFA and MCFA arise from FA (4.11%).



FA- Femoral artery, PFA- Profunda Femoris artery, LCFA –lateral circumflex femoral artery, MCFA- medial circumflex femoral artery.

DISCUSSION

The variations in the branching patterns of PFA are due to the embryological variation in the selection of capillary channels during the development of arteries of the lower limb. The axis artery of lower limb is a branch of internal iliac artery. FA develops from rete femorale in the future ventral aspect of the thigh. It communicates with the external iliac artery above through rete pelvicum and sciatic artery below. The primary sciatic artery grows out from fifth lumbar intersegmental artery in the dorsal part of thigh, when the embryo is about 10 mm long and ends in plantar capillary plexus. Anastomosis occurs between the axis artery and rete femorale. Increased blood flow in these capillaries determines the final mature arterial pattern. Thus, the most appropriate channels enlarge while others contract and disappear [7,8].

The fetal studies have shown that both LCFA and MCFA arise equally from the FA and PFA [6]. The LCFA and MCFA are the collateral branches arising from the PFA; however they may arise from FA too. The normal distance of origin of PFA from FA to the mid-inguinal point is 35-40 mm [1]. In the present study, the mean DP was found to be 4.33cms which is similar to that observed by Pakash et al., (mean DP- 4.2 cm)⁹ and by Dixit DP et al., (mean DP- 4.75 cm) [10]. much higher than the study by Vuksanovic BA et al., (3.5cms) [11].

The most common site of origin of PFA is posterolateral aspect of FA [9-12]. In study by Prakash et al. [9], by Dixit DP et al., [10] and by Dixit D et al. [12] the PFA originated from the posterolateral aspect of FA in (50%), (35.41%) and (42.1%) cases respectively. The present study also showed that the posterolateral origin of PFA from FA is the most common type (61.64%). In the present study, not even a single specimen with PFA arising from medial side of FA was observed.

In the present study, we observed that type 1 branching pattern was present in 61.64%, type 2 to be 34.23% and type 3 to be 4.11%. In study conducted by Dixit D et al. [12] out of the total 228 limbs, the MCFA in 53 cases was arising from FA while the LCFA was arising from FA in only 18 cases. Thus, the incidence of MCFA

arising from FA is higher than that of LCFA. It has been reported that the branching pattern type 1 ranges from 40-83.3%, type 2 ranges from 14-51% and type 3 ranges from 0.5-20%. The average frequencies for type 1, 2, 3 are 64.4%, 30% and 14.2% respectively [13]. In the study done by Vishal K et al., they observed that the type 1 branching pattern was observed in 56.2% cases, type 2 was in 39.6% cases and type 3 in 4.2% cases [14].

The arterial supply of the femoral head is usually compromised after femoral neck fractures. The MCFA is the main artery that supplies the femoral head and neck [15]. The branches of LCFA are used in anterolateral thigh flaps [16] and aortopopliteal bypass [17].

The PFA is used for arteriography, ultrasound and doppler imaging, digital subtraction angiography and magnetic resonance imaging [18]. Therefore, clinicians, radiologists and surgeons should be familiar with the variations of these arteries.

PFA is an important vessel for the collateral circulation during the situation of FA occlusion and for this function; PFA should have a larger caliber. The knowledge of the branching patterns of the arteries in femoral triangle is important in avoiding the iatrogenic injury to the vessels and helps in preventing the femoral arteriovenous fistula while performing the FA puncture [19].

An ultrasound examination of the upper thigh is advised before performing catheterization of femoral vessels and upper thigh surgical procedures which provides structural information about the femoral vessels and will be helpful in planning the catheterization [20].

CONCLUSION

Knowledge of the variations of the site of origin and course of PFA and its circumflex branches is of diagnostic significance and is important in various surgical procedures and reduces chances of peri-operative complications. The above mentioned anatomical facts about PFA and its branches should be kept in mind before planning diagnostic and/or therapeutic interventions.

Conflicts of Interests: None

REFERENCES

- [1]. Standing S. Pelvic girdle, gluteal region and hip joint, Profunda femoris artery. In: Gray's Anatomy, The anatomical basis of clinical practice. 40th ed. Elsevier Churchill Livingstone, 2008:1379-1380.
- [2]. Savithri P. A rare variation of trifurcation of right femoral artery. International Journal of Anatomical Variations. 2013;6:4-6.
- [3]. Kaplan JL, Allen RJ. A cost based comparison between perforator flaps and TRAM flaps. Plast Reconstr Surg 2000;105(3):943-948.
- [4]. Langer R, Langer M, Scholz A, Astinet F, Schwetlick G, Felix R. Femoral head perfusion in patients with femoral neck fracture and femoral head necrosis. J Belge Rad, 1993;76:145-149.
- [5]. Gautier E, Ganz K, Krügel N, Gill T, Ganz R, Anatomy of the medial femoral circumflex artery and its surgical implications. Journal of Bone and Joint Surgery. Br. 2000;82(5):679-683.
- [6]. Vazquez MT, Murillo J, Maranillo E, Parkin I, Sanudo J. Patterns of circumflex femoral arteries revisited. Clinical anat. 2007;20:180-5.
- [7]. Ciftcioglu E, Kale A, Kopuz C, Edizer M, Aydin E, Demir MT. Medial circumflex femoral artery with different origin and course: a case report and review of the literature. Folia Morphol. 2009;68:188-91.
- [8]. Sahin B, Uzun A, Emirzeoglu M, Kosif R, Bilgic S. A deep femoral artery passing in front of the femoral vein. Folia Morphol. 2003;62:143-6.
- [9]. Prakash, Kumar J, Kumar BA, Jose BA, Kumar YS, Singh G. Variations in the origins of the profunda femoris, medial and lateral femoral Circumflex arteries: a cadaver study In the Indian population. Romanian Journal of Morphology and Embryology. 2010;51(1):167-170.
- [10]. Dixit DP, Mehta LA, Kothari ML. Variations in the origin and course of profunda femoris artery. Journal of Anatomical Society of India. 2001;50(1):6-7.
- [11]. Vuksanovic-Bozanic, Stefanovic N, Pavlovic S, Duraskovic R, Randelovic J. Analysis of deep femoral artery origin variances on fetal material. Facta Universitatis: Medicine and biology. 2007;14(3):112-116.
- [12]. Dixit D, Kubavat DM, Rathod SP, Patel MM, Singel TC. A study of variations in the origin of profunda femoris artery and its circumflex branches. Int J Biol Med Res. 2011;2(4):1084-89.
- [13]. Vazquez MT, Murillo J, Maranillo E, Parkin I, Sanudo J. Patterns of the circumflex femoral arteries revisited. Clin Anat. 2007;20:180-5.
- [14]. Vishal K, Murlimanju BV. Variability in the origin of Lateral and medial circumflex femoral arteries: an anatomical study in South Indians. International Journal of Anatomy and Research. 2014;2(4):692-696. DOI: 10.16965/ijar.2014.528.
- [15]. Shanahan D, Jordan RK. Rare origin of the inferior epigastric artery from an anomalous medial circumflex femoral artery. J Anat. 1997;191:611.

- [16]. Valdatta L, Tuinder S, Buoro M, Thione A, Faga A, Putz R . Lateral circumflex femoral artery system and perforators of the anterolateral thigh flap, an anatomic study. *Ann plast surg.* 2002;49:145-150.
- [17]. Sugawara Y, Sata O, Miyata T, Kimura H, Namba T, Mukuuchi M .Utilization of the Lateral circumflex femoral artery as a midway outflow for aortopopliteal grafting. report of a case. *Surgery today.* 1998;28:967-970.
- [18]. Chitra R. Arare variational anatomy of the profunda femoris artery. *Folia Morphol.* 2008;67:157-8.
- [19]. Vaas F. Some considerations concerning the deep femoral artery. *Arch Chir Neerl* 1975;27:25-34.
- [20]. Canale JM, Lange L, Friedman MJ. A new technique for noninvasive evaluation of femoral arterial and venous anatomy before and after percutaneous cardiac catheterization in children and infants. *Am J Cardiol.* 1982;49:349-55.

How to cite this article:

Pretty Rathnakar, Vinay Kumar V, Remya Vinod, Beena Nandan. VARIATIONS IN BRANCHING PATTERN OF PROFUNDA FEMORIS ARTERY AND ITS CIRCUMFLEX BRANCHES. *Int J Anat Res* 2016;4(1):1922-1926. **DOI:** 10.16965/ijar.2016.114