

INCIDENCE OF SUTURAL BONES AT PTERION IN SOUTH INDIAN DRIED SKULLS

Raja Sekhar Katikireddi ^{*1}, Siva Nageswara Rao Sundara Setty ².

^{*1} MD, Associate Professor, Department of Anatomy, Bhaskar Medical college, Yenkapally (V), Moinabad mandal, Ranga Reddy District, Telangana, India.

² MD, Professor, Department of Anatomy, Bhaskar Medical college, Yenkapally (V), Moinabad mandal, Ranga Reddy District, Telangana, India.

ABSTRACT

Introduction: Sutural or Wormian bones are usually small irregular ossicles in related with the cranial sutures. They are formed because of the extra ossification centers in the vicinity of sutures.

Materials and Methods: Study conducted on 75 dried human skulls to find the incidence and type of of sutural bones at pterion in related to south Indian population.

Results: Present study concluded 4% of prevalence out of 75 cases, Right side one case and left side 2 cases were noticed, all were epipteric type of sutural pattern.

Conclusion: Anatomical Knowledge of this kind of variations are important for anthropologists, radiologists, orthopaedic surgeons, and neurosurgeons.

KEY WORDS: Skull, Wormian bones, Sutural bones.

Address for Correspondence: Dr. Raja Sekhar Katikireddi, Associate Professor, Department of Anatomy, Bhaskar Medical College, Yenkapally (V), Moinabad (Mandal), Ranga Reddy District, Pin: 500075, Telangana, India. Mobile: +919849953620 **E-Mail:** rajasekharkatikireddi@yahoo.com

Access this Article online

Quick Response code



DOI: 10.16965/ijar.2016.154

Web site: International Journal of Anatomy and Research
ISSN 2321-4287
www.ijmhr.org/ijar.htm

Received: 18 Feb 2016 Accepted: 10 Mar 2016
Peer Review: 18 Feb 2016 Published (O): 31 Mar 2016
Revised: None Published (P): 31 Mar 2016

INTRODUCTION

A sutural or wormian bone is occasionally present at the pterion at the junction of the parietal, frontal, greater wing of the sphenoid, and squamous part of the temporal bones on temporal fossa. This bone is called pterion ossicle or epipteric bone or Flower's bone [1]. Pterion is an important landmark for age, sex determination and also in archaeological studies. According to Broca [2]. pterion was classified into three types, sphenoparietal, frontotemporal and stellate and later Murphy [3] classified this into four types sphenoparietal,

frontotemporal, stellate and epipteric types. Knowledge of incidence of sutural bone at pterion is radiological importance so variations at pterion useful for neurosurgeons, radiologists, and anthropologists.

MATERIALS AND METHODS

Present study was conducted in 75 dried adult human skulls of unknown sexes in the department of anatomy, Bhaskar Medical College, Yenkapally village, Moinabad Mandal, Ranga Reddy District, Telangana, south India. This study concluded the occurrence of sutural

bones at pterion and its type in south Indian population.

RESULTS

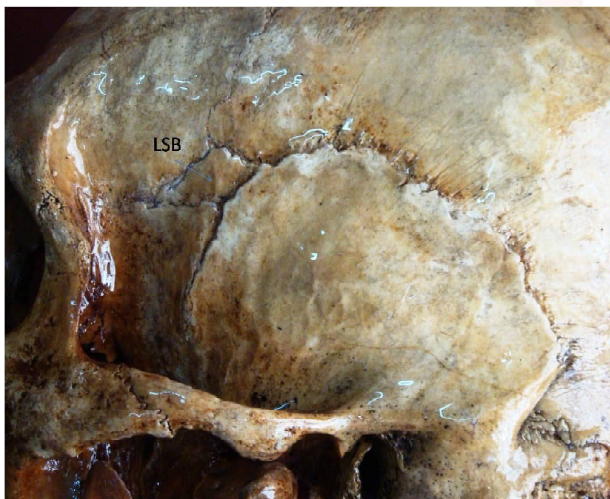
Fig. 1: Right side temporal fossa of skull shows RSB: Right Sutural Bone.

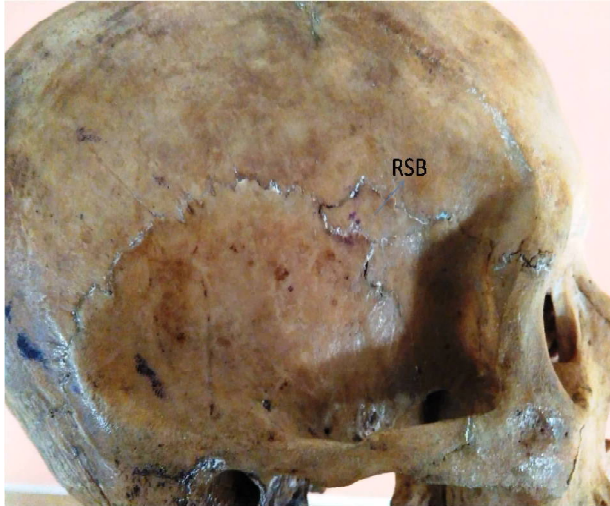

Fig. 2: Left side temporal fossa of skull shows, LSB: Left Sutural Bone.

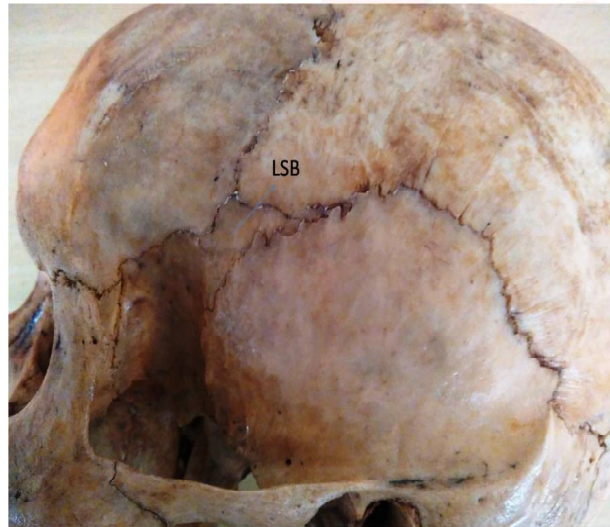

Fig. 3: Left side temporal fossa of skull shows, LSB: Left Sutural Bone.



Present study was found unilateral occurrence of sutural bones at pterion in 3 skulls out of 75 and, the incidence was 4 percent. Bilateral sutural bones at pterion were not noticed in any case. In the Present study Right side one case (Fig. 1) left side 2 cases were noticed (Fig: 2 and 3). All the occurrence cases were related to epipteric type according to Murphy's classification.

DISCUSSION

According to Bergman et al., 40% of skulls have sutural bones in the lambdoid suture [4]. The reason for the occurrence of the wormian bones may be regulated by a genetic factor [5]. Sutural bones incidence is more in Indian skulls, according to Saxena et al., studies 11.79% of Indian skulls had this kind of bones [6]. Nair et al., [7] showed that the gross incidence of epipteric or wormian bones at pterion was 6% and the percentage of occurrence of single large epipteric bone was more than the small multiple epipteric bones. Satheesha Nayak B et al., noticed one sutural bone at pterion on right side in Indians [8]. Hussian Sahib. S et al., showed the presence of two sutural bones at right side and a single unilateral sutural bones on left side at pterion [9]. Raju Sugavasi et al., noticed single unilateral sutural bone on left side at pterion in indian population [10]. According to Pryles C V et al., the presences of such variant sutural bones are usually associated with cranial and central nervous system anomalies [11]. Ersoym M et al., recommended that the presence of epipteric bones at pterion region may cause complications while performing Burr holes during neuro-surgeries [12].

CONCLUSION

Incidence of unilateral presence of sutural bones at pterion is 4% in south Indian population. Presence of sutural or epipteric bones at pterion region may be mistaken for fracture of skull. Such epipteric bones at pterion region may be the reason for complications while performing Burr holes during neuro-surgeries.

ACKNOWLEDGEMENTS

Authors are grateful to Professor & HOD Anatomy department and previous authors,

Publishers, editors of all those previous articles, journals and books from where the literature of this article has been reviewed and discussed.

Conflicts of Interests: None

REFERENCES

- [1]. Malhotra VK, Tewari PS, Pandey SN, Tewari SP. Interparietal bone. *Acta Anat. (Basel)*. 1978;101:94-96.
- [2]. Broca, P. Instructions craniologiques et craniométriques. *Mém. Soc. Anthropol. Paris*, 1875;2:1-203.
- [3]. Murphy, T. The pterion in the Australian aborigine. *Am. J. Phys. Anthropol.*, 1956; 14(2):225-44.
- [4]. Bergman RA, Afifi AK, Miyauchi R. Skeletal systems: Cranium. In: *Compendium of human anatomical variations*. Baltimore, Urban and Schwarzenberg, 1988;197-205.
- [5]. El-Najjar M, Dawson GL. The effect of artificial cranial deformation on the incidence of Wormian bones in the lambdoidal suture. *Am. J. Phys. Anthropol.* 1977;46:155-160.
- [6]. Saxena SK, Jain SP, Chowdhary DS. A comparative study of pterion formation and its variations in the skulls of Nigerians and Indians. *Anthropol. Anz.* 1988;46:75-82.
- [7]. Nair S, Gour KK, GN Trivedi, Budhiraja V, Rastogi. Morphological study of Epipteric Bones in North Indian Skulls. *Int J Cur Bio Med Sci.* 2011;1(4):166-168.
- [8]. Satheesha Nayak B, Soumya KV. Unusual sutural bones at Pterion. *International Journal of Anatomical variations*. 2008;1:19-20.
- [9]. Hussain Saheb S, Haseena S, Prassana LC. Unusual wormian bones at Pterion- Three Case Reports. *J Biomed Sci and Res.* 2010; 2(2):116-118.
- [10]. Raju Sugavasi, Sujatha. M, Indira Devi. B, Sirisha. B, Unusual sutural bone at pterion. a case report. *International Journal of Current Research and Review.* 2012;04(07):101-103.
- [11]. Pryles CV, Khan AJ. Wormian Bones. A Marker of CNS Abnormality. *Am. J. Dis. Child.* 1979;133:380-382.
- [12]. Ersoy M, Evliyaoglu C, Bozkurt MC, Konuskan B, Tekdemir I, Keskil IS. Epipteric Bones in the Pterion may be a Surgical Pitfall. *Minim. Invasive Neurosurg.* 2003;46:363-365.

How to cite this article:

Raja Sekhar Katikireddi, Siva Nageswara Rao Sundara Setty. INCIDENCE OF SUTURAL BONES AT PTERION IN SOUTH INDIAN DRIED SKULLS. *Int J Anat Res* 2016;4(1):2099-2101. DOI: 10.16965/ijar.2016.154