

STUDY OF BRANCHING PATTERN OF SPLENIC ARTERY

Ashok K R ^{*1}, Kiran T V ².

^{*1} Assistant Professor, Department of Anatomy, BGS Global Institute of Medical Sciences, Bengaluru, Karnataka, India.

² Associate Professor, Department of Anatomy, BGS Global Institute of Medical Sciences, Bengaluru, Karnataka, India.

ABSTRACT

Background: Surgeons and radiologists need detailed anatomic vascular information. The color doppler flow imaging is a major diagnostic tool in preoperative assessment for laparoscopic splenectomy which helps in selecting the operative procedures and treatment modalities. Knowledge of splenic artery anatomy coupled with preoperative evaluation helps to reduce the operation time and intraoperative complications.

Materials and Methods: 76 cadavers have been dissected to study the branching pattern of the splenic artery.

Results: Splenic artery divides in distributed pattern or bundled pattern before entering the hilum of spleen. However in few cases splenic artery enters the spleen without dividing into terminal branches. In our study distributed pattern was seen in 55.3% cases, bundled type in 34.2% cases and splenic artery entered the hilum without branching in remaining 10.5% cases.

Conclusion: As sepsis occurs as sequel in post splenectomy patients the spleen preserving surgeries are gaining importance. Spleen preserving surgeries can be performed in distributed and bundled type of splenic artery.

KEY WORDS: Splenic artery, splenectomy, spleen preserving surgery.

Address for Correspondence: Dr. Ashok. K. R, Assistant Professor, Department of Anatomy, BGS Global Institute of Medical Sciences, Kengeri, Bengaluru, Karnataka – 560060, India.
Phone No: 91 – 9743006759 **E-Mail:** hingyake@gmail.com

Access this Article online

Quick Response code



DOI: 10.16965/ijar.2016.145

Web site: International Journal of Anatomy and Research
ISSN 2321-4287
www.ijmhr.org/ijar.htm

Received: 12 Feb 2016 Accepted: 03 Mar 2016
Peer Review: 12 Feb 2016 Published (O): 31 Mar 2016
Revised: None Published (P): 31 Mar 2016

INTRODUCTION

Historically spleen was considered as a vestigial organ and was surgically removed even for minor ailments and injuries. After understanding the fact that the spleen is called upon primarily to eliminate senescent and damaged cells from the circulation, to filter the antigens and its role in immunological response; spleen preserving surgeries gathered importance [1]. The Splenic artery gives numerous branches that supplies nutrition to the stomach, pancreas, and greater omentum and finally ends by supplying

the spleen. Based on terminal branching pattern, the splenic artery pedicle can be classified into distributed type where the splenic artery divides away from the hilum of the spleen with long terminal branches that enters through the hilum and bundled/marginal type where the artery divides at the hilum with short terminal branches. The number of terminal branches varies from 2 to 6 or even more [2]. In some individuals the splenic artery enters through the hilum without giving any terminal branches.

Incidence of splenic injury is on the rise owing

to increase in road traffic accidents. Now splenectomy is not the first choice of treatment modality which is replaced by non operative management and spleen preserving surgeries like partial splenic artery embolization, ligation of terminal branches of the splenic artery. Splenic artery aneurysm is the most common aneurysm in the abdomen next to aortoiliac aneurysm [3]. Knowledge of the branching pattern of splenic artery helps to plan spleen preserving surgeries.

Keeping in mind the applied importance and to add up some more knowledge to the already existing ones, the present study was undertaken to know the branching pattern of splenic artery.

MATERIALS AND METHODS

76 embalmed cadavers from Department of Anatomy in M.R. Medical College, HKE's Homeopathic College, Kalburgi; Navodaya Institute of Medical Sciences, Raichur; JSS Medical College, Mysuru; KVG Medical College Sullia and BGS Global Institute of Medical sciences were used for this study.

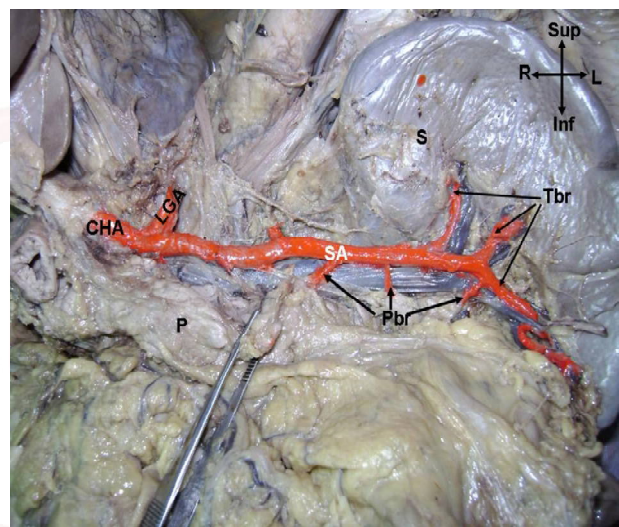
Peritoneal cavity was explored. Stomach was turned superiorly. As the pancreas was uncovered the celiac trunk was identified and the dense autonomic plexus around it was cleared. Then the splenic artery was traced distally. The terminal branching pattern of splenic artery was noted. The splenic artery and its terminal branches were painted with red color and photographed.

RESULTS AND DISCUSSION

Splenic artery entered the hilum without branching in 8 cases (10.5%). Distributed type, where the splenic artery divides away from the hilum of spleen with long terminal branches that enter through the hilum was observed in 42 cases (55.3%). Bundled/ Marginal type, where the splenic artery divides at the hilum with short terminal branches was seen in 17 cases (34.2%). Treutner et al [4] studied 32 spleens obtained from autopsy by angiographies and corrosion cast method. They observed distributed pattern in 84.4 % cases and bundled type in 9.4 % cases. They couldn't classify the remaining 6.2 %. Pandey S K et al [2] studied the branching pattern in 320 cadavers. They observed splenic

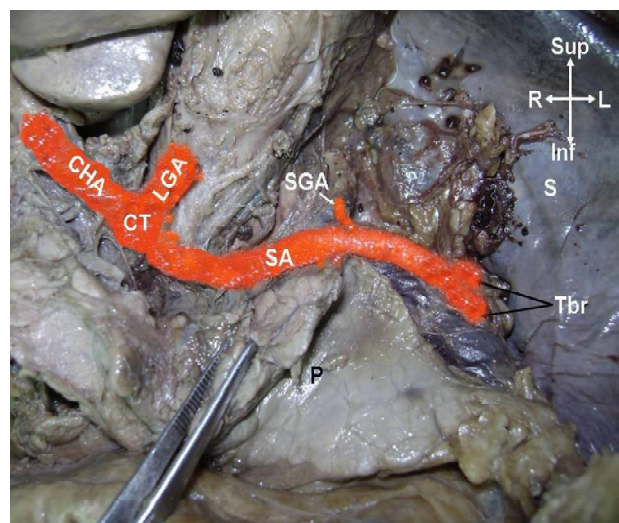
artery without terminal branches in 2.8 % cases. The disparity between Pandey S K et al and our study might be due to variation in the number of cadavers dissected. Pandey S K didn't classify the branching pattern, together it is 97%. XU wei – li et al [5] retrospectively evaluated the color doppler imaging for the determination of splenic vascular pattern in patients who underwent laparoscopic splenectomy. They observed distributed pattern of splenic pedicle in 69.6 % cases and bundled pattern in the remaining 30.4 % cases. They didn't observe splenic artery without terminal branches.

Fig. 1: Distributed type with long terminal branches.



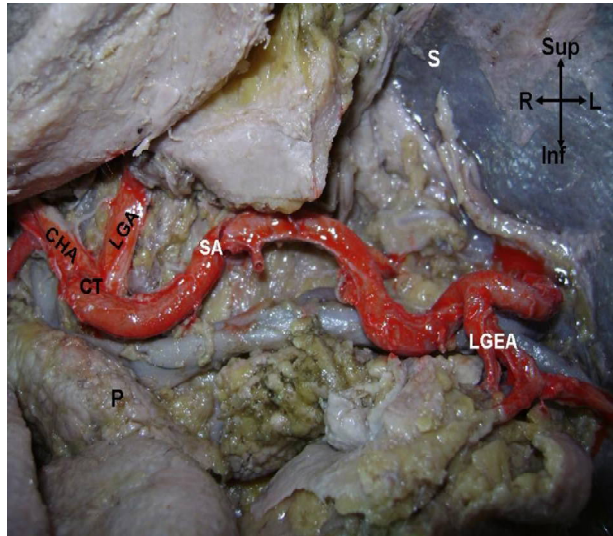
CHA – Common hepatic artery, LGA – Left gastric artery, SA – Splenic artery, Tbr – Terminal branches, Pbr – Pancreatic branches, S – Spleen, P – Pancreas

Fig. 2: Bundled type with short terminal branches.



CHA – Common hepatic artery, LGA – Left gastric artery, SA – Splenic artery, CT – Celiac trunk, Tbr – Terminal branches, S – Spleen, P – Pancreas, SGA – Short gastric artery

Fig. 3: Splenic artery entering spleen without any terminal branches.



CHA – Common hepatic artery, LGA – Left gastric artery, SA – Splenic artery, CT – Celiac trunk, S – Spleen, P – Pancreas, LGEA – Left gastro epiploic artery

Table 1: Terminal branching pattern compared with other studies.

Study	Year	Entered hilum without branching	Distributed type	Bundled type
Pandey S K et al [2]	2004	2.80%	97%	
Treutner et al [4]	1993	-	84.40%	9.40%
XU wei – li et al [5]	2009	-	69.60%	30.40%
Present Study	2015	10.50%	55.30%	34.20%

The knowledge of the pattern of splenic artery termination and its identification in color doppler flow imaging is important while planning for laparoscopic splenectomy. In distributed type of splenic artery termination the ligation of splenic artery prior to splenectomy should be done individually whereas in bundled pattern the trunk can be cut off [5]. Spleen preserving surgeries can be performed better in distributed pattern[6].

CONCLUSION

Branching pattern of the splenic artery was studied in the cadavers by dissection method. As sepsis occurs as sequel in post splenectomy patients the spleen preserving surgeries are

gaining importance. Spleen preserving surgeries can be performed in distributed and bundled type of splenic artery. The distal terminal branch of the injured segment can be embolized separately in distributed type of termination as the embolization of the main trunk may lead to post procedure splenic infarction and abscess.

ACKNOWLEDGEMENTS

We would like to acknowledge teaching and non teaching staff and students of Department of Anatomy in M.R. Medical College, HKE's Homeopathic College, Kalburgi; Navodaya Institute of Medical Sciences, Raichur; JSS Medical College, Mysuru; KVG Medical College Sullia and BGS Global Institute of Medical sciences

Conflicts of Interests: None

REFERENCES

- [1]. W. Henry Hollinshead, Cornelius Rosse. Textbook Of Anatomy, 4th edition, Harper and Row Publishers; 1985:629.
- [2]. Pandey SK, Bhattacharya S, Mishra RN, Shukla VK. Anatomical variations of the splenic artery and its clinical implications. Clin Anat 2004;17:497-502.
- [3]. Michael M. Herskowitz, Yair Safriel, Virgillio Gillego. Embolization of a Giant Splenic Artery Aneurysm with Only Proximal Coil Embolization: A Case Report. International Journal of Angiology 2003;12:209-210.
- [4]. Karl H. Treutner, Bernd Klosterhalfen, Gerd Winkeltau, Sylvia Moench, Volker Schumpelick. Vascular Anatomy of the Spleen: The Basis of Organ – Preserving surgery. Clin Anat 1993;6:1-8.
- [5]. XU Wei-li, LI Suo-lin, WANG Yan, SHI Bao-jun, LI Meng, LI Ying-chao et al. Laparoscopic splenectomy: color Doppler flow imaging for preoperative evaluation. Chinese Medical Journal 2009;122(10):1203-1208.
- [6]. Sow ML, Dia A, Ouedraogo T Anatomic basis for conservative surgery of the spleen. Surg Radiol Anat 1991;13(2):81-7.

How to cite this article:

Ashok K R, Kiran T V. STUDY OF BRANCHING PATTERN OF SPLENIC ARTERY. Int J Anat Res 2016;4(1):2073-2075. DOI: 10.16965/ijar.2016.145