

ANTHROPOMETRIC MEASUREMENTS OF INFRAORBITAL FORAMEN AND ITS ANATOMIC VARIATIONS IN DRIED HUMAN SKULLS

Shikha Sharma ^{*1}, Anil Sharma ², Chetna Thakur ³, Bhawani Shankar Modi ⁴.

^{*1} Associate Professor, Department of Anatomy, FH Medical College, Tundla, Uttar Pradesh, India.

² Associate Professor, Department of Medicine, FH Medical College, Tundla, Uttar Pradesh, India.

³ Assistant Professor, Department of Anatomy, FH Medical College, Tundla, Uttar Pradesh, India.

⁴ Tutor, Department of Anatomy, FH Medical College, Tundla, Uttar Pradesh, India.

ABSTRACT

Aim: This study was to determine the distance between IOF and IOM, IOF and pyriform aperture, the presence of accessory foraminae, orientation and location in relation with teeth on both the sides.

Materials and Methods: Fifty dried human skulls (100 sides) irrespective of age and sex were used for this study. The distance between the IOF and IOM and the distance between the IOF and pyriform aperture were measured by using manual vernier calliper. The orientation, location in relation with teeth and presence of accessory foramina were observed macroscopically.

Observations and Discussion: Accessory foramina may give complications during anaesthetization of this region. The mean distance between the IOF and infraorbital margin was 22.6mm and 15.2mm on the left and right side respectively. Mean distance between I.O.F and pyriform aperture was 26.2mm and 25.8mm on the left and right side respectively. In 30% skulls the IOF were directed vertically downward on the right side and in 38% on the left side. In 66% downward medially on the right side and 56% on the left side and in 4% skulls medially on the right side and 6% on the left side. The majority of IOF were oriented to second premolar teeth on the right side and between second premolar and first molar on the left side. Accessory foraminae were found in 6% of skulls. The results of our study may be helpful during surgical procedures in the maxillary region in reduction of Lefort fracture, and giving regional nerve block.

KEY WORDS: Infraorbital foramen, Infraorbital margin, Pyriform aperture, Manual vernier calliper.

Address for Correspondence: Dr. Shikha Sharma, FH Medical College, Anatomy Department, Near Etmadpur, Railway over Bridge, NH-2, Tundla Dist., Firozabad, Uttar Pradesh 283201, India.

E-Mail: anilsharma4160@gmail.com

Access this Article online

Quick Response code



DOI: 10.16965/ijar.2015.272

Web site: International Journal of Anatomy and Research
ISSN 2321-4287
www.ijmhr.org/ijar.htm

Received: 16 Sep 2015

Accepted: 02 Oct 2015

Peer Review: 16 Sep 2015

Published (O): 31 Oct 2015

Revised: None

Published (P): 31 Dec 2015

INTRODUCTION

Infraorbital margin is formed laterally by the zygomatic bone and medially by the maxilla. Infraorbital foramen is situated about 1cm below the infraorbital margin for the passage of infraorbital nerves and vessels. [1,2]. Infraorbital nerve appears on the face through

infraorbital foramen and give sensory innervations to lower eyelid, side of nose and upper lip through its palpebral, nasal and labial branches [3,4]. The position of the infraorbital foramen varies from 4-12mm [5,6]. The knowledge about the position of the infraorbital foramen provides important data in giving

local anesthesia in maxillofacial and plastic surgeries [7-10]. The knowledge about the presence of supernumerary foraminae help in performing surgeries in relation to the infraorbital foramen and giving regional nerve block.

MATERIALS AND METHODS

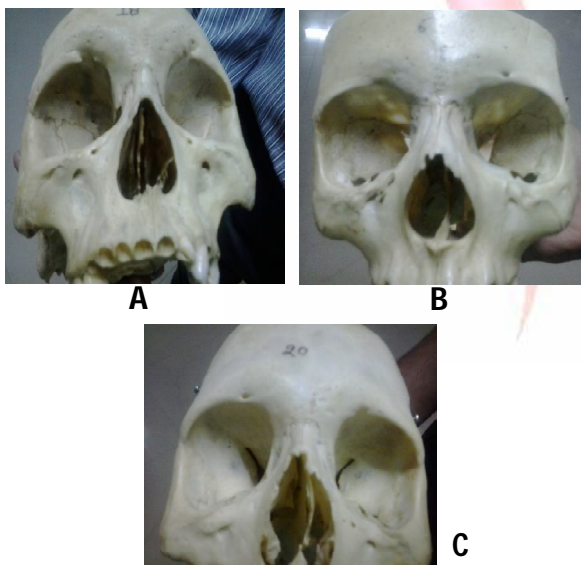
Fifty dried skulls of unknown age and sex were selected from the department of CMCH BHOPAL and FHMC TUNDLA for this study and the following measurements and observations were recorded.

1. The distance of IOF from the infraorbital margin at the zygomaticomaxillary suture with the help of manual vernier calliper with least count of 0.1mm.
2. Transverse measurements were taken from the IOF to the medial margin of pyriform aperture.
3. Orientation of the IOF with the upper teeth.
4. Direction of the IOF was noted as vertically downward, downward medially and medially.
5. The presence of accessory foraminae.

OBSERVATIONS

Fifty human dried skulls (both the sides) were examined. The mean value of the vertical distance of IOF from the infraorbital margin was found to be 22.6mm on the left side and 15.2 mm on the right side. The maximum distance recorded was 21mm and the minimum distance was 9mm on the left side.

Fig. 1: Showing presence of accessory foraminae.



The maximum distance on the right side was 21 mm and minimum was 11mm. The maximum distance between the IOF and pyriform aperture was 31mm and minimum was 19mm on the left side while on the right side the maximum distance was 30 mm and minimum distance was 19mm. The mean of the transeverse distance was 26.2 mm on the left side and 25.8 mm on the right side. Accessory foraminae were present in three skulls of which it was unilateral in two skulls and bilateral in one skull as shown in fig. 1 and 2.

Fig. 2: Vertical and Transverse Measurements.

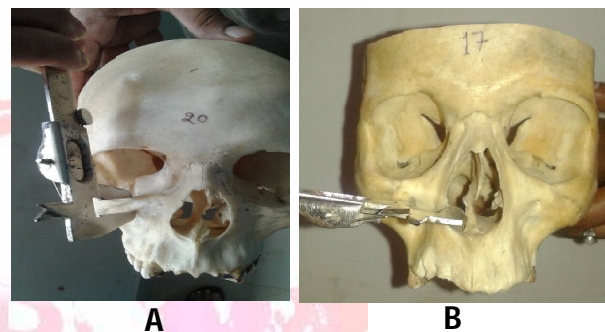


Table 1: Morphometric Measurement Mean Values.

Plane of measurement	Left side	Right side
Vertical	22.6mm	15.2mm
Transverse	26.2mm	25.8mm

Table 2: Morphometric Measurements of Accessory Foramen.

S.No	Vertical measurement		Transverse measurement	
	Right Side	Left side	Left Side	Right Side
1	4mm	11mm	17mm	19mm
2	3mm	9mm	11mm	14mm
3	-	8mm	7mm	-

Table 3: Orientation of IOF with the Teeth.

Teeth	Right side no and %	Left side no and %
1 st MO	6(12%)	8(16%)
2 nd PM/1 st MO	6(12%)	10(20%)
1 st PM/2 nd PM	5(10%)	6(12%)
2 nd PM	14(28%)	6(12%)
2 nd MO	2(4%)	2(4%)
1 st MO/2 nd MO	2(4%)	1(2%)
Edantulous	15(30%)	17(34%)

Table 4: Showing the direction of IOF.

Direction	Right side no and %	Left side no and %
DM	33(66%)	28(56%)
VD	15(30%)	19(38%)
M	2(4%)	3(6%)

Table 5: Comparison of Present Study with Previous Study.

Study	No of samples	Mean Distance of IOF from IOM mm	Accessory foramen %
Aziz et al 2000 [7]	47	8.3±1.9	15
Cutright et al	80	6.4±0.3	-
Elias et al 2004 [19]	210	6.71±1.70	15.23
Bhoopati et al 2010 [17]	80	6.57±1.7	16.25
Present study	50	15.2(rt),22.6mm(lt)	15

DISCUSSION

The knowledge of anatomical features of IOF is essential for the surgeons dealing with maxillary region like surgeries for fractures of zygoma [11], intra or extra-oral anaesthesia [12,13]. The distance between IOF and IOM had been reported to lie between 4-10mm [7,14,15]. The mean distance in between IOF and IOM our study was 22.6mm and 15.2mm on the left and right side respectively, which was on the higher side as compared with the previous study. The knowledge of location of IOF is mandatory to avoid injuries of eye during nerve block and during surgeries of comminute fracture of maxilla or inferior orbital wall. Gruber [16] reported first the presence of accessory infraorbital foramen. Bhoopati et al [17] reported accessory foramen in 16.25% of skulls in south Indians. In present study. The incidence of AF was lower than the previous studies. Regarding double AF, present study coincide with the findings of Kadnoff [18] Most of the IOF were directed downward and medially as revealed by Ellias [19]. In our study 38% IOF were directed vertically downward and in 6% directed medially. It is necessary to know the direction of IOF while passing needle to block the nerve and to direct the probe in radiofrequency neurotomy procedures. Our study showed that in the 10% the tooth most commonly noted in the same vertical line was between second premolar and first molar on the left side and in 14% cases the tooth in the same vertical plane was second premolar on the right side.

CONCLUSION

The knowledge of the location of IOF, presence of accessory foramina and morphometric measurement is very useful to maxillofacial surgeons as in reduction of Lefort's fracture, for anaesthetist while giving regional nerve block

for the better outcome of diagnostic or therapeutic procedures.

ABBREVIATIONS

IOF- Infra Orbital Foramen,
IOM- Infra Orbital Margin,
PM- Premolar,
MO- Molar,
DM- Directed medially,
VD- Vertically directed
M- Medially
AF- Accessory Foramen.

ACKNOWLEDGEMENTS

I am thankful to Mr. Ramesh and Mr. Mukesh who helped me in taking photographs. I am also thankful to Ms. Shilpi who helped me in the drafting of the text.

Conflicts of Interests: None

REFERENCES

- Williams P.L., Warwick R, M Bannister L.H. Gray Anatomy. 37th ed, New York, Churchill Livingstone, 1989.
- Gardner E, Gray, D.J, O'Halley R. Anatomia: estudo regional do corpo humano, 4th ed. Rio de Janeiro Guanabara Koogan, 1988.
- Mc Minn RMH. Pterygopalatine fossa. In, Sinnathamy CS, ED. Last's ANATOMY, Regional and Applied. London; Churchill Livingstone, 1990:451-67.
- Moore KL, Dalley AF. Nerves of the face, In: Moore KL, DALLEY AF, Eds. Clinically Oriented Anatomy, 4th ed. Philadelphia: Lippincott Williams & Wilkins, 1999:832-993.
- Testut L, Latarjet, Tratado de anatomia humana. Barcelona, Salvat, 1954.
- Bergman R.A, Thompson S.A, Afifi A.K, Saddle F.A. Compendium of Human Anatomic Variation; Catalog, Atlas and World Literature. Baltimore. Urban & Schwarzenberg, 1988.
- Aziz S.R, Marchena J.M, Puran. Anatomic characteristics of the infraorbital foramen: A cadaver study. J. Oral Maxillofac. Surg. 2000;58:992-6.
- Hwang K and Baik SH. Surgical anatomy of Korean adults. Journal of Craniofacial Surgery 1999;10:129-34.
- Rontal E, Rontal M and Guilford FT. Surgical anatomy of the orbit. Annals of Otolaryngology 1979;88:382-6.
- Triandafillidi E, Anagnostopoulou S and Soumilia M. The infraorbital foramen (the position of the infraorbital foramen in man). Odontostomatologike proodos. 1990;44:8791.
- Du Tolt D.F, Nortje C. The maxillae: Integrated and applied anatomy relevant to Dentistry. SADJ., 2003;58(8):325-30.

- [12]. Hollandshed, W.H. The head and neck., In; Anatomy for surgeon. Harper and Row, Philadelphia, 1982.
- [13]. Figun, M.E, Garino, R.R Anatomia odontologica funcional epicada. Sao Paulo. Panamericana, 1994.
- [14]. Chung M, Kim, J Kang HS, Chung, I.H. Locational relationship of the supraorbital notch or foramen and infraorbital and mental foramina in Koreans. Acta Anat (Basel). 1995;154(2):162-6.
- [15]. Zide BM., Swift R. How to block and tackle the face. Plast Reconstr Surg. 1998;101:840-51.
- [16]. Gruber W. Ein hakenformiges Fortsatzchen uber und vor dem infraorbitalloche. Arc. Pathol. Anat. Physiol. Klin. Med., 1878;72:494-6.
- [17]. Bhoopati S, Chakravarthy Marx S, Dhalapathy S, Anupa S. Anthropometric analysis of the infraorbital foramen in a South Indian population. Singapore medj. 2010;51(9):730.
- [18]. Kadanaff D, Mutafov ST and Jordanov J. Uber die Hauptoffnungen Resp. Incisurae des Gesichtsschadels. Morphologisches Jahrbuch 1970;115:102-108.
- [19]. Elias MG, Silva RB, Pimental ML. Morphometric analysis of the infraorbital foramen and accessories foraminas in Brasillian skulls. Int J Morphol. 2004;22:273-8.

How to cite this article:

Shikha Sharma, Anil Sharma, Chetna Thakur, Bhawani Shankar Modi. ANTHROPOMETRIC MEASUREMENTS OF INFRAORBITAL FORAMEN AND ITS ANATOMIC VARIATIONS IN DRIED HUMAN SKULLS. Int J Anat Res 2015;3(4):1487-1490. DOI: 10.16965/ijar.2015.272