

## Case Report

# ACCESSORY LOBE OF RIGHT LUNG

**A.K. Manicka Vasuki <sup>1</sup>, K.Kalyana Sundaram <sup>2</sup>, T.K.Aleyemma Fenn <sup>3</sup>, Deborah Joy Hebzibah <sup>4</sup>, M. Nirmaladevi <sup>5</sup>, M. Jamuna <sup>6</sup>.**

<sup>1</sup> Assistant Professor, Department of Anatomy, PSG Institute of Medical Sciences and Research, Coimbatore, Tamil Nadu, India.

<sup>2</sup> Associate Professor, Department of Anesthesiology, Coimbatore Medical College, Coimbatore, Tamil Nadu, India.

<sup>3</sup> Former Professor & HOD, Department of Anatomy, PSG Institute of Medical Sciences and Research, Coimbatore, Tamil Nadu, India.

<sup>4</sup> Assistant Professor, Department of Anatomy, PSG Institute of Medical Sciences and Research, Coimbatore, Tamil Nadu, India.

<sup>5</sup> Associate Professor, Department of Anatomy, PSG Institute of Medical Sciences and Research, Coimbatore, Tamil Nadu, India.

<sup>6</sup> Professor & HOD, PSG Institute of Medical Sciences and Research, Coimbatore, Tamil Nadu, India.

## ABSTRACT

Anatomical variations of lungs in the form of Accessory lobe and abnormality in the fissures are important for the surgeons to avoid possible injuries to the neighbouring structures. We report a case of Accessory lobe of right lung between middle and lower lobe in a male cadaver which was found during routine dissection in the Anatomy department, PSG IMS & R. Fissure and lobes of left lung was normal. Anatomical knowledge of such variations are helpful for Cardiothoracic surgeons in lobectomies, surgical resections involving individual segments and for Radiologists for interpreting X – rays,CT & MRI scans.

**KEY WORDS:** Lung, Lobes, Accessory lobe, Anatomical Variations.

**Address for Correspondence:** Dr.A.K.Manicka Vasuki, Assistant Professor, Department of anatomy, PSG Institute of Medical Sciences and Research, Coimbatore-641004, Tamil Nadu, India.

**E-Mail:** [vasukikalyan01@gmail.com](mailto:vasukikalyan01@gmail.com)

## Access this Article online

### Quick Response code



DOI: 10.16965/ijar.2015.264

**Web site:** International Journal of Anatomy and Research  
ISSN 2321-4287  
[www.ijmhr.org/ijar.htm](http://www.ijmhr.org/ijar.htm)

Received: 10 Sep 2015      Accepted: 02 Oct 2015  
Peer Review: 10 Sep 2015      Published (O): 31 Oct 2015  
Revised: None                      Published (P): 31 Dec 2015

## INTRODUCTION

Lungs are divided into lobes by oblique and horizontal fissures. Right lung is divided into superior, middle and inferior lobes by an oblique and horizontal fissure. The left lung is divided into superior and inferior lobes by an oblique fissure [1]. At the lower end of anterior border

of left lung, the cardiac notch and a small process called lingula is present. Lingula of left lung represents middle lobe of left lung. The present case describes an accessory lobe between middle and lower lobes of right lung. An Azygos lobe of the lung affects the upper lobe of right lung, present in 1% individuals, where

the apex of the lung splits into medial and lateral parts by a fissure. The medial part of split apex forms the lobe of Azygos vein [2].

Developmental anomalies of the lungs are important because they can cause complications during infancy, early childhood and adult period. They are classified into bronchopulmonary anomalies, vascular anomalies and combined lung and vascular anomalies. Development of lung starts at 28 days of embryonic life. During the development as the lungs grows the spaces or fissures that separate the individual bronchopulmonary segments become obliterated except along the two planes oblique or horizontal which give rise to the fissures. Due to partial or incomplete obliteration of spaces leads to incomplete or absent oblique or horizontal fissures. Accessory fissures of the lungs are described as clefts of various depths lined by two layers of visceral pleura.


Knowledge of an accessory fissure is helpful for clinicians to differentiate it from other normal anatomical and pathological structures. Incomplete fissure gives an atypical appearance of pleural effusion in X-ray. Accessory fissures fail to be detected on CT scans because of their incompleteness, thick sections and orientation in relation to particular plane.

Segmental localization is must in many diseases and accessory fissure and accessory lobe identification is important for the clinician. Preoperative planning for pulmonary lobectomy and segmental resection may change during presence of such accessory lobe and fissure. Incomplete fissure is a cause for postoperative air leakage. Pneumonia in particular lobe is often limited to that lobe by the fissures. Pneumonia can be wrongly interpreted as atelectasis or consolidation. Incomplete fissure is responsible for altering the spread of any lung disease.

### CASE REPORT

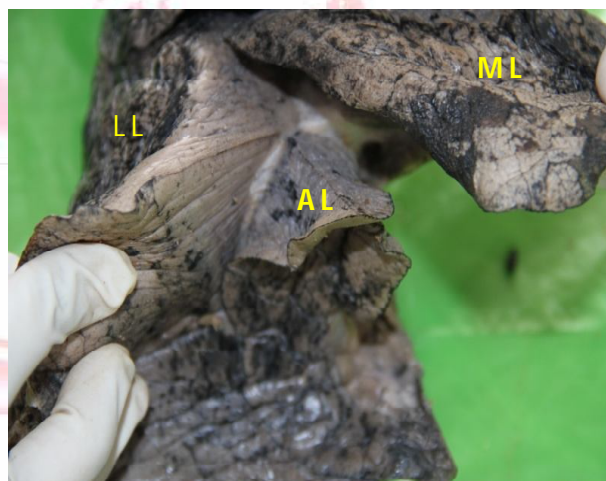
During routine dissection of male cadaver in the department of Anatomy, PSG IMS & R, it was observed that an accessory lobe was present in the right lung in addition to three lobes (superior, middle and inferior). The additional lobe with a small fissure was present between middle and the lower lobe. No abnormality was detected in

**Fig. 1:** Showed Accessory lobe of right lung.



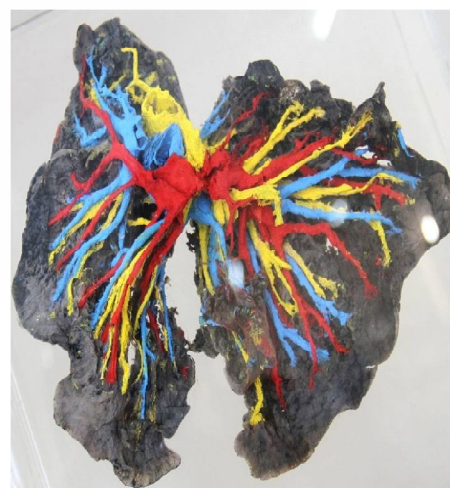AL – Accessory lobe, UL – Upper lobe, ML – Middle lobe and LL – Lower lobe

**Fig. 2:** Showed Accessory lobe between the Middle and the Lower lobe.



AL – Accessory lobe, ML – Middle lobe and LL – Lower lobe

**Fig. 3:** Showed no separate bronchus, pulmonary artery and pulmonary vein for Accessory lobe. Lower lobe bronchus, pulmonary artery and pulmonary vein were found in the Accessory lobe.



the right lung. The bronchus, branch of pulmonary artery and tributary of pulmonary vein of accessory lobe were found to originate from lower lobe branches and they were not found to be separate branches.

**Measurement of accessory lobe:** Length-9.5cm, Breadth from inside-5cm, Breadth from outside-5.5cm, Width from within-0.8cm

## DISCUSSION

H.P.Sharma, Manirul islam [3] reported an accessory middle lobe between a horizontal fissure and oblique fissure in the left lung which includes the cardiac notch and lingula.

Ashwini.H, Archana.M.hatti et al [4] reported Azygos lobe in the apex of right lung and that was found to be a lobe of Azygos vein of right lung.

Kosuri kalia chakravarthi [5] encountered an unusual variant lobar pattern of the left lung. The left lung was completely divided by a vertical fissure into anterior and posterior lobes with separate hilum. The anterior lobe of lung was divided into upper and lower lobes by an incomplete oblique fissure.

Gopal Sharma, Tarun vijayvergeya [6] found an accessory fissure in the left lung which divided the lung into three lobes.

N.Bhimai devi, B.Narasinga rao, V.Sunitha [7] encountered complete absence of transverse fissure in two right lungs and incomplete transverse fissure in four right lungs and incomplete transverse and oblique fissure were found in two right lungs and one supernumerary fissure was found in the left lung and incomplete oblique fissure was found in eight left lungs among twenty two cadavers (44 lungs).

S.Meenakshi, K.Y.Manjunath and V.Balasubramanyam [8] reported absent horizontal fissure of right lung about 16.6% and incomplete horizontal fissure of right lung about 63.3%. Incomplete oblique fissure of right lung was about 36.6%. Absent horizontal fissure and incomplete oblique fissure was about 6.66% and incomplete oblique fissure was about 46.6% among thirty pairs of lungs.

W.Sieber, N.Karcara, P.Pant [9] found a small accessory lobe on the right lung separated from the rest of upper lobe by a deep groove lodging

the Azygos vein. The presence of Azygos lobe was found during routine chest X-ray.

But in our study, we found an accessory lobe in the right lung between the middle and lower lobe with presence of four lobes in the right lung. This was not reported in any previous case studies. In the previous case studies, many authors reported Azygos lobe in the right lung, accessory fissure in the left lung which divided the left lung into three lobes and incomplete/absent oblique or horizontal fissures. There was no evidence of accessory lobe in the right lung.

## CONCLUSION

Anatomical knowledge of morphological variations of lobes and fissures are essential for Radiologists and Cardiothoracic surgeons. Hence the awareness of variations of lobes like accessory lobe and variations of fissures are important, for cardiothoracic surgeons in identifying bronchopulmonary segments and for performing lobectomies and surgical resection of individual segments and for Radiologists in diagnosing the radiological images.

**Conflicts of Interests: None**

## REFERENCES

- [1]. Standring S. Pleura, lungs, trachea and bronchi. In: Gray's Anatomy's Lungs. 40<sup>th</sup> ed. Edinburg, UK: Churchill Livingstone 2008:993
- [2]. A.K.Datta, Essentials of Human Anatomy, Part -1, 8<sup>th</sup> ed. 2008 : 39
- [3]. H.P.Sharma, Manirul islam, Accessory middle lobe in the left lung: a morphological variation, Sch. j Med Case Rep 2014;2(3):167-168.
- [4]. Ashwini H, Archana M Hatti, Jaishree H, Azygos lobe of right lung – a case report, I.J.Med. Case reports 2013;2(3):11 -13.
- [5]. Kosuri kalia chakravarthi, Unreported variant lobar pattern of left lung : A case report, IOSR J.Dental Med.Sci. 2012;1:31-33.
- [6]. Gopal Sharma, Tarun vijay vergiya, Anatomical variations in lobar pattern of lungs- Anatomical study and clinical significance, J.pharm Biomed Sci 2013 Jan;26(26):301-303
- [7]. N.Bhimai Devi, B.Narasinga rao, V.Sunitha, orphological variations of lungs-A cadaveric study in north coastal Andhra Pradesh, Int.J. Biol.Med.Res. 2011;2(4):1149 -1152.
- [8]. S.Meenakshi, K. Y. Manjunath, V. Balasubramanyam. Morphological variations of the lung fissures and lobes. I.J.Chest Dis.Allied Sci 2004;46:179-182
- [9]. W.Sieber, N.Karcara, Pankaj Pant. Pulmonary azygos lobe – An anatomical variant (2014), Kathmandu Univ.Med.J. 2014;46(2):151-152.