

Technique to minimize the incision length, in Minimally Invasive Dynamic Hip Screw procedure for the treatment of Intertrochanteric fractures of femur

Abhay Manchanda^{1,*}, Viral K. Patel², Satya N. Shukla³

^{1,3}Associate Professor, ²PG Resident, Dept. of Orthopaedics, Index Medical College, Indore, Madhya Pradesh

***Corresponding Author:**

Email: abhayortho@gmail.com

Abstract

Background: Fractures around the hip not only are very prevalent, but need more attention also, since the enhanced average life expectancy, the resultant elderly-osteoporotic-population pool has expanded, present orthopaedic surgeons are aflood with such cases^[1-4]. The intertrochanteric fractures comprise 50% of the fractures around the hip^[5]. Intertrochanteric fractures in the elderly are associated with high rates of mortality, ranging from 15 to 20%, as they are at a high risk for deep vein thrombosis (DVT), urinary tract infections, and pulmonary embolism when they fail to mobilize or ambulate early^[6]. Early mobilization is only possible when stable fixation is achieved with less post-operative pain and when patients become haemo-dynamically stable.

Aims & Objective:

1. Even though minimally invasive DHS surgery is popular since last decade, still we intended to develop a truly minimally invasive technique without the need of any special instrumentation.
2. To confirm whether the proposed minimum incision allows sound fixation, without damaging the corners of the skin incision.

Materials & Methods: This is a prospective study done over a period of 2 years at the Department of Orthopaedics at a Tertiary Care Centre. Patients presenting to the Department of Orthopaedics, Index Medical College with intertrochanteric fractures were evaluated and analysed to be included in the study. 54 patients, who presented with an intertrochanteric femur fracture and who fulfilled the inclusion criteria were enrolled in the study. Generally, for an AO 31 A1.1 and an A1.2 fracture, a two hole DHS plate is enough^[14], but when we are not sure of the quality of implants or sound purchase of the screws in cortex, we use four hole standard barrel side 135 degrees plate. It is inserted first beneath the muscle inside-surface-out, grasping the barrel then slid along the shaft and then again turned inside-surface-inside, manually.

Results:

1. The minimum incision required to perform Dynamic Hip Screw surgery is almost ONE INCH, roughly equal to the thickness of the plate.
2. The skin remains uninjured if the location of incision is proper. Out of 54 patients only in 8 patients we had to extend the incision due to initial learning curve, unstable fracture, to catch the bleeder.

Conclusion: Our study emphasised the need of locating the right entry point for the guidewire and the placing the incision slightly distal to it, since we intend to locate the incision from 2nd to 3rd screws. This enables the surgeon to manoeuvre instruments and implants through the '1-inch-incision'. '1-inch-incision' if properly placed doesn't lead to skin edge damage at incision site due to retraction.

Keywords: Minimally invasive, Dynamic hip screw, Inter-trochanteric fracture

Access this article online

Website:

www.innovativepublication.com

DOI:

10.5958/2395-1362.2016.00049.9

Introduction

Fractures around the hip not only are very prevalent, but need more attention also, since the enhanced average life expectancy, the resultant elderly-osteoporotic-population pool has expanded, present orthopaedic surgeons are aflood with such cases^[1-4]. The intertrochanteric fractures comprise 50% of the fractures around the hip^[5]. Intertrochanteric fractures in the elderly are associated with high rates of mortality, ranging from 15 to 20%, as they are at a high risk for deep vein thrombosis (DVT), urinary tract infections,

and pulmonary embolism if they fail to mobilize or ambulate early^[6]. Early mobilization is only possible when stable fixation is achieved with less post-operative pain and when patients become haemodynamically stable. Due to this, operative stabilization of these fractures is now the gold standard treatment. Although other options are available, the standard approach is to use a dynamic hip screw (DHS) with a 4-holed side plate in stable fractures in most centres.^[7-9] DHS was historically introduced in 1950s to replace the standard fixed nail plate^[4]. Traditionally a wide surgical exposure is necessary for this procedure which comes with its drawbacks like a large skin incision, considerable soft tissue trauma, significant blood loss, and pain. In the attempt to find less invasive techniques to simplify surgery and minimise complications by reducing surgical time and blood loss, some authors used custom made implants or new devices which require the purchase of additional

armamentarium by the hospital^[10-12]. The established incision length in literature is minimum 5 cm (13).

We hereby propose a surgical technique, to minimise the length of incision to 1 inch approx. equal to the width of the plate. We found the breadth of the plate to be the minimum length of the incision essential to manoeuvre the plate in place.

Materials and Method

This is a prospective study done over a period of 2 years at Department of Orthopaedics at a Tertiary Care Centre.

Inclusion criteria:

- 1- Inter-trochanteric femur fractures in skeletally mature patients
- 2- Fractures which can be reduced closely to highest acceptable standards

Exclusion criteria:

- 1- Compromised vascularity/integrity of skin at the incision site
- 2- Skeletally immature patients
- 3- Fractures which could not be reduced closely
- 4- Pathological fractures

Patients presenting to department of Orthopaedics, Index Medical College with intertrochanteric fractures were evaluated and analysed to be included in the study. 54 patients, who presented with an intertrochanteric femur fracture and who fulfilled the inclusion criteria were enrolled in the study. Patients' details were recorded in the standard format. Patients were worked up for surgery as per the standard protocol. All patients were operated under spinal anaesthesia, since better muscle relaxation is required, so essential for this technique.

After induction, patients were placed on fracture table. For closed reduction of the fracture, traction was applied to the limb & following traction to unlock the fragment, external rotation of the limb was done, under the C-ARM guidance correcting the varus/valgus/sterior sagging of the distal fragment adduction and internal rotation to lock the fragment in the acceptable reduction. Closed reduction was achieved to the best level of acceptance, confirming with a C-arm image intensifier. We accept perfect reduction on lateral view 160-180 degree neck shaft angle (Fig. 2) and 130-140 degree neck-shaft alignment on AP view (Fig. 1). Standard scrubbing, painting & draping is done.

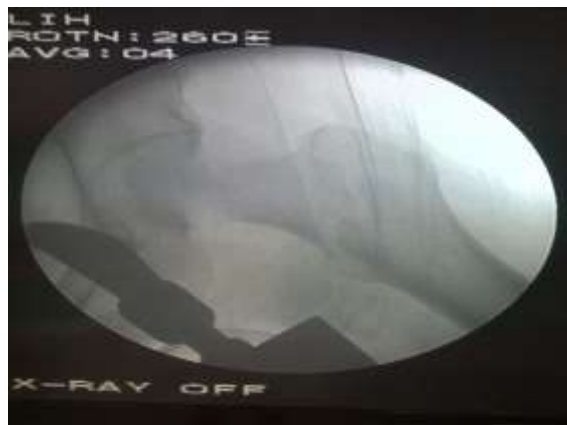

Fig. 1

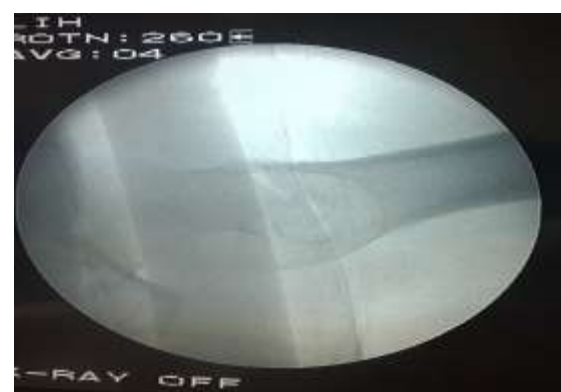

Fig. 2

Creating the entry point, at the right location is the most crucial step of the procedure (Fig. 3), since only a suitably located incision, allows insertion of the implant, without harmful retraction of the skin and soft tissues. A 135 degree 4hole barrel-plate is placed on the front of hip, along the shaft of femur and visualised under image intensifier to identify the proper location of entry point. The lateral surface skin is marked accordingly. We found, placing an inch long incision, from prospective 2nd to 3rd screws, equal to the breadth of the plate is the ideal location and the minimum size possible.

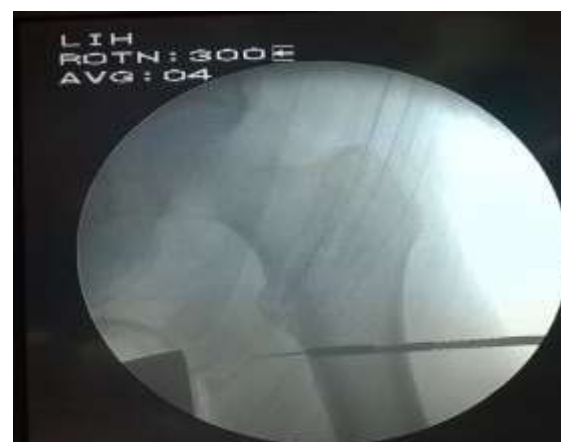

Fig. 3

The fascia and the iliotibial band are incised half an inch longer on either side, then vastus femoral lateralis muscle is incised preferably with cautery and separated. A guide wire is directly drilled at the selected entry point. The guide wire is targeted central or inferior (in the head and neck) in AP view, and central in lateral view.

Usual reaming is done over the guide wire, falling 5 to 10 mm short of articular surface. A lag screw of appropriate size is passed over the guide wire (Fig. 4). In osteopenic cases we avoid tapping. If the head rotates during screwing the lag screw, we drill a guide/k-wire, proximal to the incision through the skin, through the superior part of neck and head across acetabulum to prevent the rotation.

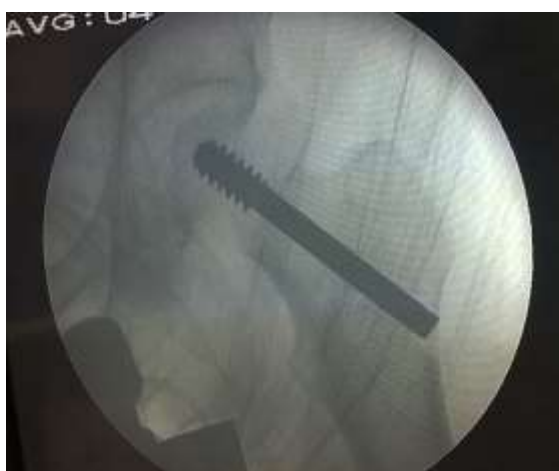

Fig. 4

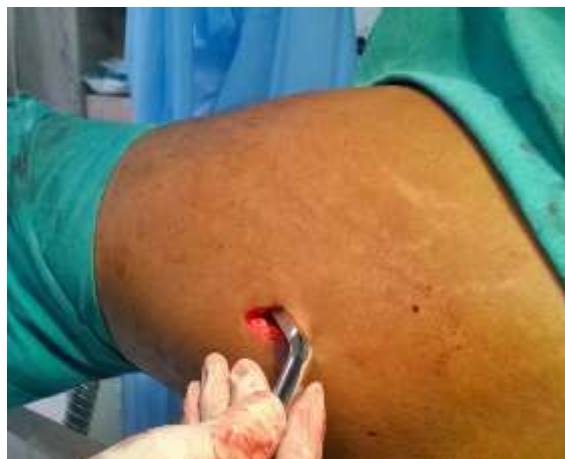

Fig. 5

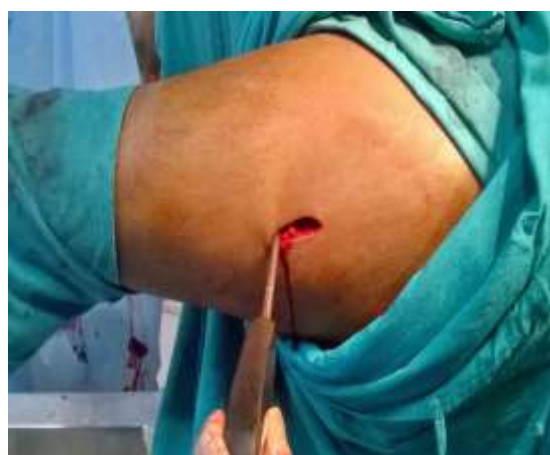

Fig. 6

Generally, for an AO 31 A1.1 and an A1.2 fracture, a two hole DHS plate is enough⁽¹⁴⁾, but when we are not sure of the quality of implants or sound purchase of the screws in cortex, we use four hole standard barrel side 135 degrees plate. It is inserted first beneath the muscle inside-surface-out (Fig. 5), grasping the barrel then slid along the shaft and then again turned inside-surface-in manually. The barrel plate is grasped over the lag screw blindly, viewing under image intensifier as required (Fig. 7). Precise insertion of the lag screw to match the barrel, is essential for blindly coupling the barrel over the lag screw. The plate is fixed with 4.5 mm cortical screw of appropriate size (Fig. 6,8,9).

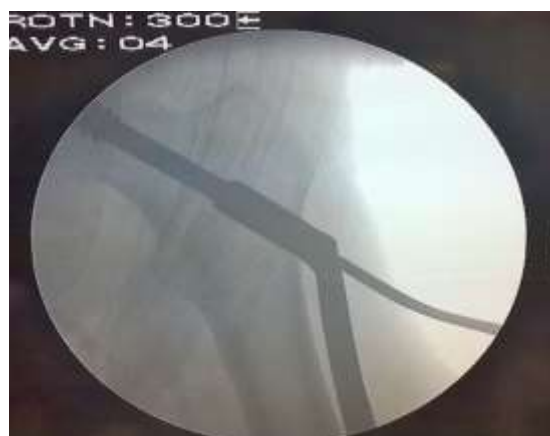

Fig. 7



Fig. 8

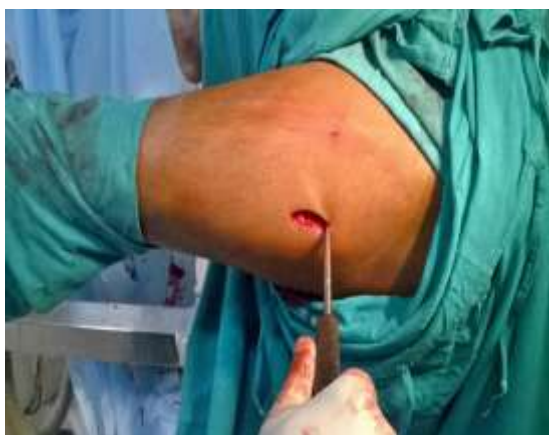

Fig. 9

We whenever, see the corners of the skin incision over-stretched, during retraction (to provide adequate room for instruments and implants) we, extend the incision as required. When the shape of the corners of the incision appears 'U' instead of 'V', it's a sign of overstretched skin.

The wound is sutured and dressed without a drain(Fig. 10).

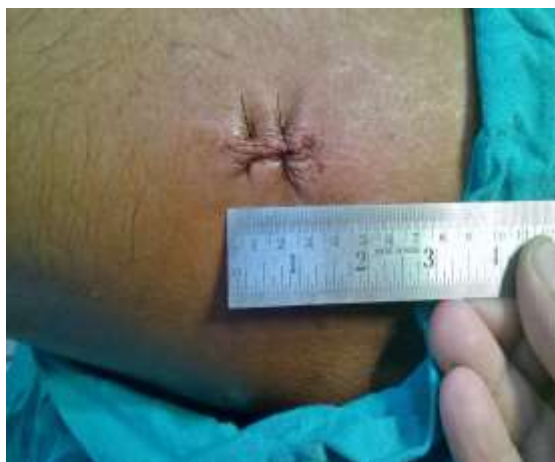

Fig. 10

Postoperative management is as per the standard protocol. The patients are followed up for a minimum period for 3 months. During follow up pain severity is assessed and time to ambulate is noted along, with the time to union and any complication.

Results

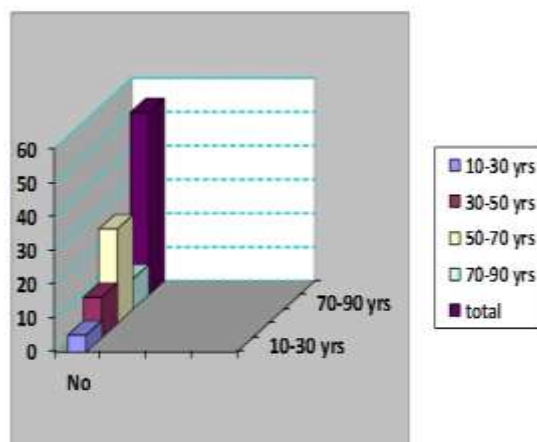
Numbers of patients: 54

Male: 38 males

Female: 16 females.

Most of the patients were between the age: 50-70 yrs⁽²⁸⁾

Minimum patients were between the age: 10-30 years⁽⁸⁾



In 08 cases we had to extend the incision an inch due to the following reasons:

- In 6 cases due to wrong anticipation of entry point, probably due to our initial learning curve
 - In 1 case we had to use a 5hole plate in place of 4, since we encountered a split in sub-trochanteric area, not visible in the pre-operative x-ray
 - In 1 case to locate the bleeder
- In 2 cases we had skin issues like cautery burn, though short lived.

All fractures healed in normal course.

Discussion

Minimally invasive dynamic hip screw technique is already prevalent, but the size of incision has never been the matter of study. We in this study attempted to discover the minimum length of incision required for conveniently performing Dynamic Hip Screw surgery, with comparable fixation as traditional incision.

Traditionally a wide surgical exposure is necessary for this procedure which comes with its drawbacks like a large skin incision, considerable soft tissue trauma, significant blood loss, and pain. In the attempt to find less invasive techniques to simplify surgery and minimise complications by reducing surgical time and blood loss, some authors used custom made implants or new devices which require the purchase of additional armamentarium by the hospital^[10-12]. The established

incision length in literature is minimum 5 cm^[13]. Compared to conventional incision minimally invasive technique has benefits like less soft tissue trauma, better soft tissue and fracture healing, less post-operative pain, less analgesics usage, early rehabilitation and better functional outcome.

Our study emphasised the need of locating the right entry point for the guidewire and the placing the incision slightly distal to it, since we intend to locate the incision from 2nd to 3rd screws. This enables the surgeon to manoeuvre instruments and implants through the one inch incision. A narrow and thin spike is adequate to retract all soft tissues superiorly and inferiorly, to clear lateral surface of upper shaft around the entry point.

As long as the corners of the incision are 'V' shaped, the viability of the adjoining skin is unchallenged. A 'U' shaped corner prompts us to extend the incision.

After an initial learning curve in identifying the right skin incision location, it is natural to be able to do so eventually.

Limitation of the study

Since due to very minimal exposure, its not possible to use angle guide to facilitate insertion of guidewire at desired angle. Hence previous experience of performing dynamic hip screw comes handy for this job.

Conclusion

A minimally invasive DHS technique offers the advantage of less dissection, less blood loss, less pain thus less use of analgesics. All these factors lead to lesser duration of hospital stay thus less economic burden to health system and better outlook for already morbid elderly patients in whom the majority of intertrochanteric fracture occur.

Our study concludes that an one-inch long incision, equal to the breadth of the plate, when rightly placed, is adequate, to perform DHS surgery.

Reference

1. A. K. Mishra, "Management of intertrochanteric fracture by using dynamic hip screw/dynamic martin screw," *Journal of Orthopaedics*, vol. 4, no. 2, article e40, 2007. View at Google Scholar.
2. D. G. LaVelle, "Fractures of hip," in *Campbell's Operative Orthopaedics*, vol. 1, pp. 28–75, Mosby, 2003. View at Google Scholar.
3. A. Alobaid, E. J. Harvey, G. M. Elder, P. Lander, P. Guy, and R. Reindl, "Minimally invasive dynamic hip screw. Prospective randomized trial of two techniques of insertion of a standard dynamic fixation device," *Journal of Orthopaedic Trauma*, vol. 18, no. 4, pp. 207–212, 2004. View at Publisher · View at Google Scholar. View at Scopus.
4. T.-C. Wong, Y. Chiu, W.-L. Tsang, W.-Y. Leung, and S.-H. Yeung, "A double-blind, prospective, randomised, controlled clinical trial of minimally invasive dynamic

- hip screw fixation of intertrochanteric fractures," *Injury*, vol. 40, no. 4, pp. 422–427, 2009. View at Publisher · View at Google Scholar · View at Scopus.
5. Baumgaertner MR, Curtin SL, Lindskog DM, Keggi JM. The value of the tip-apex distance in predicting failure of fixation of peritrochanteric fractures of the hip. *J Bone Joint Surg Am* 1995;77:1058-64.
6. R. Watson-Jones, *Fracture Treatment*, vol. 29, 7th edition, 2009.
7. B. R. Bolhofner, P. R. Russo, and B. Carmen, "Results of intertrochanteric femur fractures treated with a 135-degree sliding screw with a two-hole side plate," *Journal of Orthopaedic Trauma*, vol. 13, no. 1, pp. 5–8, 1999. View at Google Scholar.
8. Y.-S. Lee, H.-L. Huang, T.-Y. Lo, and C.-R. Huang, "Dynamic hip screw in the treatment of intertrochanteric fractures: a comparison of two fixation methods," *International Orthopaedics*, vol. 31, no. 5, pp. 683–688, 2007. View at Publisher · View at Google Scholar · View at Scopus.
9. A. R. Lyons, "Clinical outcomes and treatment of hip fractures," *American Journal of Medicine*, vol. 103, no. 2A, pp. 51S–63S, 1997. View at Google Scholar · View at Scopus.
10. Alobaid A, Harvey EJ, Elder GM, Lander P, Guy P, Reindl R. Minimally invasive dynamic hip screw: prospective randomized trial of two techniques of insertion of a standard dynamic fixation device. *J Orthop Trauma*. 2004;18:207–212. doi: 10.1097/00005131-200404000-00003. [PubMed] [Cross Ref]
11. Brandt SE, Lefever S, Janzing HM, Broos PL, Pilot P, Houben BJ. Percutaneous compression plating (PCCP) versus the dynamic hip screw for peritrochanteric hip fractures: preliminary results. *Injury*. 2002;33:413–418. doi: 10.1016/S0020-1383(02)00080-3. [PubMed] [Cross Ref]
12. Ingman AM. Percutaneous intramedullary fixation of trochanteric fractures of the femur. Clinical trial of a new hip nail. *Injury*. 2000;31:483–487. doi: 10.1016/S0020-1383(00)00027-9. [PubMed] [Cross Ref]
13. Comparison between conventional and minimally invasive DHS Michael Ho,¹ Giorgio Garau,² Gayle Walley,¹ Francesco Oliva,³ Alfredo Schiavone Panni,⁴ Umile Giuseppe Longo,⁵ and Nicola Maffulli.
14. AO Surgery Reference AO Foundation AO Surgery Reference, Executive Editor: Joseph Schatzker, Peter Trafton, Authors: Ernst Raaymakers, Inger Schipper, Rogier Simmermacher, Chris van der Werken.