

## Evaluation of Hybrid External Fixator for Tibial Plateau Fractures: A Prospective Study

Yashavantha Kumar C<sup>1</sup>, Shivaprasad MS<sup>2,\*</sup>, Ravikumar TV<sup>3</sup>, Suraj HP<sup>4</sup>

<sup>1,3</sup>Assistant Professor, <sup>2</sup>Associate Professor, <sup>4</sup>Junior Resident, Dept. of Orthopaedics, MSR Medical College, Bangalore

**\*Corresponding Author:**

Email: kumyashwanth@gmail.com

### Abstract

**Background:** Tibial plateau fracture is one of the common injuries encountered in our daily clinical practice. The goals of management of these peri-articular fractures are restoration of joint congruity by anatomic reduction of the articular fragments, stable fixation of fragments, early joint movements, care of injured soft tissues and prevention of fracture related, surrounding soft tissue and wound related complications. Though open reduction and internal fixation is preferred in the current day practice for such fractures, they are associated with a variety of complications leading to poor outcome. Ligamentotaxis and percutaneous fixation has been advocated by many authors to improve the results and to minimize the risk of serious complications. The aim of the present study is to evaluate and assess the results of closed reduction and hybrid external fixator application in the management of tibial plateau fractures.

**Materials and methods:** Study included 28 patients with Schatzker type II and above closed tibial plateau fractures treated by Hybrid external fixator by the same team of surgeons on a tertiary care center following relevant investigations and assessment. Patients were followed up at regular intervals and finally evaluated clinically and radiologically at the end of one year.

**Conclusion:** Our study highlighted the success of indirect reduction and hybrid external fixation application as the definitive method for the management of tibial plateau fractures. It minimizes the risk of soft tissue damage and reduces the incidence of serious complications with good fracture union and functional outcome in patients.

**Keywords:** Hybrid external fixator, Tibial plateau fracture, Schatzker.

### Access this article online

**Website:**

[www.innovativepublication.com](http://www.innovativepublication.com)

**DOI:**

10.5958/2395-1362.2016.00047.5

### Introduction

Tibial plateau fractures are one of the common injuries encountered in our daily clinical practice. The mechanism of injury involves an initial axial load combined with an angular force causing significant stress at the tibial condyles, not only causing comminution of the tibial plateau but also the metaphysis<sup>[1]</sup>.

According to Schatzker's classification tibial plateau fractures are divided into six groups, out of which type V (fractures involving both condyles) and type VI (fracture line crossing the metaphysis) are the most challenging to treat because of the osseous damage<sup>[2]</sup>. The other types are also difficult to treat considering the amount of significant soft tissue damage associated with the fracture and other associated injuries. Providing good fixation and results is of paramount importance in patients with these fractures because of the articular involvement. Inadequate reduction and fixation leads to limited range of movements and difficulty in performing routine activities of daily living.

The goals of management of these peri-articular fractures are restoration of joint congruity by anatomic reduction of the articular fragments, stable fixation of fragments, early joint movements, care of injured soft tissues and prevention of complications. Most data indicate that external fixation is equally as effective as or more than any form of internal fixation.<sup>[4-5]</sup>

The aim of the present study is to evaluate and assess the results of closed reduction and hybrid external fixator application in the management of tibial plateau fractures.

### Materials and Methods

This study was undertaken in patients who were operated in between January 2012 to March 2014 at M S Ramaiah Teaching Hospital, which is a tertiary care hospital in Bangalore. Study included 28 patients with Schatzker type II and above tibial plateau fractures treated by Hybrid external fixator. All 28 patients were treated in M S Ramaiah teaching hospital by surgeons of the same unit.

### Inclusion Criteria

1. Age more than 25years
2. Both males and females
3. Closed tibial plateau fractures (Schatzker type II and above) treated by hybrid external fixator

### Exclusion Criteria

- 1 Associated ipsilateral femur fractures or distal tibia fractures or significant ligamentous injury around the knee
- 2 Pathological fractures of tibia
- 3 Patients lost for follow up

Following admission all the patients underwent thorough clinical examination. Following diagnosis of the fracture detailed radiographic assessment, pre-operative planning and templating was done for all cases. CT scan with 3D reconstruction was done for most of the patients, especially for fractures with high energy trauma for better understanding of fracture geometry. Patient was taken up for the procedure following detailed written and informed consent following pre anaesthetic check up.

Out of the 28 patients, 19 were males and 9 were females with a mean age of 38 (range, 26- 64years). Twenty patients sustained injury in road traffic accidents (12 were bike accidents, 2 car accidents, 6 pedestrians struck by vehicles), 6 fell from height, 2 patients sustained injury due to fall of heavy object on the leg. With respect to fracture type there were 3 Schatzker type II fractures, 2 type-III, 4 type-IV, 11 type-V and 8 type-VI fractures. All patients had closed fractures and soft tissue condition was graded by Tscherne classification. Five patients had Tscherne type C0 injury, 7 patients with C1, 10 patients with C2 and 6 patients with Tscherne type C3 soft tissue injury. The time period between the trauma and the surgery varied from 6hrs to 8days with an average of 3 days. All the patients were operated by the same team of surgeons. Majority of cases were operated under regional anaesthesia (23 patients) and some under general anaesthesia (5 patients). Preoperative antibiotics were administered about 30minutes prior to surgery in all patients, however intravenous antibiotics as per hospital protocol was started in all patient with Tscherne type C3 injuries.

All the patients were put on fracture table except few where elevation of the depressed fragment and bone grafting was necessary. On fracture table indirect reduction was achieved by ligamentotaxis and confirmed on fluoroscopy. By maintaining reduction Ilizarov wires were passed into the tibial plateau and hybrid external fixator was applied. Twenty three patients were operated by closed reduction, 5 patients needed bone grafting for the collapsed tibial plateau which was managed by elevation using a limited opening of the fracture site. Autogenous bone graft was used for 3 patients, harvested from the ipsilateral iliac crest and fresh frozen allogeneous bone graft from a tissue bank was used for 2 patients.

Partial weight bearing was started in most of the patients and knee range of motion exercises in all patients was started by the third post operative day and gradually progressed to full weight bearing following

radiological evidence of callus formation by around 3weeks.

Patients were followed up at regular intervals and with each visit clinical, radiological and functional evaluation of these patients were done.

### Results

The observations and the results of the study are shown in tables and graphs as follows:

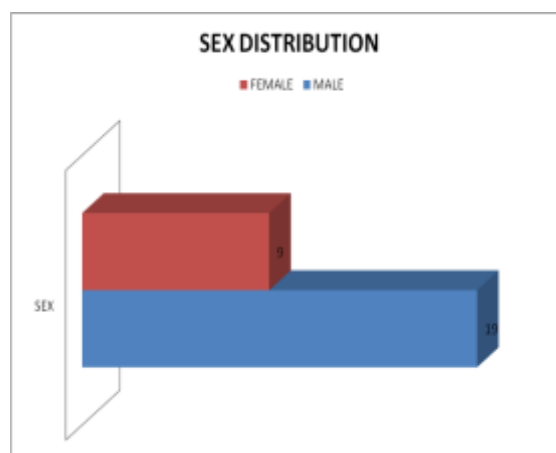


Fig. 1: Sex distribution of patients

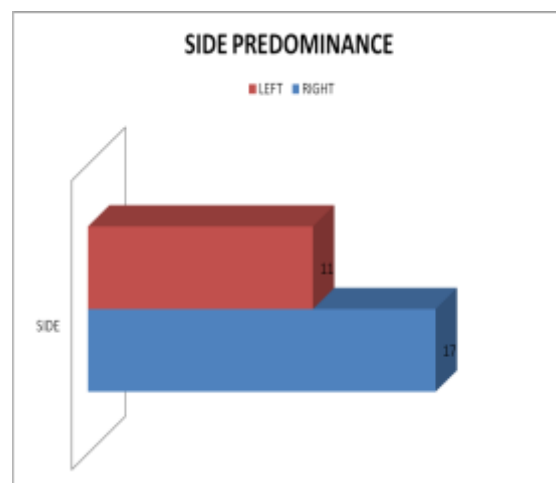


Fig. 2: Side predominance

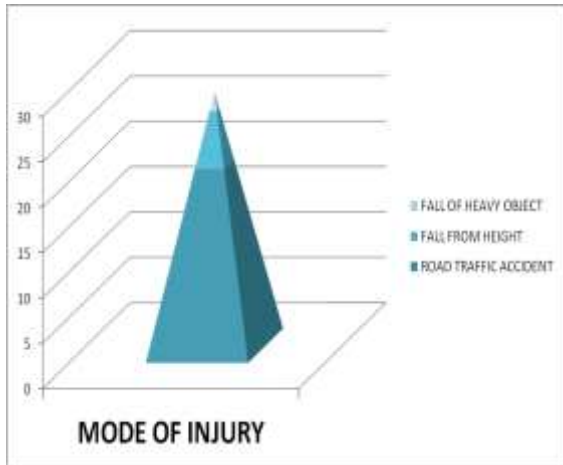


Fig. 3: Mode of injury

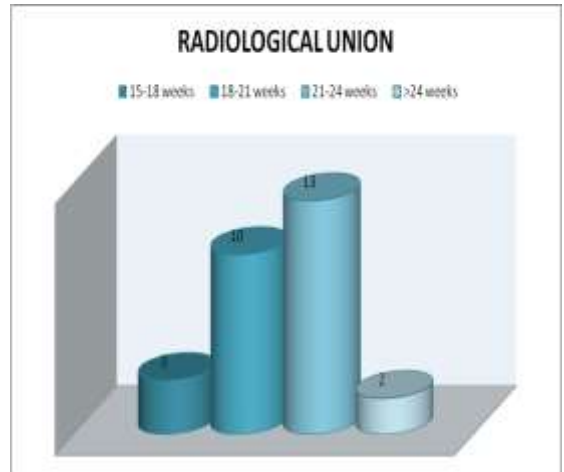


Fig. 6: Time of radiological union of fracture

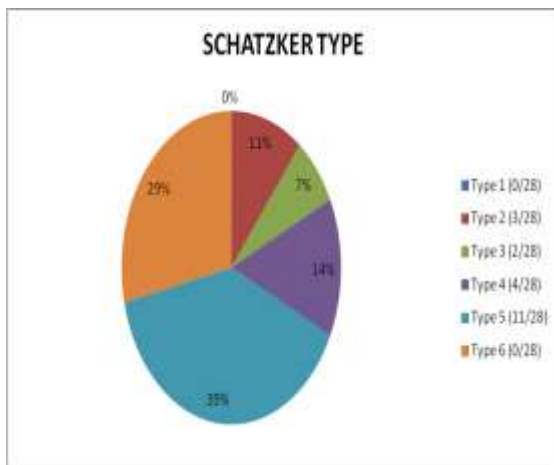


Fig. 4: Schatzker type of fracture

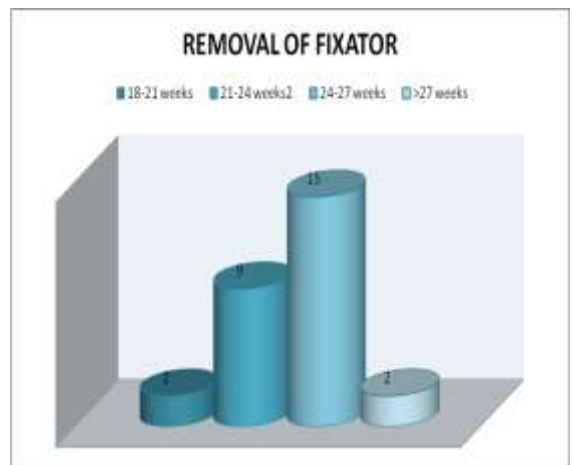


Fig. 7: Time of removal of hybrid fixator

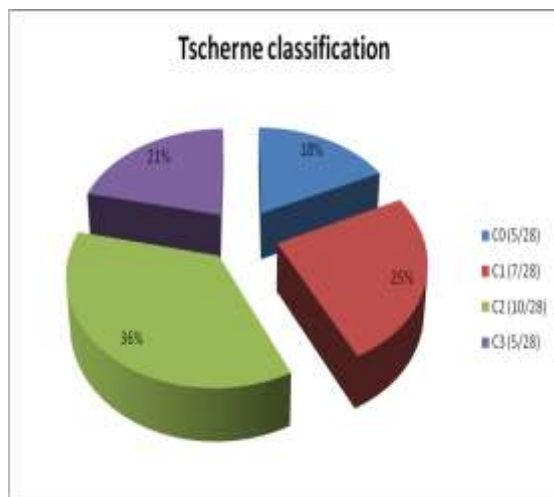


Fig. 5: Tscherne classification of soft tissue injury

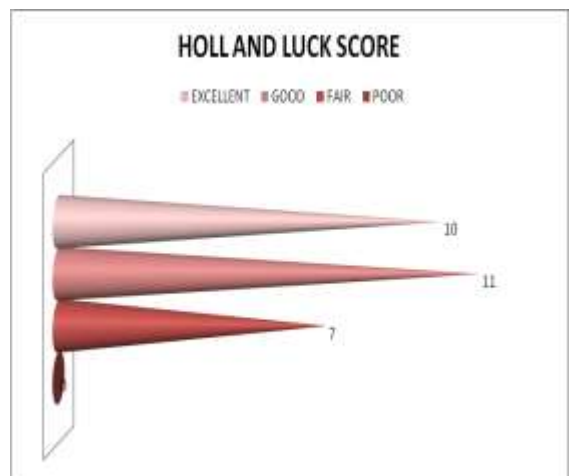


Fig. 8: Holl and Luck score

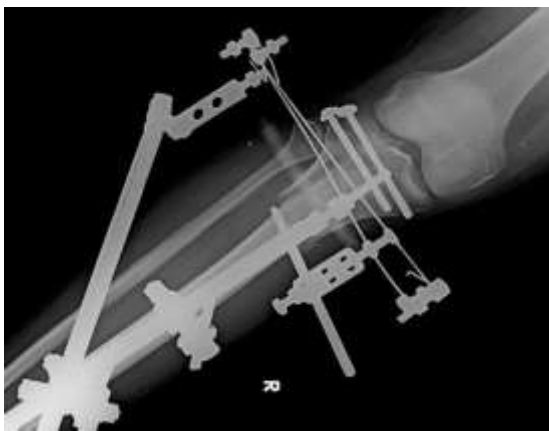
All fractures united by a mean duration of 21.3weeks (range 17.6-36.4). Two patients had delayed union for which bone marrow infiltration was done and united subsequently. Fixator was kept for about 3weeks following union, mean fixator period was 24weeks (range 20.3- 39.5). Following removal of fixator all

patients were allowed full weight bearing, some with PTB brace and some without the brace.

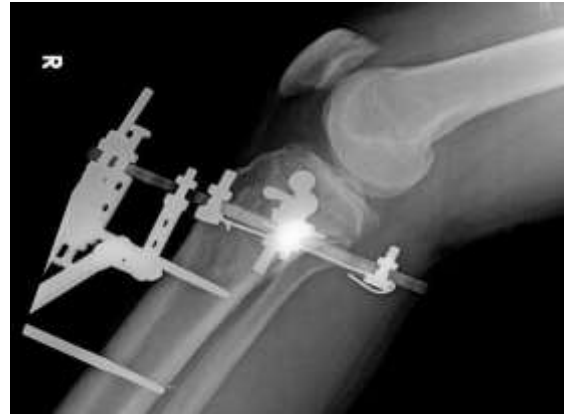On clinical examination by the end of one year 21 patients had knee flexion beyond 120 degrees, 4 patients up to 120 degrees and 3 patients had knee flexion up to 90 degrees. Six patients had extensor lag, 2 patients more than 20degrees and 4 patients less than 20 degrees. Two patients had fixed flexion deformity of the ipsilateral knee which was less than 20degrees. One patient was found to have significant thigh muscle atrophy and 2 patients with significant atrophy of calf muscles. No patients had signs of significant ligamentous laxity by the end of one year. The functional results were measured by Lyshom's and Hohl and Luck score. At the end of one year, mean Lyshom's score 84.40 and as per Hohl and Luck grading no patients had poor score, 7 patients had fair, 11 had good and 10 had excellent results.

Four patients had pin tract infections which resolved with appropriate antibiotics and regular dressing and pin tract care, however one patient needed change of wire. Two patients were diagnosed with impending compartment syndrome for which fasciotomies were done and no further complications were noted following surgery. Varus malunion (tilt less than 10degrees) was seen in 3 patients, which did not cause significant functional problems.

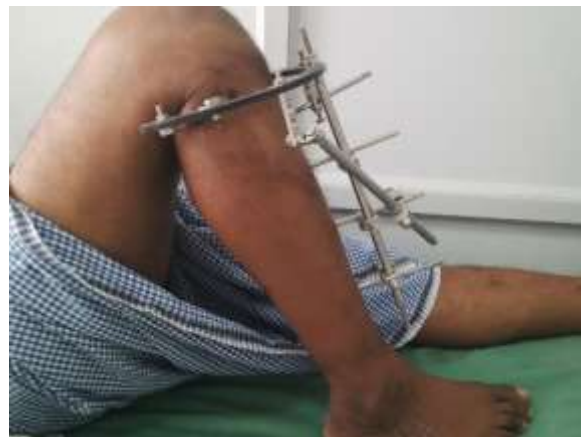We did not encounter any significant intra operative complication like neurovascular damage. No patient had signs of septic arthritis, osteomyelitis, cellulitis, deep vein thrombosis or pulmonary embolism.



**Fig. 9: United tibial plateau fracture anteroposterior view with hybrid fixator in situ**



**Fig. 10: United tibial plateau fracture lateral view with hybrid fixator in situ**



**Fig. 11: Clinical photo with fixator in situ**

## Discussion

Management of tibial plateau fractures especially high energy injuries is a challenging task considering the fracture type and the associated soft tissue injuries. About 1/3rd of Schatzker type-IV, type-V, and type-VI fractures are associated with an open injury and 2/3rd of the remaining types are associated with significant closed soft tissue injury.

Many treatment modalities have been advocated for the treatment of such fractures from conservative POP cast application to technically demanding procedures. Though open reduction and internal fixation is preferred in the current day practice for such fractures, they are associated with a variety of complications leading to poor outcome<sup>[6]</sup>. Ligamentotaxis and percutaneous fixation has been advocated by many authors to improve the results and to minimise the risk of serious complications<sup>[7-8]</sup>.

The presence of fracture blisters or extensive subcutaneous haemorrhage and bruising does not hinder percutaneous placement of the wires and Hybrid external fixator prevents further soft tissue destruction, devitalisation of the bone. The construct of the frame allows adequate reduction and maintenance of

alignment and patient can be started with immediate range of movement exercises and early weight bearing.

Supervised physiotherapy is essential to achieve good range of movements, the value of which is well established<sup>[9-10]</sup>. Early weight bearing leads to improved bone healing and preservation of muscle strength, however premature weight bearing can lead to varus or valgus mal-alignment or even collapse of the articular surface<sup>[11-12]</sup>.

On reviewing literature many studies show good results for tibial plateau fractures treated by similar constructs of hybrid ring fixators and avoids potential complications of open reduction and plate osteosynthesis like infection and non-union.<sup>[13-16]</sup>

### Conclusion

Our study highlights the success of indirect reduction and hybrid external fixation application as the definitive method for the management of tibial plateau fractures. It minimises the risk of soft tissue damage and avoids serious complications of internal fixation. Fracture union rates and functional outcomes are better in patients with high velocity injuries.

### References

1. Eggli S, Hartel MJ, MD S, Haupt U, Exadaktylos AK, Roder C: Unstable Bicondylar Tibial Plateau Fractures: A Clinical Investigation. *J Orthop Trauma* 2008;22(10):673-679.
2. Schatzker J, McBroom R, Bruce D: The tibial plateau fracture: The Toronto experience (1968-1975). *Clin Orthop Relat Res* 1979(138):94-104.
3. Moore TM, Patzakis MJ, Harvey JP. Tibial plateau fractures: Definition, demographics, treatment rationale and long term results of closed traction management or operative reduction. *J Orthop Trauma* 1987(2):97-119.
4. Hohl M, Luck V. Fractures of the tibial condyle. *Journal of Bone Joint Surgery Am* 1956;38(7):1001-1018.
5. Oestern HJ, Tschern H: Pathophysiology and classification of soft tissue injuries associated with fractures, in Tschern H, Gotzen L [eds]: *Fractures With Soft Tissue Injuries* [German]. Telger TC [trans]. Berlin, Germany: Springer-Verlag, 1984, pp 6-7.
6. Young MJ, Barrack RL. Complications of internal fixation of tibial plateau fractures. *Orthop Rev* 1994;23(2):149-154.
7. Kataria H, Sharma N, Kanojia RK. Small wire external fixation for high-energy tibial plateau fractures. *J Orthop Surg* 2007;15(2):137-143.
8. Piper KJ, Won HY, Ellis AM. Hybrid external fixation in complex tibial plateau and plafond fractures: An Australian audit of outcomes. *Injury* 2005;36(1):178-184.
9. Apley AG. Fractures of the lateral tibial condyle treated by skeletal traction and early mobilisation: A review of sixty cases with special reference to the long-term results. *J Bone Joint Surg Br* 1956;38-B(3):699-708.
10. Gausewitz S, Hohl M. The significance of early motion in the treatment of tibial plateau fractures. *Clin Orthop Relat Res* 1986(202):135-8.
11. Scotland T, Wardlaw D. The use of cast-bracing as treatment for fractures of the tibial plateau. *J Bone Joint Surg Br* 1981;63B(4):575-8.
12. Segal D, Mallik AR, Wetzler MJ, Franchi AV, Whitelaw GP. Early weight bearing of lateral tibial plateau fractures. *Clin Orthop Relat Res* 1993;(294)232-7.
13. Hisam M A, Nidzwani M M, Shaharuddin A R, Azmi B and Mohamad H S: Modified hybrid fixator for high-energy Schatzker V and VI tibial plateau fractures. *Strat Traum Limb Recon*;2011;(6):21-26.
14. George C B, Dimitrios S E, Panagiotis K, Konstantinos N and Panagiotis N: High energy tibial plateau fractures treated with hybrid external fixation. *Journal of Orthopaedic Surgery and Research* 2011,6(1):35.
15. Berkson EM, Virkus WW: High-energy tibial plateau fractures. *J Am Acad Orthop Surg*. 2006;14(1):20-31.
16. Kye-Yeol Cho, Hyun-Sup Oh, Jae-Ho Yoo, Duk-Hyun Kim, Young-Joo Cho, Kang-II Kim et al: Treatment of Schatzker Type V and VI Tibial Plateau Fractures Using a Midline Longitudinal Incision and Dual Plating. *Knee Surg Relat Res*. 2013;25(2):77-83.