

## **STREPTOZOTOCIN INDUCED HYPOINSULINEMIA ON STRUCTURAL ASPECTS OF THYROID GLAND IN DWARF GOAT**

ABDUL MAJEED CHEEMA, SADYA JAVAID AND RUBINA MUSHTAQ

*Department of Zoology, University of the Punjab, Quaid-e-Azam Campus, Lahore-54590, Pakistan*

**Abstract:** A successful hypoinsulinemia (experimental diabetes type 1) was induced with two consecutive doses of 33mg/kg body weight and 40mg/kg body weight streptozotocin (STZ), at the gap of four days, in male dwarf goats. Marked hyperglycemia >250mg/dl (average increase of 278%,  $P < 0.001$ ) and significant glycosuria up to 1.7 to 7 g/dl confirmed the induction of the syndrome. The hypoinsulinemic and control goats were maintained for 14 weeks before slaughtered for obtaining tissues. Marked effects on the morphology of the hypoinsulinemic compare to the control goats have been observed. Increased follicular size with fewer interfollicular stroma and excessively flattened follicular epithelium with the evident indications of inactive state of the gland are the characteristic of the thyroid in insulin insufficiency. The weight of thyroid did not exhibit a noticeable variation in the comparable groups, however, average follicular epithelial height was measured at  $7.26 \pm 0.09 \mu\text{m}$  and  $4.22 \pm 0.10 \mu\text{m}$  in the control and hypoinsulinemic goats respectively. Calcitonin cells remained unaffected in hypoinsulinemia.

**Key words:** Goat, diabetes, thyroid.

### **INTRODUCTION**

Interrelationships between endocrine glands maintain the crucial role of physiological homeostasis. Almost four decades ago endocrine pancreas-thyroid interaction received preliminary attention. Since then numerous studies have been reported to show sub-normal thyroid function in experimentally induced diabetes mellitus (Serif and Sihotang, 1962; Kumareson and Turner, 1966; Cheema and Matty, 1972; Zaninovich et al., 1977 and Jolin and Gonzalez, 1978). Similarly in clinical observations reduced thyroid function in diabetes (Zaripova, 1970; Inada, 1973; Saunders et al., 1978; Solar and Nicholson, 1979 and Gray et al., 1980) and stimulated thyroid activity following insulin administration (Blum 1973) have been observed. Induced diabetes creating hypoinsulinemia have been employed also in ruminants to see the effects of insulin deprivation on various physiological targets such as metabolites in pregnant and lactating ewe (Leenanuruksa and McDowell, 1988; Lips et al., 1988 and Miodovnik et al., 1989). However, a study in such induced state on thyroid function in ruminants has not appeared.

The role of insulin in ruminants is very intriguing as these exhibit insulin resistance. This is an adaptation, in ruminants to manage the poor availability of glucose directly

from gastrointestinal tract (GIT) and to promote gluconeogenesis in liver and kidney (Brockman, 1990; Wastney *et al.*, 1983)). Thus the role of insulin in endocrine pancreas-thyroid interaction, in ruminants, may be expected deviated from non ruminants. Thus the present study is performed to investigate endocrine pancreas and thyroid interaction in goat model of the ruminants to compare with reported effects of these axis in non ruminants.

## MATERIALS AND METHODS

A group of adult four male dwarf goats tagged as 16, 17, 19 and 20 were shifted from Farm house to animal house for experimentation and round the clock care. Similarly another batch of 4 male goats numbered as 36, 37, 38 and 39 were kept as control group. The goats were confined to the animal house and were provided with green fodder and concentrate dry ration. An injection of streptozotocin (Sigma Chemical Company, USA) was prepared at a concentration of 33mg/ml in sterile saline citric acid buffer of pH 4.3 and administered to the experimental goats in a dose of 33mg/kg body weight. Subsequently the goats were monitored for glycemia and glycosuria. Goats were not rendered diabetic with this dose, therefore administered with another dose of 40mg/dl 4 days after the first injection. The goats developed significant hyperglycemia, three days after the second injection goats were suffering with severe hyperglycemia and glycosuria. The goats were maintained for 14 weeks. The control goats were also maintained in the similar conditions of diet and housing condition and sham injections of sterile isotonic saline were given on the same pattern as for experimental goats.

Following slaughtering tracheal tube was excised carefully and thyroid lobes along the isthmus were separated. The gland of each goat was weighed and of two goats from each batch of experimental and controls was fixed in Bouin's fixative. The tissues were dehydrated in grades of ethyl alcohol, cleared in cedar wood oil and the oil was removed with xylene. Tissues were ultimately fixed in high grade paraffin wax for serial sections on a rotary microtome at a thickness of 6 $\mu$ . Tissues were fixed on glass slides and stained with Ehrlich's haematoxylin and eosine as prepared by Drury *et al.* (1973). Tissues were studied under the light microscope at various magnifications for histological and histometric observations.

## RESULTS AND OBSERVATIONS

### *General*

The surface of the gland in control goats was smooth in contrast to uneven surface with tiny out bulgings form the glandular surface in the hypoinsulinemic goats. The mean weight of the gland was  $1.676 \pm 0.101$ g in the diabetic and  $1.800 \pm 0.083$ g in the control goats. The weight of the gland did not show any noticeable difference in both the comparable groups (Fig.1).

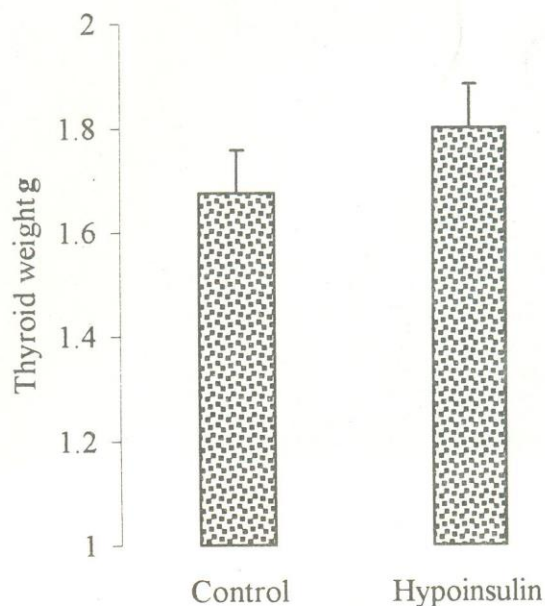


Fig. 1: Thyroid weight in intact and induced hypoinsulinemic goats.

#### *Histological study*

The follicles with sufficient interfollicular stroma clearly represent the picture of thyroid in intact goats. The follicles of varying size and shapes are observed. There is a trend of distribution of larger size follicles on the periphery and smaller size follicles towards the center of the glandular geography. Colloid in the follicles fills, adequately, intrafollicular space with striations and spaces in between hence clearly explicating optimum or moderate secretory capacity of the gland (Fig. 2)

In diabetic goats the substance of the gland is occupied by follicular spaces. The follicles of the glands are randomly distributed with out any specific pattern. Colloid is significantly reduced in the follicular cavity, as there is large space between follicular epithelial and colloidal boundaries. The epithelium of the follicles is comparatively flattened and appears that fewer interfollicular stroma is the result of enlarged follicles (Fig.3).

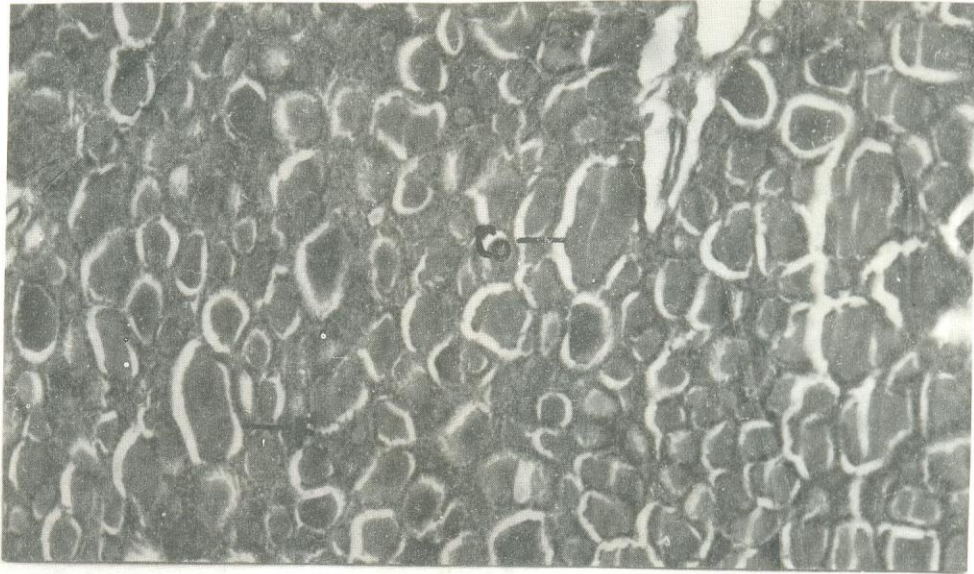


Fig. 2: Low power photomicrograph (x100) of a portion of thyroid gland in intact goat. F, Follicles; Co, Colloid.

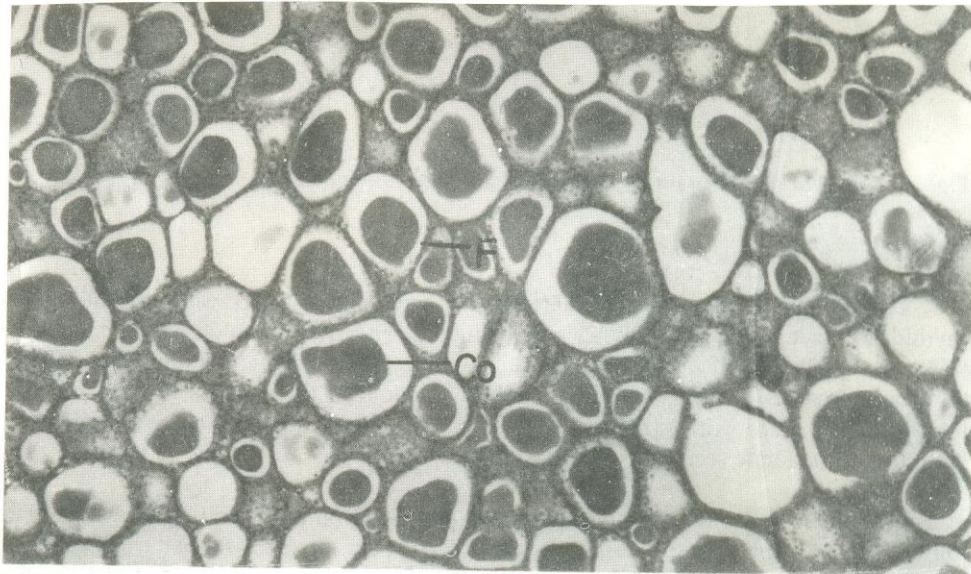


Fig. 3: Low power photomicrograph (x100) of a portion of thyroid gland in hypoinsulinemic goat. F, Follicles; Co, Colloid.

In the control goats, follicular epithelium is cuboidal, with nucleus occupying the central position in the epithelial cells. The microvillous extension form the inner membrane of the epithelium and intrafollicular droplets are clearly demonstrated (Figs 4 and 5). The general status of the gland is evidently in healthy secretory phase with replenishing synthesizing capacity.

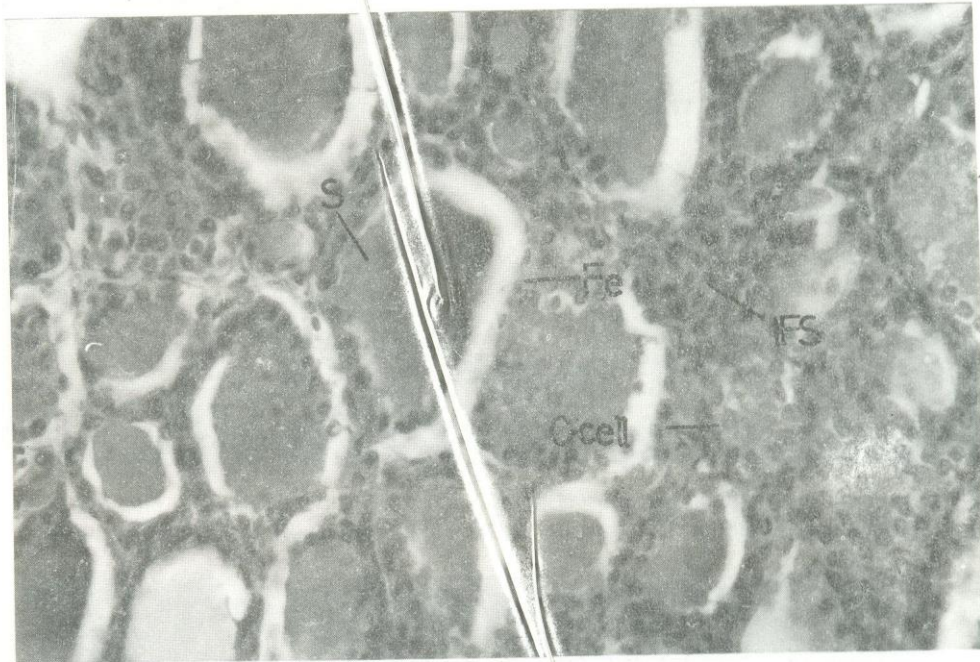


Fig. 4: High power photomicrograph (x400) of a portion of thyroid gland in intact goat. Fe, Follicular epithelium; ICD, Intrafollicular colloid droplets; C Cell, Calcitonin cells.

In diabetic goats, in contrast, has conspicuous flattened follicular epithelium and their nuclei are squeezed in the cellular membranes facing basement membrane and the follicular cavity. In the most of the follicles microvillous extension are absent or sparsely present in some. Similarly intrafollicular droplets are few. These observations demonstrate reduced synthetic ability in the gland (Figs. 6 and 7). Also the secretory capacity with reduced replenishing synthetic activity had depleted the amount of colloid in the follicular substance. Calcitonin cells did not exhibit any noticeable difference in the comparable groups.

#### *Morphometric study*

The average follicular epithelial height in the control goats was determined at  $7.26 \pm 0.09 \mu\text{m}$  and  $4.22 \pm 0.10 \mu\text{m}$  in the control and hypoinsulinemic goats respectively.

The follicular height was 72% ( $P < 0.001$ ) lower in hypoinsulinemic mic compare to the control goats (Fig. 8).

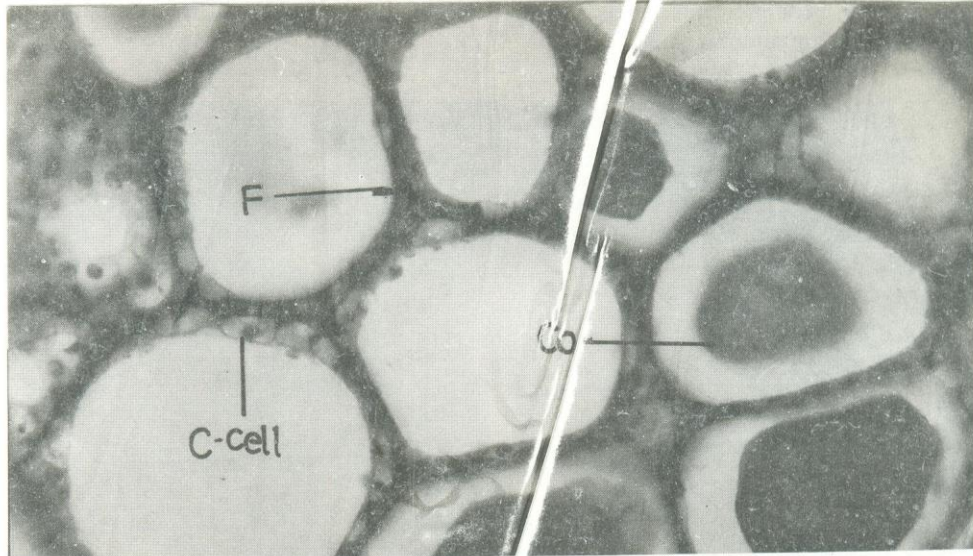


Fig. 5: High power photomicrograph (x100) of a portion of thyroid gland in intact goat. Fe, Follicular epithelium; ICD, Intrafollicular colloid droplets; C Cell, Calcitonin cells.

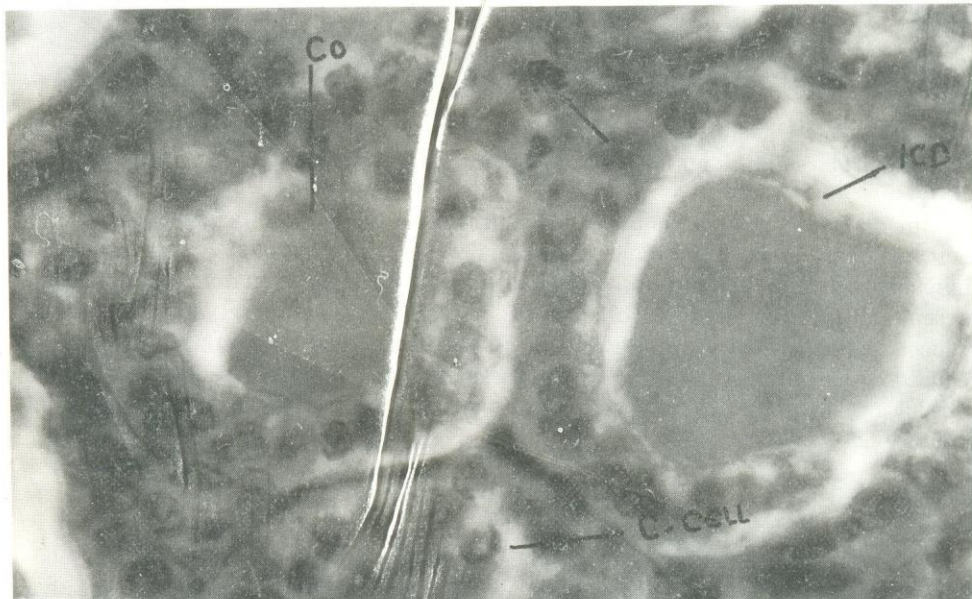


Fig. 6: High power photomicrograph (x400) of a portion of thyroid gland in hypoinsulinemic goat. F, Follicles; Co, Colloid; C Cell, Calcitonin cells.

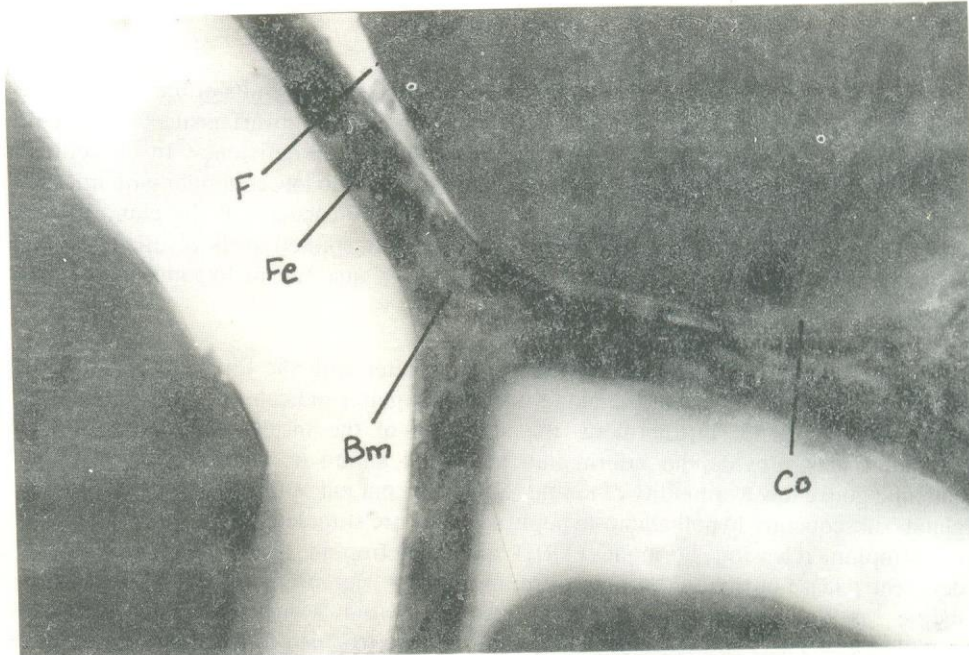


Fig. 7: High power photomicrograph (x100) of a portion of thyroid gland in hypoinsulinemic goat. F, Follicles; Fe, Follicular epithelium; C, Colloid; Bm, Basement membrane.

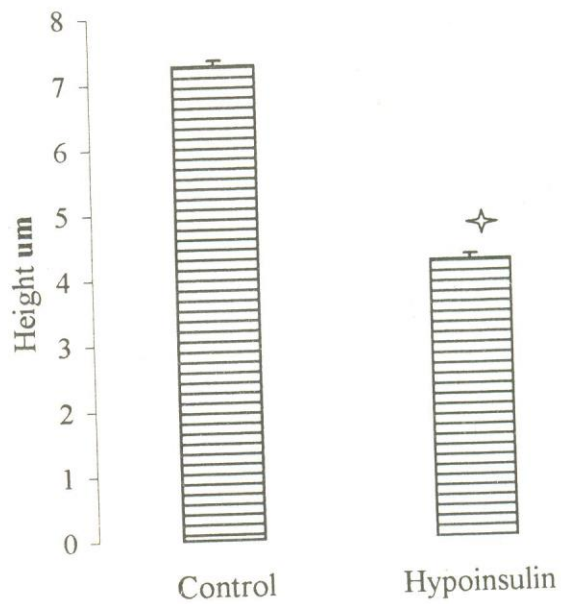


Fig. 8: Follicular epithelial height in intact and induced hypoinsulinemic goats. \* $P < 0.0001$ .

## DISCUSSION

Induced hypoinsulinemia, as clearly demonstrated in the results of the present study, markedly affects functional aspects of thyroid gland in the dwarf goat. The structural alterations in the gland are the manifestation of the insulin deficiency. In the follicular picture of the glandular histology, epithelium is squamous to low columnar with microvilli and intracoloidal droplets exhibiting efficient secretory capacity of the gland in intact goats. In contrast in hypoinsulinemic goats, follicular epithelium is distinctly low and cuboidal. The amount of colloid is also in decreased quantity in hypoinsulinemic goat compare to the control goats.

Morphology and histology of thyroid gland alter with the functional status of the gland. Hence enlargement of the gland in endemic goiter indicates the failing functional ability of the gland. Furthermore, the attributes of the histological and histometric alteration may provide the information about the nature of thyroid clinical state. In endemic goitre low availability of iodine reduces the out put of thyroid hormones from the gland, subsequently hypothalamo-hypophyseal axis are stimulated to enhance secretion of thyrotrophin releasing hormone (TRH) and thyrotrophin (TSH) to compensate the deficient release of thyroid hormones from the gland. Because of very low availability of iodine, as the precursor in the synthesis of thyroid hormones, the compensatory stimulation persists and follicular epithelium is hypertrophied to increase the size of the gland (Medeiros-Neto, 1989 and Greenspan, 1997). In experimental hypophysectomy in rats, follicular cells are flattened and lamina are distended by colloid (Halmi, 1978). Low cuboidal follicular epithelium is the characteristic of hypoactive follicles and consequently reduced functional capacity of the gland. (Ekholm, 1989).

The alteration of follicular epithelium, following induction of hypoinsulinemia, to low cuboidal clearly demonstrate hypoactivity in the gland and has resulted from reduced stimulation by TSH. However, in a typical reduced TSH mediated thyroid hypoactivity, the distension of colloid in the follicular lamina is expected. Unlike to it the normal releases of thyroid hormones, as reflected by lower amount of colloid, are observed. Pericas and Jolin (1977) in their study on streptozotocin induced diabetic rats have concluded that lack of insulin diminishes the full response of thyroid to TSH and affect the pituitary TSH secretion. In light of this observation, hypoactive thyroid following induced hypoinsulinemia seems to result from diminished TSH secretion and its response on thyroid cells. However, it appears that response of TSH in thyroid hormones' synthesis is more adversely affected than the secretory capacity of the gland.

The alterations in histological results of thyroid following induced hypoinsulinemia are marked and evidently demonstrate shifts in pituitary-thyroid axis in insulin deficiency in the dwarf goat. The assay of TRH, TSH and thyroid hormones shall certainly elucidate the nature of this shift.



## REFERENCES

- BLUM, C., 1973. Effect of induced hypoglycemia on thyroid function and thyroxine turnover. *Eur. J. Clin. Invest.*, **3**: 124-129.
- BROCKMAN, R. P. 1990. Effect of insulin on utilization of propionate in gluconeogenesis in sheep. *Br. J. Nutr.*, **64**: 95-101.
- CHEEMA, A. M. AND MATTY, A. J., 1972. The relationship of thyroid stimulating hormone to the altered thyroid gland activity of alloxan and insulin treated rats. *J. Endocrinol.*, **53**: xl-xli.
- DRURY, R. A. B., WALLINGTON, E. A. AND CAMERON, S. R., 1973. *Carleton's histological techniques*. Oxford University Press, New York.
- EKHOLM, R., 1989. Anatomy and development In DeGroot, L. J. *et al.* (eds): *Endocrinology Volume 1 Part III Thyroid gland*. W. B. Saunders Company, Philadelphia.
- GRAY, R. S. BORSEY, D. Q. SETH, J. BROWN, N. AND CLARK, F. B., 1960. Prevalence of sub-clinical thyroid failure in insulin dependent diabetes mellitus. *J. Clin. Endocrinol. Metab.*, **50**: 1034-1037.
- GREENSPAN, F. S., 1997. The thyroid gland In Greenspan, F. S. & Stewler, G. J. (eds) *Basic and clinical endocrinology*. Prentice-Hall International Inc. New Jersey.
- HALMI, N. S. 1978. Anatomy and histochemistry In Werner, S. C. and Ingbar, S. H. (eds) *The thyroid: a fundamental and clinical text*. Harper and Row Publishers, New York.
- INADA, M., 1973. Thyroxine turnover and transport in diabetes mellitus. *J. Clin. Endocrinol. Metab.*, **36**: 590-597.
- JOLIN, T. AND GONZALEZ, C., 1978. Thyroxine iodine metabolism in streptozotocin diabetic rats. *Acta Endocrinol.*, **88**: 506-516.
- KUMARESAN, P. AND TURNER, C. W., 1966. Effect of alloxan on thyroid hormone secretion rate and replacement therapy with insulin. *Endocrinology*, **79**: 828.
- LEENANURUKSA, D. AND McDOWELL, G. H., 1988. Experimental diabetes in lactating sheep: Effect of alloxan on plasma insulin, glucose, glucose kinetics and milk characteristics. *Aust. J. Biol. Sci.*, **41**: 223-229.
- LIPS, J. P., JONGSMA, H. W., ESKES, T. K., 1988. Alloxan induced diabetes mellitus in pregnant sheep and chronic fetal catheterization. *Lab. Anim.*, **22**: 16-22.
- MEDEIROS-NETO, G., 1989. Endemic goiter and endemic cretinism In DeGroot, L. J. *et al.* (eds): *Endocrinology Volume 1*. W. B. Saunders Company, Philadelphia.
- MIODOVNIK, M, MIMOUNI, F., BERK, M. AND CLARK, K. E., 1989. Alloxan induced diabetes mellitus in pregnant ewe: metabolic and cardiovascular effects on the mother and her fetus. *Am. J. Obstet. Gynecol.*, **160**: 1239-1244.
- PERICAS, I AND JOLIN, T., 1977. The effect of streptozotocin induced diabetes on the pituitary thyroid axis in goitrogen-treated rats. *Acta Endocrinol.*, **86**: 128-139.
- SAUNDER, J., HALL, S. E. H. AND SONKSEN, P. H. 1978. Thyroid hormone in insulin requiring diabetes before and after treatment. *Diabetologia*, **15**: 29-32.
- SERIF, G. S. AND SIHOTANG, K., 1962. Thyroid iodine metabolism in alloxanized rats. *Proc. Soc. Exp. Biol. Med.*, **109**: 950
- SOLAR, N. AND NICHOLSON, H. 1979. Diabetes and thyroid disease during pregnancy. *Obstet. Gynecol.*, **54**: 318-321.
- WASTNEY, M. E., J. E. WOLFF, R. BICKERSTAFFE, C. F. RAMBURG AND BERMAN, M., 1983. Kinetics of glucose metabolism in sheep. *Aust. J. Biol. Sci.*, **36**: 463-467.
- ZANINOVICH, A. A., BROWN, T. J., BOADO, R., BROMAGE, N. R. AND MATTY, A. J., 1977. Thyroxine metabolism in diabetic rats. *Acta Endocrinol.*, **86**: 336-343.

ZARIPOVA, Z.Kh., 1970. Thyroid function in different forms of diabetes mellitus. *Probl. Endokrinol.*, **16**: 42-45.

(Received: 5 August, 1999)