

The level of terminal division of the ulnar nerve into superficial and deep branches- A Cadaveric Study

Harish Gaikwad^{1,*}, Rajneesh Pandey²

^{1,2}Associate Professor, Dept. of Anatomy, Seth GS Medical College & KEMH, Mumbai

***Corresponding Author:**

Harish Gaikwad

Associate Professor, Dept. of Anatomy, Seth GS Medical College & KEMH, Mumbai

Email: harishgaikwad@kem.edu

Abstract

Introduction: The level of division of the ulnar nerve into superficial and deep branches is of great clinical importance in ulnar nerve entrapment at the wrist.

This knowledge is significant during the surgical procedure of Guyon's canal release of the ulnar nerve and decompression of the deep motor branch.

Objective: To measure the level of division of the ulnar nerve into superficial and deep branches

Materials and Methods: The study was done on sixty seven formalin fixed forearms. The division of the ulnar nerve into superficial and deep was traced. The level of division was measured using a divider from the radial styloid process.

Results: In the present study mean level of division of the ulnar nerve into superficial and deep branches was 40 mm in 32 specimens of the left side and 42 mm in 35 specimens of the right side. The maximum percentage of the level of division of ulnar nerve was found in the range of 31 to 40 mm of the left side and on the right side maximum percentage was found in the range of 41 to 50 mm.

Conclusion: The mean level of division of the ulnar nerve into superficial and deep branches is variable and is approximately 40 mm from the radial styloid process which would be helpful during the surgical decompression of the deep motor branch.

Key words: Superficial and deep terminal branches of the ulnar nerve, Radial styloid process, Ulnar wrist pain, Guyon's canal syndrome

Access this article online	
Quick Response Code:	Website: www.innovativepublication.com
	DOI: 10.5958/2394-2126.2016.00048.7

Introduction

Guyon's canal syndrome is a well-defined syndrome. It has symptoms of motor and sensory abnormalities or sometimes only motor weakness or sometimes pure sensory deficit. The syndrome is not common as the carpal canal syndrome. It is important to know the anatomy of ulnar nerve as it passes through the Guyon's canal and its level of terminal division into superficial sensory and deep motor branch to get a good surgical result¹.

The Guyon's canal also called as ulnar tunnel, is an oblique fibro-osseous tunnel. The canal has the ulnar nerve, the ulnar artery with venae comitantes and loose fibrofatty tissue. The ulnar nerve divides into superficial sensory and deep motor branches in the canal¹. The sensory terminal branch of the ulnar nerve is easily seen through Guyon's canal for decompression, but the deep motor branch due to hypothenar muscles is difficult².

The ulnar nerve and the artery at the wrist passes through the fibroosseous tunnel³. The Guyon canal is the second most common site of entrapment.

Entrapment may cause purely motor, purely sensory, or a mixed lesion, depending on the site of compression⁴.

Men develop perioperative ulnar neuropathies more frequently than women⁵. Compression of the ulnar nerve can be understood in terms of the anatomic and dynamic factors. Although the ulnar nerve may be compressed at any point along its course, it is particularly susceptible at the elbow and the wrist⁶.

The superficial terminal branch, which can be palpated on the hook of the hamate, supplies palmaris brevis and divides into two palmar digital nerves. One supplies the medial side of the little finger, the other a common palmar digital nerve sends a twig to the median nerve and divides into two proper digital nerves to supply the adjoining sides of little and ring fingers⁷.

The deep terminal branch passes deeply into the palm between the heads of origin of flexor and abductor digiti minimi and through the origin of opponens digiti minimi. Passing down to the interossei, it grooves the distal border of the hook of the hamate and arches deeply in the palm within the concavity of the deep palmar arch dorsal to the flexor tendons⁸.

It supplies the three short muscles of the little finger. As it crosses the hand, it supplies the interossei and the third and fourth lumbricals. It ends by

supplying adductor pollicis, the first palmar interosseous and usually flexor pollicisbrevis. It sends articular filaments to the wrist joint⁷.

Compromising a nerve's blood supply for a long period by compression of the vasa nervorum can also cause nerve degeneration⁹.

Materials and Methods

The study was done on sixty-seven upper limbs of thirty-five cadavers of which all were male cadavers. The cadavers were embalmed with 10% formalin. Meticulous dissections were carried on these limbs.

The division of the ulnar nerve into superficial and deep terminal branches was traced. The level of division of the ulnar nerve into superficial and deep was measured with using a divider from the radial styloid process (Fig. 1).

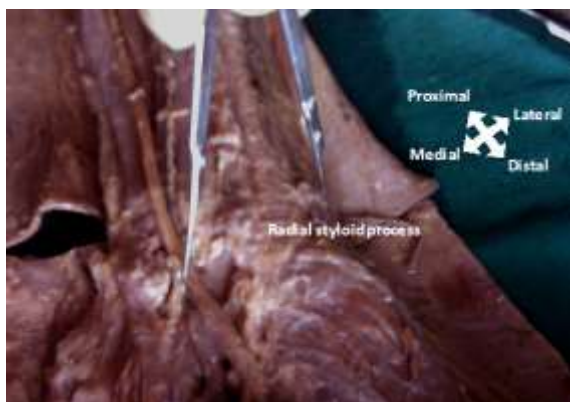


Fig. 1: Measurement of level of division of the ulnar nerve into superficial and deep branches from the tip of the radial styloid process using divider

Results

Table 1: Level of division of the ulnar nerve into superficial and deep branches measured in mm from radial styloid process

Side	No. of Specimens	Mean (mm)	SD	Range (mm)
Left	32	40	4.1	33 to 48
Right	35	42	4.7	23 to 51

Out of 32 specimens of the left side the mean of the level of division of the ulnar nerve into superficial and deep branches measured in mm from radial styloid process was 40 mm found in the range of 33 to 48 mm. Out of 35 specimens of the right side the mean of the level of division of the ulnar nerve into superficial and deep branches measured in mm from radial styloid process was 42 mm found in the range of 23 to 51 mm.

Table 2: Level of division of the ulnar nerve into superficial and deep branches measured in mm from radial styloid process (Distribution)

Range	No. of cases on the Left side	Percentage	No. of cases on the Right side	Percentage
21 to 30	0	0	1	2.86
31 to 40	18	56.25	7	20
41 to 50	14	43.75	26	74.29
51 to 60	0	0	1	2.86
Total	32	100	35	100

Maximum percentage of the level of division of the ulnar nerve into superficial and deep branches measured in mm from radial styloid process was 56.25 in 18 specimens of the left side. This was found in the range of 31 to 40 mm.

Maximum percentage of the level of division of the ulnar nerve into superficial and deep branches measured in mm from radial styloid process was 74.29 in 26 specimens of the right side. This was found in the range of 41 to 50 mm.

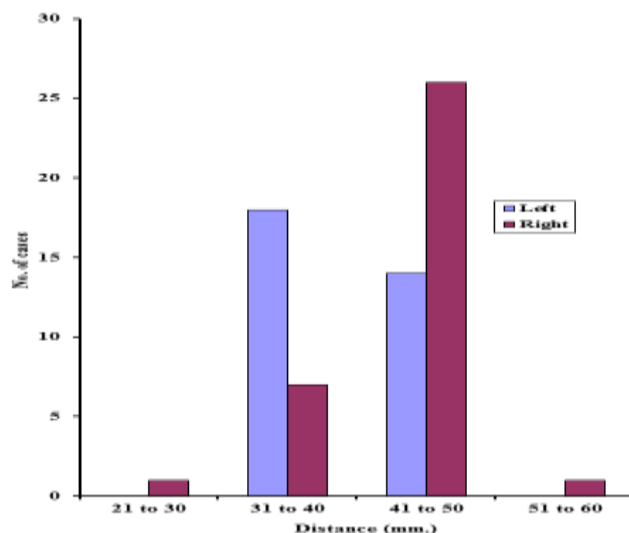


Fig. 2: Level of division of the ulnar nerve into superficial and deep branches (Distribution)

Discussion

Guyon's canal is clinically important because it contains ulnar nerve and artery. The ulnar artery is very close and radial to the ulnar nerve. Different zones of compression are classified. Zone 1 compression:- extends from the proximal edge of the palmar carpal ligament to the bifurcation of the ulnar nerve- compresses sensory and motor aspects of the ulnar nerve as well as the motor innervation of the hypothenar muscles. Zone 2 compression:- extends from the bifurcation of the ulnar nerve just distal to the fibrous arch of the hypothenar muscles- the deep motor branch of the ulnar nerve is susceptible to compression. Zone 3 compression:- contains the superficial sensory branch of the ulnar nerve¹⁰.

According to Gross M S, the ulnar tunnel of 4-4.5 cm in length is mostly vulnerable to external compression. Combined motor and sensory loss was most often due to compression from deep to ulnar nerve but pure sensory deficits was the result of compression lesions lying superficial to the ulnar nerve¹¹.

According to Sunderland the ulnar nerve divided into its superficial and deep divisions at a point, which varied from 4 to 20 mm below the radial styloid level¹².

In the present study mean level of division of the ulnar nerve into superficial and deep branches was 40 mm in 32 specimens of the left side and 42 mm in 35 specimens of the right side.

Maximum percentage was 56.25 seen in the range of 31mm to 40 mm and 43.75 percentage was seen in

the range of 41mm to 50 mm were seen in 32 specimens of the left side.

Maximum percentage was 74.29 seen in the range of 41mm to 50 mm and 20 percentage was seen in the range of 31mm to 40 mm were seen in 35 specimens of the right side.

Conclusion

The mean level of division of the ulnar nerve into superficial and deep branches is variable. It is approximately 40 mm from the radial styloid process.

The maximum level was seen in the range of 31 to 40 mm in the left side. In the right side it was seen maximum in the range of 41 mm to 50 mm.

This knowledge of anatomy would be helpful especially during the surgical decompression of the deep motor branch so to prevent permanent muscular damage.

Acknowledgement

We are deeply obliged to Dr. Pritha S Bhuiyan, Professor and HOD for their support and valuable guidance.

References

1. Paulo Henrique Aguiar et al, surgical management of Guyon's canal syndrome an ulnar nerve entrapment at the wrist, *Arq Neuropsiquiatr* 2001;59(1):106-111.
2. Susan E Mackinnon et al, Guyon's canal release of the ulnar nerve and decompression of the deep motor branch, *Peripheral nerve surgery: resource of surgeons* 2011, <http://nervesurgery.wustl.edu/so/NerveDecompressi>

- on/Ulnar/GuyonsCanalRelease/Pages/default.aspx.
(accessed on 11.2.16)
3. Bozkurt CM, Tagil MS, Ozcaka L, Ersoy M, Tekdemir I. Anatomical variations as potential risk factors for ulnar tunnel syndrome: A cadaveric study. *Clinical Anatomy*. 2005; 18.Pp 274-280.
 4. Stern M, Steinmann P S. Ulnar Nerve Entrapment. 2004. Available from: <http://www.emedicine.com/orthoped/topic574.htm> (accessed on 25.08.05).
 5. Contreras GM, Warner AK, Charboneau JW, Cahill RD. Anatomy of the ulnar nerve at the elbow: Potential relationship of acute ulnar neuropathy to gender differences. 1998; 11. Pp 372-378.
 6. Ulnar nerve anatomy and compression. *Orthop Clin North Am*. 1996; 27(2):317-38. Available from: <http://www.ncbi.nlm.nih.gov/entrez/query.fcgi?CMD=search&DB=pubmed> (accessed on 25.08.05).
 7. Johnson D, Harold E. Wrist and Hand. In: Gray' Anatomy. In: The anatomical basis of clinical practice.39th edition. Elsevier Churchill Livingstone. 2005. Pp 932.
 8. Last RJ. Upper limb. In: Anatomy regional and applied. Tenth edition. London: English Language Book Society (ELBS). 2002. Pp 52-94.
 9. Sunderland S. Nerve repair. General considerations. In: Nerve and Nerve injuries, second edition, Churchill Livingstone, Edinburgh. 1978. Pp 505 to 532.
 10. Wheless Textbook of Orthopaedics, Tunnel of Guyon, Available from: http://www.whelessonline.com/ortho/tunnel_of_guyon (accessed on 17.2.2016).
 11. Gross MS, Gelberman RH, The anatomy of the distal ulnar tunnel, *Clin Orthop Relat Res*. 1985 Jun;(196):238-47.
 12. Sunderland S. The Ulnar nerve. Anatomical and Physiological features. In: Nerve and Nerve injuries, second edition, Churchill Livingstone, Edinburgh. 1978. Pp 728-749.