

The Correlation between Ultrasound Testicular Volume and Conventional Semen Parameters in Albanian Subfertile Males

Adrian Kristo^{1*}, Evin Dani²

¹Imaging Service HUC Tirana, Tirana, Albania; ²Male Infertility Center, Tirana, Albania

Abstract

Citation: Kristo A, Dani E. The Correlation between Ultrasound Testicular Volume and Conventional Semen Parameters in Albanian Subfertile Males. *OA Maced J Med Sci*. 2014 Sep 15; 2(3):464-466. <http://dx.doi.org/10.3889/oamjms.2014.081>

Key words: testicular volume; ultrasound; subfertile males; sperm parameters; Albania.

***Correspondence:** Dr. Adrian Kristo. Imaging Service HUC Tirana, Radiology, rr.e Dibres 372, Tirana 1004, Albania. Phone: 0675075772. E-Mail: ardesa.sa@hotmail.com

Received: 11-Jun-2014; **Revised:** 31-Jul-2014; **Accepted:** 10-Aug-2014; **Online first:** 06-Sep-2014

Copyright: © 2014 Kristo & Dani. This is an open access article distributed under the terms of the Creative Commons Attribution License, which permits unrestricted use, distribution, and reproduction in any medium, provided the original author and source are credited.

Competing Interests: The authors have declared that no competing interests exist.

OBJECTIVE: The study is conducted to evaluate the relationship between testicular volume measured by ultrasound and conventional sperm parameters (volume, concentration, total count, motility and morphology) in Albanian subfertile males and to determine a normal limit value of the testicular volume.

MATERIALS AND METHODS: A total of 500 males were observed for this study. The testicular volumes of all subjects were measured by ultrasonography. The semen samples were collected by the process of masturbation after 3-5 days of ejaculatory abstinence and were analyzed according to WHO criteria 2010.

RESULTS: Testicular volume has a strong positive correlation with sperm count, total count and motility and a positive correlation with semen volume.

CONCLUSION: Testicular volume has a direct correlation with semen parameters and the critical total testicular volume indicating normal testicular function is approximately 26.6 ml (the mean testicular volume 13.3 ml). The measurement of testicular volume can be helpful for assessing fertility at the initial physical examination.

Introduction

The examination of the infertile man comprises physical examination, semen analysis, and hormone testing and ultrasound examination. Since the seminiferous tubules comprise 75–85% of the testicular mass, testicular volume is likely to reflect spermatogenesis and semen profiles in infertile men. The testis is composed primarily of seminiferous tubules packed closely together and also interstitial cells. Each tubule is 30-70 cm long and 200-300 microns in diameter. There are approximately 500-600 tubules per testis. The cells within the seminiferous tubules are germ cells that get matured into spermatozoa, and Sertoli cells that serve as supporting cells for developing germ cells. Sertoli cells create a blood-testis barrier and separate the germinal epithelium into basal and luminal compartments. The

WHO 2010 criterion for semen are: the lower reference limit for semen volume is 1.5 ml; the lower reference limit for total motility (PR + NP) is 40%; the lower reference limit for sperm concentration is 15 million spermatozoa per ml; the lower reference limit for total sperm number is 39 million spermatozoa per ejaculate; the lower reference limit for sperm morphology is 4 %.

Testicular volume measurement methods involve the use of calipers, orchidometry or ultrasonography. Orchidometry is a conventional method that has been used for many years but the cut off testicular volume that indicates normal testicular function is not established. Some studies have concluded that the ultrasound measurement of testicular volume is more confident than orchidometry [1, 2]. Bahk JY and others have showed that in a

group of 20-27 years old males the mean total testicular volume was 36.5 ml [3]. Bujan and others have demonstrated that testicular volume is considered to be a reliable indicator of testicular function [4]. By Condorelli and others the normal testis is >15 ml and abnormal testis is <12 ml [5]. Kumar found a strong positive correlation between testicular volume and sperm total count, he found poor semen parameters in males with total testicular volume <26 ml [6]. Aribarg studying a group of fertile Thai males found the mean total testicular volume 34.4 ml, range (24-50 ml) [7]. The mean ultrasonic total testicular volume showed by Lenz.S in a group of infertile males was 20.6 ml [8].

Based on this research, the relationships between testicular volume and semen parameters were evaluated using testicular volume as a marker for testicular fertility function.

Materials and Methods

The study was conducted in HUC Radiology Department and Male Infertility Center. Over a period of 7 months, from January 2013 to July 2013, 500 men presenting for male infertility, referred to andrologist during couple infertility work out, aged 20-50 years, were examined. Semen analyses were performed to evaluate the semen quality according to WHO 2010 standard [9]. Scrotal ultrasound was performed to evaluate the testicular echo structure, volume of both testis and the presence of varicocele by Color Doppler and pulsed Doppler. During ultrasound examination the patient was placed in a supine position with the legs slightly spread apart. Highfrequency linear transducer (7.5-10 MHz) that performs both power and spectral Doppler ultrasonography is used. Using the ultrasound was measured the length, the height and width of the right testis and the left testis. The volume of each testes was calculated by using formula $V = L \times W \times H \times 0.71$ (L-length, longitudinal diameter; W-width, transversal diameter; H-height, AP diameter) as established before in a lot of studies [6].

Past history of infection like mumps, measles, orchitis and any surgical procedure were also noted. The clinical diagnosis was confirmed by ultrasonography and cases with previous testicular torsion or injury and other associated diseases were excluded from the statistical analysis.

After 3-5 days of ejaculatory abstinence the semen samples were collected in a sterile container by the process of masturbation from the subjects. The collected samples were allowed to liquefy at 37°C for 30 minutes and analyzed within one hour after collection. Microscopic examinations were carried out to record the sperm count, total sperm count, motility and morphology of the sperm according to WHO Guideline (2010) [9].

To estimate the levels of different sperm parameters including testicular volume, mean and standard deviation of the same were worked out. Independent t-test was performed. Pearson correlation coefficient was worked out to assess the linear relationship of testicular volume with different sperm parameters. Data was entered into the computer using Microsoft Excel.

Results and Discussion

The mean age for all participants was 31.48 years with a standard deviation (S.D) of 3.8 years. Among patients, 13 men (2.6 %) failed to give semen (aspermia) even after three attempts. Mean testicular volume in aspermic men was 18.1 ml. Other 79 patients had testes damage post orchitis (29 patients), post herniorrhaphy (15), post orchipexy (15), had cryptorchidism (10), had only one testis (8) and in two cases it was malignant tumor testes. For the other 408 patients in the Table 1 is the relationship between total testicular volume (right testicular volume + left testicular volume) and semen volume, sperm count per ml, total sperms per ejaculate, motility and morphology.

Table 1: Correlation between total testicular volume and the variables.

Variables	r*	P value
Age	0.02	0.692
Semen Volume	0.247	<0.0001
Concentration	0.499	<0.0001
Mobility	0.484	<0.0001
Morphology	0.382	<0.0001
Total spermatozoa	0.514	<0.0001

*Pearson correlation coefficient.

No correlation is seen between total testicular volume and the age. Significant positive correlation is seen between total testicular volume and semen volume ($r = 0.247, p < 0.0001$), because the testis contributes only 5 % of the semen volume. Pearson correlation test was strongly significant between testicular volume and total sperm count ($r = 0.514, p < 0.0001$), between testicular volume and sperm count per ml ($r = 0.499, p < 0.0001$). Highly positive relationship was observed between testicular volume and sperm motility ($r=0.484, p < 0.0001$).

Table 2: Total count of spermatozoa.

Variables	Total count of spermatozoa		T value	P value
	Abnormal (under 39000000) (n=223)	Normal (>=39000000) (n=185)		
TTV	26.58 ± 9.69	36.31 ± 7.44	10.842	<0.001
RTV	13.31 ± 4.98	18.55 ± 3.83	10.806	<0.001
LTV	13.06 ± 4.80	17.87 ± 3.71	10.664	<0.001

TTV, total testicular volume; RTV, right testes volume; LTV, left testes volume.

Both sperm count per ml and total sperm count per ejaculate were directly related to total testicular volume. One hundred and five men had normal total sperm count per ejaculate (39 million and above) demonstrating the average total testicular volume of 36.31 ml (± 7.44), range (20 ml – 63 ml), the mean testicular volume 18.15 ml (the mean right testis 18.55 ml and the mean left testis 17.87 ml).

Two hundred twenty three men had a normal

total sperm count (< 39 million) demonstrating the average total testicular volume 26.58 ml (\pm 9.69),

Table 3: Total count of pathological spermatozoa according testes measurement.

Testes measurement	Total count of spermatozoa pathological (< 39000000)					
	Average	SD	Median	Mode	Minimum	Maximum
RTL	38.48	4.56	39	39	16	50
RTW	26.37	4.28	27	27	10	35
RTH	17.91	2.93	18	18	7	25
LTL	38.18	4.47	38	38	16	50
LTW	25.96	4.13	26	27	10	34
LTH	17.74	2.89	18	18	7	24

RTL, right testis length; RTW, right testis width; RTH, right testis height; LTL, left testis length; LTW, left testis width; LTH, left testis height.

range (2 ml – 56 ml), and the mean testicular volume 13.29 ml (the right testis 13.31 ml and the left testis 13.06 ml). This difference of the testis volume is statistically significant ($p < 0.0001$) (Table 2). Figures 1 and 2 represent two small testes; Figures 3 and 4 represent two normal testes.

Table 4: Total count of pathological spermatozoa according testes measurement.

Testes measurement	Total count of spermatozoa normal (\geq 39000000)					
	Average	SD	Mediane	Mode	Minimum	Maximum
RTL	43.32	3.80	43	43	33	51
RTW	29.50	1.95	30	30	24	35
RTH	20.19	1.37	20	20	16	25
LTL	42.85	3.74	43	43	35	51
LTW	29.04	2.00	29	29	23	35
LTH	19.97	1.42	20	20	15	25

The results for testes dimensions are in Table 3 and 4. For a normal sperm count the right testis measures: L = 38.4 mm (\pm 4.5), W = 26.3 mm (\pm 4.2), H = 17.9 mm (\pm 2.9); the left testes measures: L = 38.1 mm (\pm 4.4), W = 25.9 mm (\pm 4.1), H = 17.7 mm (\pm 2.8). For normal sperm count the right testis measures: L = 43.32 mm (\pm 3.8), W = 29.5 mm (\pm 1.9), H = 20.19 mm (\pm 1.37); the left testes measures: L = 42.85 mm (\pm 3.74), W = 29 mm (\pm 2), H = 19.97 mm (\pm 1.4).

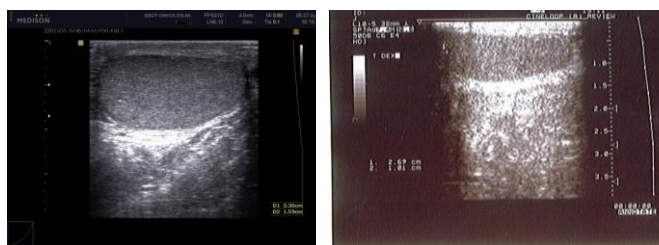


Figure 1: Scrotal ultrasound of two small testes.

Between 183 males with normal total count 14 males have the TTV < 27 ml, and from this number 6 men have normal spermiogram, the other 8 have asthenospermia or teratospermia. From all 117 men that have TTV < 27 ml, only 6 men (5%) have normal spermiogram. We did not find any male that have normal spermiogram with total testicular volume under 20 ml.

In conclusion, correlation exists between

testicular function and testicular volume measured by ultrasound. Smaller testes have poor semen quality, a lower number of spermatozoa, lower motility. Our

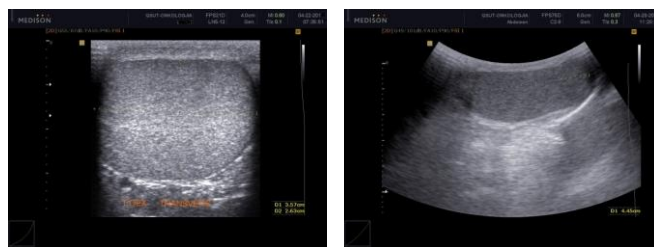


Figure 2: Scrotal ultrasound of two normal testes.

study shows that the threshold value of normal total testicular volume is 26.6 ml, testicular volume 13.3 ml with testis measures: 38 x 26 x 18 mm. If the total testicular volume is < 27 ml the semen is abnormal for 95% of patients, and if the volume is <20 ml the semen is abnormal for all patients.

References

1. Sakamoto H, Ogawa Y, Yoshida H. Relationship between testicular volume and testicular function: comparison of the Prader orchidometric and ultrasonographic measurements in patients with infertility. *Asian J Androl.* 2008;10(2):319-24.
2. Sakamoto H, Saito K, Oohta M, Inoue K, Ogawa Y, Yoshida H. Testicular volume measurement: comparison of ultrasonography, orchidometry, and water displacement. *Urology.* 2007;69(1):152-7.
3. Bahk JY, Jung JH, Jin LM, Min SK. Cut-off value of testes volume in young adults and correlation among testes volume, body mass index, hormonal level, and seminal profiles. *Urology.* 2010;75(6):1318-23.
4. Bujan L, Mieusset R, Mansat A, Moatti JP, Mondinat C, Pontonnier F. Testicular size in infertile men: relationship to semen characteristics and hormonal blood levels. *Br J Urol.* 1989;64(6):632-7.
5. Condorelli R, Calogero AE, La Vignera S. Relationship between Testicular Volume and Conventional or Nonconventional Sperm Parameters. *Int J Endocrinol.* 2013;2013:145792.
6. Mbaeri TU, Orakwe JC, Nwofor AME, Oranus CK, Mbonu OO. Ultrasound measurements of testicular volume: Comparing the three common formulas with the true testicular volume determined by water displacement. *African Journal of Urology.* 2013;19(2):69–73.
7. Aribarg A, Kenkeerati W, Vorapaiboonsak V, Leepipatpaiboon S, Farley TM. Testicular volume, semen profile and serum hormone levels in fertile Thai males. *Int J Androl.* 1986;9(3):170-80.
8. Lenz S, Thomsen JK, Giwercman A, Hertel NT, Hertz J, Skakkebaek NE. Ultrasonic texture and volume of testicles in infertile men. *Hum Reprod.* 1994;9(5):878-81.
9. Jungwirth A, Diemer T, Giwercman A, Kopa Z, Krausz C, Tournaye H. Guidelines for the investigation and treatment of male infertility. *Eur Urol* 2002;42(4):313-22.