

Vascular Endothelial Growth Factor in Colonic Cancer, Ulcerative Colitis and Colonic Adenoma: An Immunohistochemical Study

Amina A. Gamal el Din¹, Reham Sh. E. Esmail^{1*}, Amal A. Hareedy²

¹National Research Center, Pathology, Cairo, Egypt; ²Cairo University, Pathology, Cairo, Egypt

Abstract

Citation: Gamal el Din AA, Esmail RSE, Hareedy AA. Vascular Endothelial Growth Factor in Colonic Cancer, Ulcerative Colitis and Colonic Adenoma: An Immunohistochemical Study. *OA Maced J Med Sci*. 2014 Sep 15; 2(3):439-443.
<http://dx.doi.org/10.3889/oamjms.2014.075>

Key words: VEGF; ulcerative colitis; colon cancer; colonic adenoma.

***Correspondence:** Dr. Reham Sh Esmail. National Research Centre, Pathology, El Behos St. Doki, Giza 046, Egypt. E-Mail: rehamelnemr@yahoo.com

Received: 12-Apr-2014; **Revised:** 19-Jun-2014; **Accepted:** 23-Jul-2014; **Online first:** 10-Aug-2014

Copyright: © 2014 Gamal el Din et al. This is an open access article distributed under the terms of the Creative Commons Attribution License, which permits unrestricted use, distribution, and reproduction in any medium, provided the original author and source are credited.

Competing Interests: The authors have declared that no competing interests exist.

BACKGROUND: Colon cancer is one of the most common malignancies worldwide. Colonic adenoma and ulcerative colitis (UC) are important precancerous lesions. Vascular Endothelial Growth Factor (VEGF) is a well-known pro-angiogenic factor plays important role in physiologic and pathologic conditions and in neovascularization in cancer and hence becomes a potential target for anti-angiogenic cancer therapy.

AIM: This study investigated VEGF immunohistochemical expression in colon cancer and its precancerous lesions.

MATERIAL AND METHODS: Paraffin blocks from two hospitals were collected in a year: Colon cancer: 20 cases, colonic adenoma: 15 cases, UC: 15 cases and 5 controls from normal mucosa. VEGF was assessed immunohistochemically using a primary anti-VEGF antibody (VG1, Dako, Denmark).

RESULTS: Median age was 49 years (range 31-52) in cancer, 40 years (range 31-52) in adenomas and 33 years (range 27-43) in UC. VEGF expression was negative in control, significantly strongly positive in 90% of colonic adenocarcinoma ($p=0.001$), significantly positive in adenomas ($p=0.002$) - the weak positivity significantly seen in mild dysplasia ($p=0.001$) - and significantly positive in 73.3% of UC cases ($p=0.022$).

CONCLUSION: The significant increase in positivity of VEGF in precancerous to cancerous lesions may point to its potential role in the pathogenesis and progression of colonic neoplasia.

Introduction

Colon cancer is one of the most common malignancies in Egypt with about 142 registered cases per year in one Government (the only available population based registry) [1] and the third leading cause of cancer-related mortality according to the latest Egyptian registry [2].

The gradual increase of incidence and mortality of colon cancer recommended a deeper understanding of its pathogenesis and biology which is crucial for establishing novel therapeutic and diagnostic strategies [3].

A number of colon carcinoma risk factors have been identified including; life style, obesity, diet and smoking. It may also evolve from a number of precancerous lesions, among which adenoma and ulcerative colitis (UC) are recorded.

The adenoma –carcinoma progression in colon is a multistep process characterized by genetic alterations and mutation accumulation [5, 6]. Based on epidemiological, clinical, postmortem, and molecular biological studies, the concept that colorectal cancers (CRC) may arise from pre-existing adenomas is now widely accepted [7, 8].

Ulcerative colitis (UC) is a chronic and relapsing inflammation of the colonic mucosa; the continuous inflammation may repeatedly destroy the epithelial cells [9]. This has to be compensated by epithelial increased proliferation, hyperplasia, dysplasia which finally can lead to inflammation-associated colorectal cancer (CRC) [10, 11]. The risk is estimated to reach up to 2.4 folds that seen in normal population in some studies [12].

Angiogenesis was proved to play important role in carcinogenesis [3]. However, few data are

available on pre-malignant conditions [13].

Vascular Endothelial Growth Factor (VEGF) is a well-known pro-angiogenic factor [14]. It increases vascular permeability, stimulates leukocyte adhesion to the endothelium, and promotes monocyte chemotaxis that promotes tumor neovessel angiogenesis. It has long been proposed as an important biomarker for cancer as well as a target for anti-angiogenic cancer therapy. Elevated VEGF expression levels are appreciated in most solid tumors, including colon carcinoma [15].

In pre-malignant lesions, VEGF was found to be significantly increased in some organs, such as in the oral mucosa, skin, and uterine cervix. So, it was suggested that tumor angiogenesis is not necessarily a characteristic of invasive tumor, but may be an early event during tumorigenesis [13].

This work aimed at studying the immunohistochemical expression of VEGF in colon cancer and the related two important precancerous lesions; colonic adenomas and ulcerative colitis. This is an attempt to investigate the potential role of VEGF in the pathogenesis of colonic neoplasia and ulcerative colitis.

Material and Methods

Paraffin blocks of 55 cases were included; twenty cases of colonic cancer of different degrees of differentiation, 15 cases of colonic adenoma, and 20 cases of ulcerative colitis, additional 5 blocks of normal colonic mucosa were obtained as a control all were collected in the duration of a year from 2011/2012 from Nasr Institute hospital (specialized national Hospitals) and Mahmoud Hospital (Non-Governmental Organization Hospital).

Blocks were sectioned at 5 micron thickness on positive charged slides, revised for the histopathological diagnosis by two independent pathologists (A.G & R.SH) and then stained for VEGF immunostains according to the following steps:

Slides were hydrated in descending grades of alcohol followed by distilled water. Endogenous peroxidase activity was quenched by 0.3% hydrogen peroxide for 5 minutes followed by rinsing in distilled water and three times wash in phosphate buffer saline (PBS) pH 7.4. The primary mouse antihuman monoclonal antibody; Vascular Endothelial Growth Factor- VEGF (Clone VG1); DAKO, Denmark; was applied and incubated for 30 minutes and then the slides were rinsed in successive baths of PBS. DAKO Envision detection kit was used. Diaminobenzidine tetrachloride (DAB) was used as chromogen.

Slides were counterstained in Harris haematoxylin (Hx), dehydrated, and cleared in xylene and coverslipped. Reactive lymph nodes and internal control were used as positive control. Slides with omitted antibodies were used as negative control.

Interpretation of IHC

Cytoplasmic and/or membrane specific positive tumor cells were assessed [16].

In the literatures, it was observed that the interpretation of VEGF in different organs may differ, yet it was preferred to interpret according to Zhang et al.; being a relatively recent study done on colonic tissue as well. According to this study, five fields were randomly selected and immunohistochemical staining of the cells was assessed according to both the proportion of cells stained and the staining intensity.

The proportion of cells stained was assessed using a semiquantitative 4-point scale: 0, <10% staining; 1, 10–20% staining; 2, 21–50% staining; and 3, >50% staining.

The staining intensity was also graded using a 4-point scale: 0, no staining; 1, light yellow; 2, brown; and 3, dark brown.

The combined score was calculated by multiplying the individual scale of the proportion and intensity (range 0–9) and was assessed as follows: 0–2, negative staining (-); 3–6, positive staining (+); and ≥6, strong positive staining (++) [3].

Statistical analysis

Data were statistically described in terms of frequencies (number of cases) and relative frequencies (percentages). Chi square (χ^2) test was performed to compare the different study variables between the study groups. Yates correction and Fisher exact tests were used only when the expected frequency was found to be less than five. A probability value (p value) less than 0.05 was considered statistically significant.

All statistical calculations were done using computer programs Microsoft Excel version 7 (Microsoft Corporation, NY, USA) and SPSS (Statistical Package for the Social Science; SPSS Inc., Chicago, IL, USA) statistical program.

Results

Review of the epidemiologic data of the studied cases: - the study included 50 cases; - Cases of colonic adenocarcinoma ranged in age from 34years up to 65years with median of 49 years; - Cases of the adenomatous polyps ranged in age from 31years up to 52years with median of 40 years; - cases of ulcerative colitis ranged in age from 27 years to 43years with median of 33 years; - among the studied cases of adenocarcinoma, the highest frequency (72%) occurred in males, while there was no significant sex difference in adenomatous polyps studied cases (46.7% male: 53.3% female), and in UC cases (40% male: 60% females).

Results of VEGF expression (Table 1, Figure

1): - cases of the control group showed absent or focal pale staining (combined score 0-2; negative); - strong cytoplasmic expression for VEGF (combined score <6; ++) was observed in 90% of the adenocarcinoma cases, rest of the cases (10%) showed cytoplasmic positivity (combined score 3-6; +). The difference between VEGF expressions in carcinomas compared to the control cases was highly significant (p=0.001).

The difference in VEGF immunohistochemical expression between adenocarcinoma cases of moderate differentiation compared to those of poor differentiation was insignificant (p= 0.321).

All cases of adenomas showed positive cytoplasmic reaction for VEGF, The difference in VEGF immunohistochemical expression between the adenoma cases and the control was significant (p=0.002).

Table1: Immunohistochemical expression of VEGF in the different diagnostic groups and their comparison to control group.

VEGF SCORE	Studied cases					Control N (%)
	Carcinoma - differentiation		Adenoma - dysplasia		Ulcerative colitis	
	Mod. N (%)	Poor N (%)	Mild N (%)	Mod.& marked N (%)	N (%)	
0-2 (-)	0 (0)	0 (0)	0 (0)	0 (0)	4 (26.7)	5 (100)
3-6 (+)	2 (10)	0 (0)	4 (26.7)	0 (0)	10 (66.7)	0 (0)
≥6 (++)	12 (60)	6 (30)	0 (0)	11 (73.3)	1 (6.7)	0 (0)
Total	14 (70)	6 (30)	4 (26.7)	11 (73.3)	15 (100)	5 (100)
P value when compared with the control	p=0.001		P=0.002	P=0.002	p= 0.022	-

Strong positivity (score < 6, ++) was seen in 73.3% (cases of moderate to marked dysplasia), while (combined score 3-6; +) was seen in 26.7% of the cases (cases of mild dysplasia).

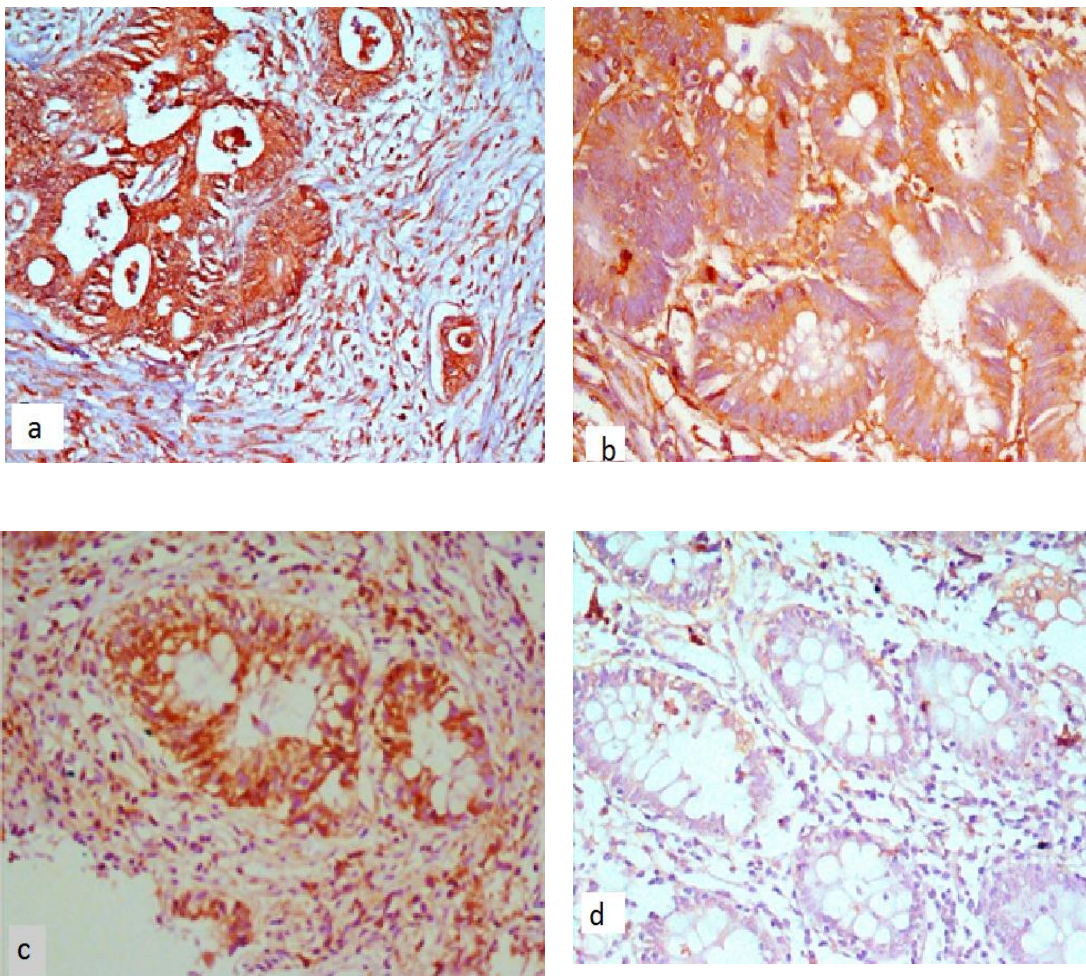


Figure1: (a) A case of colonic adenocarcinoma showed strong diffuse VEGF cytoplasmic immunostain(X200) (b) A case of colonic adenoma with moderate dysplasia showed diffuse strong cytoplasmic immunostain for VEGF(X400), (c) A case of ulcerative colitis showed strong cytoplasmic VEGF immunostain in some cells (X200), (d) A normal control showed almost negative VEGF immunostain (X200).

The low positivity score was significantly seen in mild dysplasia ($p= 0.001$). The difference in VEGF immunohistochemical expression between adenomas of marked dysplasia and carcinomas was insignificant ($p= 0.072$), while the difference between adenomas with mild dysplasia and cases of adenocarcinomas was significant ($p= 0.003$). In UC; 26.7% of the cases showed negative reaction for VEGF in the epithelial cells (combined score 0-2; -), 66.7% showed positive reaction (combined score 2-6; +), 6.6% showed strong positivity (combined score > 6 ; ++).

It was noticed that the lamina propria in all cases showed strong VEGF expression.

In comparison with the control cases; the diagnosis of ulcerative colitis was significantly associated with VEGF positivity ($p= 0.022$).

The overall difference between cases of adenocarcinoma and cases of ulcerative colitis in VEGF positivity was insignificant ($p= 0.1$); however, high positivity score ($> 6-9$) was significantly associated with adenocarcinoma cases ($p= 0.04$).

Discussion

Colon cancer is the third most common cancer worldwide in both sexes [8] and one of the most frequent cancers in Egypt [2].

Colonic adenomas and UC are two documented precancerous lesions, whose proper control is thought to affect cancer colon incidence largely [17].

Angiogenesis plays a significant role in tumor genesis and progression and so its targeting jumped to be a priority in oncology [18].

In the present study we examined the immunohistochemical expression of a potent pro-angiogenic factor VEGF in two premalignant colonic lesions; the adenomas and ulcerative colitis, compared to its expression in colon cancer cases and normal colonic mucosal control in Egypt.

The study included 20 cases of colorectal cancer; 15 cases of adenomatous polyps, 15 case of ulcerative colitis and 5 control specimens.

According to our cases (90%) of colonic adenocarcinoma cases were strongly positive for VEGF, with no significant differences between cases of moderate and poor differentiation.

The positivity of colon cancer cells for VEGF is proved in many studies. Islam et al. stated that increased expression of vascular endothelial growth factor (VEGF) occurs concurrently with increasing vascular density of an invasive tumor of colon cancer and increased in the context of metastasis, and recurrence [19].

Chen et al. stated that the level of VEGF expression is significantly raised in colorectal cancer compared with polyps and normal mucosa [20].

As well Cao et al. got similar results and recommended that VEGF should be added to the list of biomarkers used in clinical practice for CRC [21].

In the present study adenoma cases showed a significant difference in the expression of VEGF; between different grades of dysplasia; positivity increasing with the increase in the grade of the dysplasia.

Adenomas with moderate and marked dysplasia showed strong VEGF expression in 73.3% of cases, while all the cases of adenoma with mild dysplasia showed mild positivity.

Generally a limited number of studies in the literature studied the expression of VEGF in colonic adenomas. In 2007, Shin et al., studied the expression of VEGF and other factors in cases of adenomas, early carcinoma and advanced carcinoma and they noticed the increase in the VEGF protein expression from adenoma to early cancer to advanced cancer cases. Similarly, Raica et al. got similar findings. Both studies concluded that VEGF is implicated in the progression from adenoma to carcinoma and they proposed that estimation of VEGF can be helpful in follow up of adenoma cases to detect early carcinogenesis and further progression of colon cancer [13]. However, both studies didn't correlate the expression with the degree of dysplasia in adenomas.

Cases of UC in the current study showed variable results for VEGF reactivity of the epithelial mucosal cells; 26.7% of the cases showed negative reaction for VEGF (score 0-2,-), 66.7% showed positive reaction (score 3-6, +), 6.6% showed strong positivity (score > 6 , ++). Strong VEGF expression is seen in the lamina propria in all cases.

In the literatures, variable results are demonstrated: Giatromanolaki et al. found that the expression of VEGF in UC was weak. Kapsoritakis et al., found that its expression in UC was almost similar to that in normal control, both suggested that the pathogenesis of UC is not VEGF dependent [22, 23].

However, more recent studies; Alkim et al., noticed that VEGF is increased in IBD patients' tissue and their sera [24]. As well, Griga et al. found increased expression of VEGF in epithelium of the inflamed mucosa and non-inflamed mucosa of patients of active UC, and in the interstitial lamina propria due to accumulation of the VEGF producing leucocytes [25].

Similarly, Tsiolakidou et al. & Tolstanova et al., noticed increased VEGF expression in the mucosa of UC cases compared to the healthy control, and proposed a possible role of angiogenesis in the pathogenesis of inflammatory bowel diseases mostly

by increasing vascular permeability and promoting the infiltration of inflammatory cells [26, 27]. This also was the base on which Tolstanova et al., built their experimental study, in which they highlighted that Neutralizing anti-VEGF antibody significantly ameliorates experimental UC in rats in part by reducing excessive vascular permeability and decreasing inflammatory cells infiltration [28].

A similar conclusion was achieved by Pousa et al., who suggested that a better understanding of the angiogenic process may facilitate the design of more effective therapies for chronic intestinal inflammation [29].

As a conclusion, the current work proposes that the angiogenic factor VEGF may play a role in the pathogenesis of colonic neoplasia and ulcerative colitis. This may support the introduction of anti-VEGF as adjuvant to chemotherapy in colon cancer management, and as a follow up parameter in colonic adenomas and UC cases.

References

- Veruttipong D, Soliman AS, Gilbert SF, Blachley TS, Hablas A, Ramadan M, Rozek LS, Seifeldin IA. Age distribution, polyps and rectal cancer in the Egyptian population-based cancer registry. *World J Gastroenterol*. 2012; 18(30): 3997-4003.
- Mokhtar N, Gouda I, Adel I (editors). Malignant endocrine system tumors. In : Cancer pathology registry 2003-2004 and time trend analysis 1ST edition. NCI, 2007: 91-93.
- Zhang Y, Liu X, Zhang J, Li L, and Liu C. The expression and clinical significance of PI3K, pAkt and VEGF in colon cancer. *Oncol Lett*. 2012; 4: 763–766.
- Haggar FA, Boushey RP. Colorectal cancer epidemiology: incidence, mortality, survival, and risk factors. *Clin Colon Rectal Surg*. 2009;22:191-7.
- Sun Y, Yokoi K, Li H, Gao J, Hu L, Liu B, Chen K, Hamilton SR, Fan D, Sun B, Zhang W. NGAL expression is elevated in both colorectal adenoma-carcinoma sequence and cancer progression and enhances tumorigenesis in xenograft mouse models. *Clin Cancer Res*. 2011;17:4331-40.
- Berger AW, Etrich TJ, Dollinger MM. Colon Polypectomy - And Then? .*Zentralbl Chir*. 2013. [Epub ahead of print]
- Nussrat FL, Ali HH, Hussein HG, AL-Ukashi RJ. Immunohistochemical Expression of ki-67 and p53 in Colorectal Adenomas: A Clinicopathological Study. *Oman Med J* 2011; 26:229-234.
- Tocantins de Sousa WA, Rodrigues LV, Silva Jr RG, Vieira FL. Immunohistochemical evaluation of p53 and Ki-67 proteins in colorectal adenomas. *Arq Gastroenterol*. 2012;49:35-40.
- Rogler G. Inflammatory bowel disease cancer risk, detection and surveillance. *Dig Dis*. 2012;30:48-54.
- Lukas M. Inflammatory bowel disease as a risk factor for colorectal cancer. *Dig Dis*. 2010;28:619-24.
- Lichtenstein GR& Rutgeerts P. Importance of mucosal healing in ulcerative colitis. *Inflamm Bowel Dis*. 2010;16:338-46.
- Jess T, Rungoe C, Peyrin-Biroulet L. Risk of colorectal cancer in patients with ulcerative colitis: a meta-analysis of population-based cohort studies. *Clin Gastroenterol Hepatol*. 2012;10:639-45.
- Raica M, Cimpean AM, Ribatti D. Angiogenesis in pre-malignant conditions. *Eur J Cancer*. 2009;45:1924-34.
- Pohl M, Werner N, Munding J, Tannapfel A, Graeven U, Nickenig G, Schmiegel W, Reinacher-Schick A. Biomarkers of anti-angiogenic therapy in metastatic colorectal cancer (mCRC): original data and review of the literature. *Z Gastroenterol*. 2011 ;49:1398-406.
- Pringels S, Van Damme N, De Craene B, Pattyn P, Ceelen W, Peeters M, Grooten J. Clinical procedure for colon carcinoma tissue sampling directly affects the cancer marker-capacity of VEGF family members. *BMC Cancer*. 2012; 12: 515.
- Liang J, Wang H, Xiao H, Li N, Cheng C, Zhao Y, Ma Y, Gao J, Bai R Zhen H. Relationship and prognostic significance of SPARC and VEGF protein expression in colon cancer. *J Exp Clin Cancer Res*. 2010, 29:71.
- Salazar R, Roepman P, Capella G, Moreno V, Simon I, Dreezen C. Gene expression signature to improve prognosis prediction of stage II and III colorectal cancer. *J Clin Oncol* 2011;29:17–24.
- Lazăr D, Raica M, Sporea I, Tăban S, Goldiș A, Cornianu M. Tumor angiogenesis in gastric cancer. *Rom J Morphol Embryol*. 2006;47(1):5-13.
- Islam R, Chyou PH, Burmester JK. Modeling efficacy of bevacizumab treatment for metastatic colon cancer. *J Cancer*. 2013 Apr 29;4(4):330-5.
- Chen JC, Chang YW, Hong CC, Yu YH and Su JL. Review The Role of the VEGF-C/VEGFRs Axis in Tumor Progression and Therapy. *Int J Mol Sci*. 2013; 14, 88-107.
- Cao D, Hou M, Guan YS, Jiang M, Yang Y, Gou HF. Expression of HIF-1alpha and VEGF in colorectal cancer: association with clinical outcomes and prognostic implications. *BMC Cancer*. 2009;9:432.
- Giatromanolaki A, Sivridis E, Maltezos E, Papazoglou D, Simopoulos C, Gatter KC, Harris AL, Koukourakis MI. Hypoxia inducible factor 1alpha and 2alpha overexpression in inflammatory bowel disease. *J Clin Pathol*. 2003;56(3):209-13.
- Kapsoritakis A, Sfiridaki A, Maltezos E, Simopoulos K, Giatromanolaki A, Sivridis E, Koukourakis MI. Vascular endothelial growth factor in inflammatory bowel disease. *Int J Colorectal Dis*. 2003;18(5):418-22.
- Alkim C, Sakiz D, Alkim H, Livaoglu A, Kendir T, Demirsoy H, Erdem L, Akbayir N, Sokmen M. Thrombospondin-1 and VEGF in inflammatory bowel disease. *Libyan J Med*. 2012;7.
- Griga T, May B, Pfisterer O, Müller KM, Brasch F. Immunohistochemical localization of vascular endothelial growth factor in colonic mucosa of patients with inflammatory bowel disease. *Hepatogastroenterology*. 2002;49(43):116-23.
- Tsiolakidou G, Koutroubakis IE, Tzardi M, Kouroumalis EA. Increased expression of VEGF and CD146 in patients with inflammatory bowel disease. *Dig Liver Dis*. 2008;40(8): 673-679.
- Tolstanova G, Khomenko T, Deng X, Szabo S, Sandor Z. New molecular mechanisms of the unexpectedly complex role of VEGF in ulcerative colitis. *Biochem Biophys Res Commun*. 2010;399(4):613-6.
- Tolstanova G, Khomenko T, Deng X, Chen L, Tarnawski A, Ahluwalia A, Szabo S, Sandor Z. Neutralizing anti-vascular endothelial growth factor (VEGF) antibody reduces severity of experimental ulcerative colitis in rats: direct evidence for the pathogenic role of VEGF. *J Pharmacol Exp Ther*. 2009;328(3):749-57.
- Pousa ID, Maté J, Salcedo-Mora X, Abreu MT, Moreno-Otero R, Gisbert JP. Role of vascular endothelial growth factor and angiopoietin systems in serum of Crohn's disease patients. *Inflamm Bowel Dis*. 2008;14(1):61-7.