

# Symptomatic Fourth Ventricle Arachnoid Cyst Extending to the Upper Border of the Dens of the Axis: A Case Report and Review of the Literature

Salih Gulsen

*Department of Neurosurgery, Baskent University, Ankara, Turkey*

## Abstract

**Citation:** Gulsen S. Symptomatic Fourth Ventricle Arachnoid Cyst Extending to the Upper Border of the Dens of the Axis: A Case Report and Review of the Literature. *OA Maced J Med Sci*. 2014 Jun 15; 2(2):299-302. <http://dx.doi.org/10.3889/oamjms.2014.050>

**Key words:** Arachnoid cyst; craniocervical junction; fourth ventricle; intraventricular air; posterior fossa.

**Correspondence:** Salih Gulsen, MD. Department of Neurosurgery, Faculty of Medicine, Baskent University Medical Faculty Department of Neurosurgery, Fevzi Cakmak Caddesi 10. Sokak no: 45, Cankaya, Bahcelievler, Ankara 06490. Turkey. Business Phone: 0090 312 212 68 68 /1362. FAX: 0090 3122237333. E.mail: [salihgulsen07@gmail.com](mailto:salihgulsen07@gmail.com)

**Received:** 10-Feb-2014; **Revised:** 12-Mar-2014; **Accepted:** 13-Mar-2014; **Online first:** 11-Apr-2014

**Copyright:** © 2014 Gulsen. This is an open access article distributed under the terms of the Creative Commons Attribution License, which permits unrestricted use, distribution, and reproduction in any medium, provided the original author and source are credited.

**Competing Interests:** The authors have declared that no competing interests exist.

Arachnoid cysts are congenital and non-tumorous intra-arachnoid fluid accumulations that make up about 1% of all intracranial space-occupying lesions. We report a patient with a fourth ventricle arachnoid cyst extending to the upper border of the dens of the axis. This patient progressively developed walking difficulty and stiffness in his legs together with difficulty in grasping objects with his hands within one year. The cyst was totally excised and the patient's symptoms improved in the early postoperative period, but he developed intraventricular and intracisternal air which was followed-up conservatively and resolved spontaneously.

## Introduction

Arachnoid cysts are congenital and non-tumorous intra-arachnoid fluid accumulations that comprise about 1% of all intracranial space-occupying lesions, and are reported to be the most commonly encountered intracranial cysts [1]. Many different locations have been described including the sylvian fissure, suprasellar region, cerebral convexity, quadrigeminal plate and posterior fossa and the peripetrosal region [2, 5]. Asymptomatic arachnoid cysts are followed conservatively with serial neuroimaging studies. Arachnoid cysts are usually diagnosed in the first or second decades of life. Various surgical treatment options have been used in symptomatic patients. We present this case to emphasize the importance of the surgical excision of a

symptomatic arachnoid cyst extending from the fourth ventricle to the upper border of the dens of the axis and the quick improvement.

## Case Report

**History and Presentation:** A sixty-year-old right hand-dominant man was admitted to our hospital for severe walking difficulty and difficulty in grasping objects with his hands. These symptoms had been developed within one year. And, his symptoms had been progressively increased. Moreover, he had not been able to not walk without help and showed clumsiness in daily life due to unsteadiness.

**Neurological examination:** He had negative

Babinski sign on the left but positive on the right. Also, he had increased deep tendon reflexes, symmetrically, and mild spastic quadriparesis. He had intention tremor during the nose-to-finger test, and Romberg test was positive.

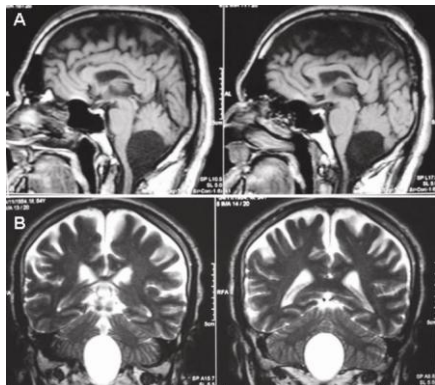


Figure 1a, b: T1-weighted sagittal section and T2-weighted coronal section MRI showed a cyst within the fourth ventricle extending to the craniocervical junction.

**Imaging:** T1-weighted sagittal section and T2-weighted coronal section MRI showed a cyst within the fourth ventricle extending to the craniocervical junction (Fig. 1a, b). T2-weighted axial section MRI showed the pressure effect of the cyst on the spinal cord at the level of the upper border of the axis (Fig. 2). Cranial CT showed air within the ventricular and cisternal systems (Fig. 3a), and control cranial CT showed a decreased amount of air within the same systems (Fig. 3b). Control MRI was performed three months after the surgical operation and showed no pressure effect on the neural structures (Fig. 4a, b).

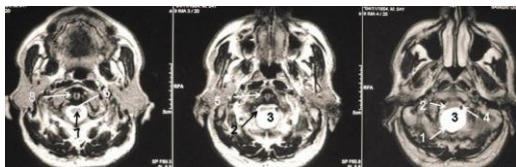


Figure 2: T2-weighted axial section MRI showed the pressure effect of the cyst on the spinal cord at the level of the upper border of the axis. 1-Posterior border of the cyst. 2-The thinned medulla spinalis due to the pressure effect of the arachnoid cyst. 3-The arachnoid cyst at the level of the atlas. 4-Left vertebral artery. 5-Tip of the dens of the axis. 6, 7-Normal appearance of the medulla spinalis at the middle third of the dens of the axis. 8-Middle third of the dens of the axis.

**Operation:** We performed suboccipital craniectomy in the concorde position. Following craniectomy, we opened the duramater with a scalpel in Y shaped. Then, we observed a cystic lesion extended between the cerebellar tonsils and the inferior border of the posterior arcus of the atlas. Microsurgically, we opened and easily dissected this cyst from the arachnoid folds. During the opening period of the cyst, the liquid within the cyst was discharged, and the liquid within the cyst was very similar to cerebrospinal fluid.

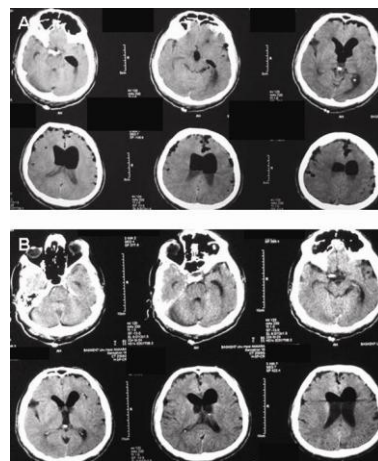


Figure 3a, b: Cranial CT showing air within the ventricular and cisternal systems (Fig 3a), and follow-up cranial CT showing a decreased amount of air within the ventricular and cisternal systems (Fig 3b).

**Postoperative Course:** We transferred the patient from the operation room to the intensive care unit. He had no complaints and was fully conscious and extubated. He was transferred to the ward but developed a headache the day after the surgery. Computerized brain tomography showed intraventricular and intracisternal air (Fig. 3a). No intervention was planned and follow-up tomography 4 days after the first postoperative tomography showed diminished air within the ventricles and cisterns (Fig. 3b). The patient was discharged on the tenth postoperative day in better clinical condition. We examined him three months later of the operation and showed no Babinski sign and Romberg sign. He could walk unaided, and he stated that he could grasp objects better than in the preoperative period.

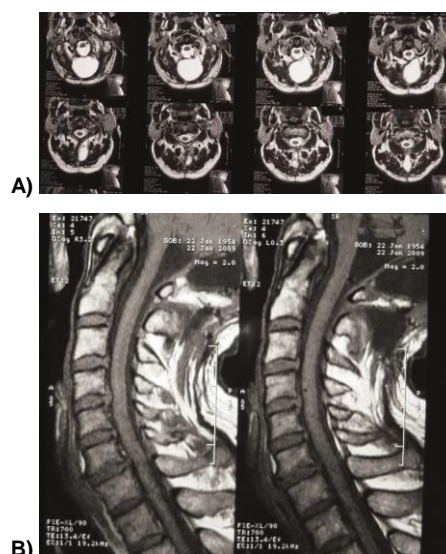


Figure 4: A) T2-weighted axial section MRI performed three months after postoperative period. It shows complete relieving and no pressure effect on the medulla spinalis. In addition, cerebrospinal fluid collection was seen, but it had no any clinical consequences. B) T1-weighted sagittal section MRI performed after three months of the operation. It shows no cyst.

## Discussion

Asymptomatic arachnoid cysts can be followed conservatively, but they should be treated surgically whenever these cysts cause progressive symptoms and new symptoms and signs, such as epileptic seizure, ataxia or hydrocephalus due to pressure effects [1, 6-9]. Moreover, asymptomatic cysts can be followed up at between 6 and 12 months intervals with computerized tomography or magnetic resonance imaging of the brain [1, 6, 9]. However, any arachnoid cyst that shows a mass effect but causes no symptoms should be treated surgically to prevent possible devastating complications including intracystic hemorrhage and cyst rupture [10, 11]. An arachnoid cyst can be located in the anterior fossa, middle fossa, sylvian cistern, perimesencephalic cistern, cortical surfaces, suprasellar region, quadrigeminal cistern, posterior fossa, or craniocervical junction [1, 2, 5, 12, 13]. Essentially, there are two types of arachnoid cyst. The first type is the congenital or primary arachnoid cyst, and it is seen more frequently than a secondary arachnoid cyst. A secondary cyst is derived from various pathologies such as an inflammatory or traumatic process, intracranial bleeding, chemical irradiation and tumors [1, 5, 6] and should be differentiated from a congenital or primary cyst. Some congenital arachnoid cysts may have a capacity to enlarge, and eventually to cause pressure on brain tissue. They may also cause some symptoms and signs associated with the location of the cyst including seizure, walking difficulty, hemiparesis, headache, vomiting, endocrine disorders, upward gaze limitation, visual loss, hydrocephalus, syringomyelia, presyrinx myelopathy and third cranial nerve palsy [7, 14, 15]. Various surgical methods have been used to treat arachnoid cysts, including evacuation of the liquid content and microsurgical excision of the cyst. The other option is to create a communication hole to provide flow of liquid between the cyst and the anatomic cisterns. Cystoperitoneal shunting and stereotactic intracavitary irradiation are also among the surgical options [6, 7, 10, 11, 16, 17]. Arachnoid cyst surgery has some risks. The brain tissue located beneath the cyst may bleed after the evacuation, and intraparenchymal brain hemorrhage may occur, but it is seen rarely [1, 6]. Microsurgical excision of the Galassi types II and III arachnoid cysts may result in subdural hematoma [1, 6, 13]. A case of brain stem hemorrhage was reported after the evacuation of a sylvian fissure arachnoid cyst [18]. Complications and treatment choices have not been reported extensively due to the rarity of arachnoid cysts extending from the fourth ventricle to the craniocervical junction in contrast to anterior and middle fossa arachnoid cysts. Bonde et al reported four cases of arachnoid cyst located within the fourth ventricle. They performed total cyst excision in one case and partial cyst excision in three cases in which they performed ventriculoperitoneal shunting. They concluded that a fourth ventricle arachnoid cyst causing hydrocephalus

should be differentiated from a communicating hydrocephalus as patients with a fourth ventricle arachnoid cyst will not benefit from ventriculoperitoneal shunting without cyst excision [19]. Korouse and associates reported a case of arachnoid cyst of the fourth ventricle causing normal pressure hydrocephalus. They performed ventriculoperitoneal shunting and the posterior fossa arachnoid cyst was excised and evacuated totally via suboccipital craniectomy 15 days later. Ventriculoperitoneal shunting improved the clinical state except for gait ataxia in this case. The gait ataxia improved after cyst excision [20].

Arachnoid cysts located in the craniocervical junction have also been reported. There have been 12 cases reported by different authors including our presented case. The common point of these cases is that they did not need a ventriculoperitoneal shunt procedure except one case in which a cystoperitoneal shunt was performed [21-27]. Different surgical techniques such as a neuroendoscopic approach were used on these patients with an arachnoid cyst located in the fourth ventricle [28]. Acar et al reported a case of fourth ventricle arachnoid cyst. They also performed total cyst excision, but their patient was lost due to a cerebral stroke on the 19th postoperative day [29]. The current literature states the main approach in symptomatic fourth ventricle arachnoid cysts and craniocervical junction cysts as the excision of the cyst totally through suboccipital craniectomy as much as possible in all cases. Cystoperitoneal shunting alone or ventriculoperitoneal shunting with partial excision and marsupialization of the cyst have also been performed for the treatment of fourth ventricle arachnoid cysts and craniocervical junction arachnoid cysts. Ventriculoperitoneal shunting has been performed in cases of arachnoid cysts located in the fourth ventricle, but patient symptoms have not improved. A second operation was performed for patients during which the liquid content of the cyst was evacuated and cyst walls were excised. The patients' clinical condition improved after the cyst excision [19-21]. Nomura and associates have reported successful management of a complicated posterior fossa arachnoid cyst case via endoscopic fenestration [30]. Our presented case had an arachnoid cyst extending from the fourth ventricle to the upper border of the dens of the axis. We think that there is still not enough information collected regarding the management and postoperative complications of arachnoid cysts extending from the fourth ventricle to the craniocervical junction. Cyst evacuation and excision of the cyst walls as much as possible should be performed to relieve patient symptoms according to the literature [19-21]. The reports associated with posterior fossa arachnoid cysts do not mention the patient position during suboccipital craniectomy and also the presence of any postoperative intracranial air. The sitting position may cause abundant cerebrospinal fluid to escape and air passing into the cranium after excision of the posterior

fossa cyst. Suboccipital craniectomy should therefore be performed in the Concorde position to decrease air passage into the cranium. In our presented case, we performed suboccipital craniectomy and also total cyst excision with the patient in the Concorde position. We did not choose to perform ventriculoperitoneal shunting due to the lack of hydrocephalus. We think that the Concorde position caused less intracranial air than the sitting position, and it provided better comfort in the postoperative period. The cranial computerized tomography performed in the first postoperative day due to the patient's headache showed air within the ventricular and cisternal systems (Fig. 3a). The air resolved over time and the follow-up computerized cranial tomography on the postoperative 4th day showed a decreased amount of air within the cisterns and ventricles (Fig. 3b). The patient's headache also resolved. Our patient's symptoms and signs improved and the difficulty walking and grasping objects decreased compared to the preoperative period. A follow-up craniocervical MRI performed two months later showed no cyst residue and no pressure effect on the neural structures.

In conclusion, symptomatic fourth ventricle arachnoid cysts extending into upper border of the dens of the axis should be treated surgically rather than conservatively. Suboccipital craniectomy should be performed to excise the arachnoid cyst and the cyst walls should be dissected and excised as much as possible. A ventriculoperitoneal shunt should not be thought as the first step treatment choice. If the patient has continuing hydrocephalus and does not respond well to cyst excision, a shunt procedure should be thought as the second step treatment choice.

## References

1. Al-Holou WN, Terman S, Kilburg C, Garton HJ, Muraszko KM, Maher CO. Prevalence and natural history of arachnoid cysts in adults. *J Neurosurg*. 2013;118(2):222-31.
2. Aicardi J, Bauman F. Supratentorial extra-cerebral cysts in infants and children. *J Neurol Neurosurg Psychiatry*. 1975;38:57-68.
3. Boutarbouch M, El Ouahabi A, Rifi L, Arkha Y, Derraz S, El Khamlichi A. Management of intracranial arachnoid cysts: institutional experience with initial 32 cases and review of the literature. *Clin Neurol Neurosurg*. 2008;110:1-7.
4. Cristobal R, Oghalai JS. Peripetrosal arachnoid cysts. *Curr Opin Otolaryngol Head Neck Surg*. 2007;15:323-29.
5. Gandy SE, Heier LA. Clinical and magnetic resonance features of primary intracranial arachnoid cysts. *Ann Neurol*. 1987; 21:342-48.
6. Cincu RA, Agrawal AB, Eiras J. A Intracranial arachnoid cysts: Current concepts and treatment alternatives. *Clin Neurol Neurosurg*. 2007;109: 837-43.
7. Thompson TP, Lunsford LD, Kondziolka D. Successful management of sellar and suprasellar arachnoid cysts with stereotactic intracavitary irradiation: an expanded report of four cases. *Neurosurgery*. 2000;46(6):1518-23.
8. Shukla R, Sharma A, Vatsal DK. Posterior fossa arachnoid cyst presenting as high cervical cord compression. *Br J Neurosurg*. 1998; 12:271-3.
9. Cokluk C, Senel A, Celik F, Ergur H. Spontaneous disappearance of two asymptomatic arachnoid cysts in two different locations. *Minim Invasive Neurosurg*. 2003; 46:110-2.
10. Geissinger JD, Kohler WC, Robinson BW, Davis FM. Arachnoid cysts of the middle cranial fossa: surgical considerations. *Surg Neurol*. 1978;10:27-33.
11. La Cour F, Trevor R, Carey M. Arachnoid cysts and associated subdural hematoma: Observations on conventional roentgenographic and computerized tomographic diagnosis. *Arch Neurol*. 1978;35: 84-9.
12. Daneyemez M, Gezen F, Akboru M, Sirin S, Ocal E. Presentation and management of supratentorial and infratentorial arachnoid cysts. Review of 25 cases. *J Neurosurg Sci*. 1999;43:115-23.
13. Galassi E, Tognetti F, Gaist G, Fagioli L, Frank F, Frank G. CT scan and metrizamide CT cisternography in arachnoid cysts of the middle cranial fossa: classification and pathophysiological aspects. *Surg Neurol*. 1982; 17:363-69.
14. Ashker L, Weinstein JM, Dias M, Kanev P, Nguyen D, Bonsall DJ. Arachnoid Cyst Causing Third Cranial Nerve Palsy Manifesting as Isolated Internal Ophthalmoplegia and Iris Cholinergic Supersensitivity. *J Neuroophthalmol*. 2008;28:192-7.
15. Martinez-Lage JF, Poza M, Sola J, Puche A. Congenital arachnoid cyst of the lateral ventricles in children. *Childs Nerv Syst*. 1992;8:203-6.
16. Aggouri M, Boujraf SA, Benzagmout M, Chaoui ME. Arachnoid cyst of the posterior fossa. *Neurosciences (Riyadh)*. 2010;15(4):277-9.
17. Yamashita T, Hiramatsu H, Kitahama Y, Tokuyama T, Sugiyama K, Namba H. Disproportionately large communicating fourth ventricle associated with syringomyelia and intradural arachnoid cyst in the spinal cord successfully treated with additional shunting. *Case report. Neurol Med Chir (Tokyo)*. 2012;52(4):231-4.
18. Mori H, Terabayashi T, Kitazawa T, Sugiyama Y. Multiple intracerebral hemorrhages immediately after surgical excision of middle fossa arachnoid cysts and evacuation of chronic subdural hygroma. *Case report. Neurol Med Chir (Tokyo)*. 1989;29:142-5.
19. Bonde V, Muzumdar D, Goel A: Fourth ventricle arachnoid cyst. *J Clin Neurosci*. 2008;15 26-8.
20. Korosue K, Tamaki N, Fujiwara K, Matsumoto S. Arachnoid cyst of the fourth ventricle manifesting normal pressure hydrocephalus. *Neurosurg*. 1983;12:108-10.
21. Bhatia S, Thakur RC, Radotra BD, Kak VK. Craniospinal intradural arachnoid cyst. *Postgrad Med J*. 1992; 68:829-30.
22. Cakirer S. Arachnoid cyst of the craniospinal junction: a case report and review of the literature. *Acta Radiol*. 2004; 45:460-3.
23. Fukushima Y, Sato M, Taguchi J, Sasaki M, Kanai N, Hayakawa T. Craniospinal arachnoid cyst: case report. *No Shinkei Geka*. 1996; 24:75-9.
24. Kuroiwa T, Takeuchi E, Yamada K, Ohta T, Miyaji Y, Onomura T. An intradural arachnoid cyst of the craniovertebral junction; a case report. *No Shinkei Geka*. 1991;19:1097.
25. Kutlay M, Colak A, Demircan N, Akin O. Craniocervical junction arachnoid cyst causing hydrocephalus: case report and review of the literature. *Mil Med*. 2007;172:66-72.
26. Price SJ, David KM, O'Donovan DG, Aspoas AR. Arachnoid cyst of the craniocervical junction: case report. *Neurosurgery*. 2001; 49:212-5.
27. Khan IS, Ahmed O, Thakur JD, Shorter CD, Guthikonda B. Craniocervical arachnoid cyst in a patient with Klippel-Feil syndrome: a unique case. *J Neurosurg Spine*. 2013;18(2):161-4.
28. Schroeder HWS, Gaab MR, Niendorf WR. Neuroendoscopic approach to arachnoid cysts. *J Neurosurg*. 1996; 85:293-8.
29. Acar O, Kocaogullar Y, Guney O. Arachnoid cyst within the fourth ventricle: a case report. *Clin Neurol Neurosurg*. 2003;105:93-4.
30. Nomura S, Akimura T, Imoto H, Nishizaki T, Suzuki M. Endoscopic fenestration of posterior fossa arachnoid cyst for the treatment of presyrinx myelopathy. *Case report. Neurol Med Chir (Tokyo)*. 2002;42:452-4.