

Case Report

DUPLICATION OF FEMORAL VEIN AND ITS CLINICAL SIGNIFICANCE

Deepali Onkar ^{*1}, Prashant Onkar ².

^{*1} Associate Professor Anatomy, ² Associate Professor Radiodiagnosis.

NKP Salve Institute of Medical Sciences and Research Centre, Hingna road, Nagpur, India.

ABSTRACT

Variations seen in the femoral vein include duplication or multiple veins. We came across a case of femoral vein variation during dissection for undergraduates. There was bilateral duplication of femoral vein in the adductor canal. The presence of femoral vein duplication has potential influence on misdiagnosis of deep venous thrombosis by duplex ultrasound scanning. Femoral veins are also suitable vascular substitutes in infected prosthetic grafts and in infra-inguinal bypass surgery.

KEY WORDS: Femoral vein duplication, Deep vein thrombosis, Vascular substitute, Duplex scanning, Doppler.

Address for Correspondence: Dr. Deepali Onkar, Associate Professor Anatomy, NKP Salve Institute of Medical Sciences and Research Centre, Hingna road, Nagpur, India. 440019
Ph No.: +91-712-2248590, +91-9822248570. **E-Mail:** drdeepalionkar@yahoo.com

Access this Article online

Quick Response code



DOI: 10.16965/ijar.2015.189

Web site: International Journal of Anatomy and Research
ISSN 2321-4287
www.ijmhr.org/ijar.htm

Received: 28 May 2015 Accepted: 15 Jun 2015
Peer Review: 28 May 2015 Published (O): 30 Jun 2015
Revised: None Published (P): 30 Jun 2015

INTRODUCTION

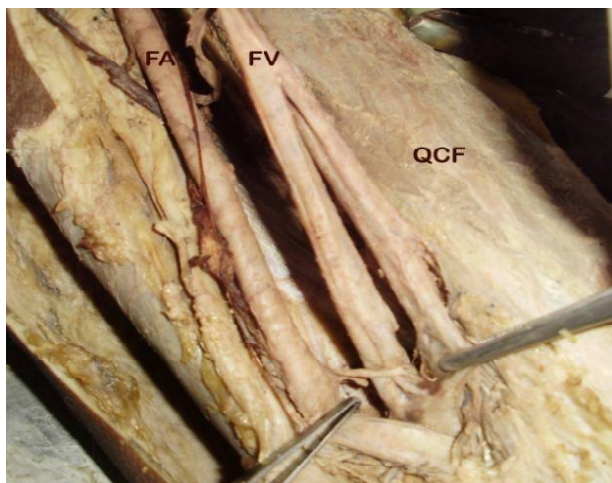
The femoral vein accompanies the femoral artery. It begins at the adductor opening as the continuation of the popliteal vein and ends posterior to the inguinal ligament as external iliac vein [1]. Variations in the anatomy of the lower limb veins have been studied with use of cadavers, venography and recently with duplex ultrasound. Duplex ultrasound has evolved as a primary method of studying peripheral veins and has replaced venography [2]. The individual with duplication of femoral vein are more prone to deep venous thrombosis. Moreover many of them are asymptomatic due to collateral drainage. There can be potential misdiagnosis of deep venous thrombosis in cases of femoral vein duplication [3]. Femoral vein assessment is also important in central line placement and can be used for iliac substitution [4]. Therefore knowledge of anatomical patterns of variations of femoral vein is necessary.

CASE REPORT

While conducting dissection for undergraduate students we came across the case of bilateral femoral vein duplication in formaldehyde preserved adult male cadaver in the department of anatomy.

The femoral vein in adductor canal was duplicated at a distance of 2 cm from adductor hiatus in both lower limbs. The components of duplicated vein in either limb were lateral to the femoral artery. They joined at the upper part of the adductor canal to form a single femoral vein. Length of components was 9 cm and 6 cm on the left and right side respectively. The diameters of the components were equal (Fig.1, 2). The single femoral vein received great saphenous vein around 2.5 cm below inguinal ligament and was medial to the femoral artery at the level of inguinal ligament.

Fig. 1: Showing duplicated femoral vein on left side.



FV- femoral vein, FA- femoral artery, QCF- Quadriceps femoris

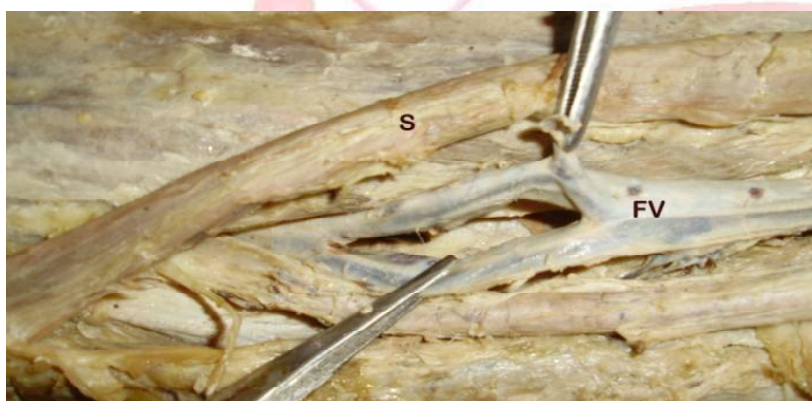

Fig. 2: Showing duplicated femoral vein on right side.

FV- femoral vein, S-Sartorius

DISCUSSION AND CONCLUSION

Femoral vein is the continuation of popliteal vein. In the literature cited the term 'superficial femoral vein' is used to define femoral vein and 'deep femoral vein' is used to define profunda femoris vein by radiologists and vascular surgeons. Since the femoral vein is involved in deep vein thrombosis the term superficial femoral vein is misleading and should be replaced by femoral vein. The term used by anatomists is as per international interdisciplinary consensus committee [5].

Venographic study has demonstrated that most of the duplicated femoral veins arise at the adductor canal or just above it in mid thigh region. There is an equal chance of lying medial and lateral to the main vein. Only 4 % of duplicated vessels are of same size as the native vessel. They observed duplicated femoral veins in 31% and complex duplicated system in 1.5% cases. The length of duplicated segment varied from 1-35 cm. The presence of multiple vessels in one leg was strongly correlated with the probability of occurrence in the other leg [6].

Another study conducted by duplex ultrasound observed that the femoral vein is most commonly duplicated involving its middle part. They found that in 15% of patients there was a duplicated segment and venous thrombus in the same limb [7].

Higher proportion of thrombosis in duplicated veins can be explained by an increased blood volume in the venous pool, resulting in slower flow rate leading to formation of thrombus. Similarly high occurrence of asymptomatic deep venous thrombosis in patients with duplicated veins can be explained by the presence of collateral channels provided by the accessory veins [3].

Femoral veins have been widely used as vascular substitute. Femoral vein has been the first choice of substitute for in situ reconstruction of the aortoiliac tree when prosthetic infection is present. Accessory femoral veins with diameters superior to 6 mm are commonly used for iliac substitution [4].

Femoral vein can also be used as a substitute in infra-inguinal bypass surgery when the conventional options are unavailable or infection is present [8].

Theoretically, main femoral vein harvesting for use as a substitute would be more tolerated in patients with duplicated systems, as venous flow originating from leg veins would naturally be redirected to accessory femoral veins [4].

It is therefore important to rule out femoral vein duplications while doing duplex ultrasound examination for suspected femoral vein thrombosis and duplication should be looked for when venous substitutes are required for arterial reconstruction.

Conflicts of Interests: None

REFERENCES

- [1]. Mahadevan V. Pelvic girdle and lower limbs. In: Gray's anatomy. 40th Ed. Edited by Standring S. Churchill Livingstone; 2008:1381.
- [2]. Screamon NJ, Gillard JH, Berman LH, Kemp PM. Duplicated superficial femoral veins: a source of error in the sonographic investigation of deep vein thrombosis. *Radiology* 1998;206:397-401.
- [3]. Liu GC, Ferris EJ, Reifsteck JR, Baker ME: Effect of anatomic variations on deep venous thrombosis of the lower extremity. *Am J Roentgenol* 1986;146:845-848.
- [4]. Casella IB, Presti C, Yamazaki Y, Vassoler AA, Furuya LA, Sabbag CD. A duplex scan-based morphologic study of femoral vein: Incidence and patterns of duplication. *Vascular Medicine* 2010;15(3):197.
- [5]. Caggiati A, Bergan JJ, Gloviczki P, Jantet G, Wendell-Smith CP, Partsch H. Nomenclature of the veins of the lower limbs. an international interdisciplinary consensus statement. *J Vasc Surg* 2002;36:416–422.
- [6]. Quinlan DJ, Alikhan R, Gishen P, Sidhu PS. Variations in lower limb venous anatomy: Implications for US diagnosis of deep vein thrombosis. *Radiology* 2003;228:443-448.
- [7]. Simpson WL, Krakowski DM. Prevalence of lower extremity venous duplication. *Indian J Radiol Imaging* 2010;20:230-234.
- [8]. Wozniak G, Gortz H, Akinturk H, Dapper F, Hehrlein F, Alemany J. Superficial femoral vein in arterial reconstruction for limb salvage: outcome and fate of venous circulation. *J Cardiovasc Surg (Torino)* 1998;39:405-41ne1.

How to cite this article:

Deepali Onkar, Prashant Onkar. DUPLICATION OF FEMORAL VEIN AND ITS CLINICAL SIGNIFICANCE. *Int J Anat Res* 2015;3(2):1162-1164. **DOI:** 10.16965/ijar.2015.189