

DESIGNING A CONTEMPORARY ANATOMY MUSEUM: ANATOMISTS' PERSPECTIVE

Venkatesh. G. Kamath ^{*1}, Biswabina. Ray ², Shakuntala R. Pai ³, Ramakrishna Avadhani ⁴.

^{*1} Assistant Professor, Department of Anatomy, Yenepoya Medical College, Mangalore, India.

² Professor and Head, Department of Anatomy, ESICMC-PGIMSR, Bangalore, India.

³ Professor and Head, Department of Anatomy, Srinivas Institute of Medical Sciences, Mangalore, India.

⁴ Professor and Head, Department of Anatomy, Yenepoya Medical College, Mangalore, India.

ABSTRACT

Background: A research study was conducted in sixteen anatomy museums across India.

Aim: The aim of the study is to have an integrated approach while designing a museum.

Objective: The objective is to stress on the need to have a holistic approach while designing a museum so that that the museum is well planned and organised and has a huge sectional diversity that spans all aspects related to anatomy.

Materials and Methods: All the museums were studied using a planned proforma that emphasised on special features of the museum with special emphasis on sectional variety.

Observations: The various techniques of specimen preparation, preservation, mounting and display were observed and photographed. The sectional variety was noted. Moreover the various methods of maintaining specimen related information in pictorial and computerised catalogues was observed.

Results and Conclusion: A design of a contemporary anatomy museum can now be conceived that incorporates all aspects of anatomy from history, evolution, embryology, cross-sectional anatomy, comparative anatomy, teratology, genetics and clinical anatomy to sections with modern techniques like plastination. Such a museum will certainly have a more holistic approach to anatomy and will be more educative and scientific.

KEY WORDS: Mouseion, Models, Mummies, Plastinates, Embryology Section, History Of Anatomy.

Address for Correspondence: Dr. Venkatesh G. Kamath, M.B.B.S., M. D. Anatomy, Assistant Professor, Department of Anatomy, Yenepoya Medical College, Mangalore, Karnataka, India.

E-Mail: drvenkateshkamath@gmail.com

Access this Article online

Quick Response code



DOI: 10.16965/ijar.2015.158

Web site: International Journal of Anatomy and Research
ISSN 2321-4287
www.ijmhr.org/ijar.htm

Received: 15 Apr 2015

Accepted: 05 May 2015

Peer Review: 15 Apr 2015

Published (O): 31 May 2015

Revised: None

Published (P): 30 June 2015

INTRODUCTION

The word museum is derived from the Greek word "mouseion" which means "seat of the Muses" (Muses are the patron divinities in Greek mythology of the arts) and hence a building set apart for the study and display of the arts [1]. Anatomy is a science that can only be studied by dissections, specimen preparation and preservation. Early anatomists therefore promo-

-ted the establishment of anatomy museums and at present it is mandatory for every medical college to have a museum.

Early anatomy flourished in Italy between 1300A.D. to 1500A.D. A manual of anatomic dissection was written, printed and published for the first time by Mondino de'Liuzzi [2]. Leonardo da Vinci (1452-1519) and Michelangelo (1475-1564) were the renowned

artists of the fifteenth century. Michelangelo performed public dissections in his early teens and by the age of eighteen performed his own dissections as is depicted in the article "Michelangelo: art, anatomy and the kidney" [3]. Early neuroanatomical structures and techniques were first depicted in a book called "Anathomia" which displays six plates showing meninges, cerebrum, spinal cord and ventricles [4].

THE ORIGIN OF A NEW CONCEPT OF ANATOMY

MUSEUM: Between the years 1699 to 1763 the Surgeons of Edinburg determined to create a collection of anatomical specimens, pictures and books which was called the "cabinet of curiosities" [5].

Early museums mainly consisted of models, artistic sketches and paintings. Between 1789 and 1815 wax models made by the renowned modeler Clemente Susini were acclaimed worldwide [6]. The museum of anatomical waxes at the University of Cagliari, Sardinia, Italy houses some of the best models prepared by this 18th century modeler who made over 2000 models during his career based on the dissections made by the anatomist Francesco Antonio Boi [7]. The famous artist Fabricius had painted over 300 paintings by 1600 and made the "Tabulae Pictae" a famous atlas of anatomy. La Specola Collection in Florence which has the greatest collection of anatomical wax models was built in the year 1775. The models have been distinguished for their true to life appearance and each piece is a perfect blend of art and science. These models were prepared by the Dutch anatomist, Bernard Siegfried Albinus (1697-1770) and Jan Wanderlaer (1690-1759), his artist and engraver [8]. The article "Role of anatomy in our contemporary age and the history of the anatomy museum of Naples by Esposito et al, describes the anatomy museum in Naples as an academic place founded under the guidance of the renowned surgeon and anatomist Marco Aurelio Severino and is one of the ancient museums [9].

As science developed, formalin was discovered in the mid nineteenth century. Though the aldehyde was first reported by a Russian chemist Alexander Michailovich Butlerov in 1859 it was

conclusively identified in 1868 by a German chemist August Wilhelm Von Hoffmann. The article "Capital punishment and anatomy: history and ethics of an ongoing association" by Hildebrandt S. describes how bodies of executed criminals were the only source of bodies for dissection from thirteenth to early seventeenth century [10]. In late seventeenth century unclaimed bodies were made available for dissection in some countries. In nineteenth century the British system renounced the practice of use of bodies of executed people. However by 1913, "Anatomy Laws", were passed in America and also in London allowing unclaimed bodies to be consigned to medical schools for dissection[11]. The museums now witnessed a transition from an institute housing a collection of models and artistic sketches, to one housing wet formalin preserved specimens, corrosion casts and finally plastinates. The contemporary museums have sophisticated interiors, display, lightings and use computerised catalogues and audio-visual aids to teach anatomy.

In the history of anatomy we witness first an era of model making and artistic sketches till the mid-nineteenth century, followed by an era of specimen preservation as formalin was invented and the anatomy laws were passed. The discovery of carcinogenic effects of formalin was followed by attempts at dry preservation and thus followed a new era of dry preservation with corrosion casts that culminated in plastination.

This article is a study of sixteen modern day museums. The aim here is to create a museum which is not focussed only on the gross specimens as it is seen in most of the museums, but instead on all the aspects of anatomy like history, evolution, embryology, genetics, cross-sectional anatomy, comparative anatomy etc. The authors believe that this would be a more holistic approach and such museums will be more educative.

MATERIALS AND METHODS

Written consent was obtained for study and photography from all the museums from the college authorities.

Sample selection was such that even both museums with a history of over fifty years and those that were built in the present decade were considered.

All aspects of a museum were studied in detail using the following proforma.

PROFORMA

Name of the Museum:

Name of the Medical College:

Location:

Total number of visitors per day:

Target population: Academic, public or both

History of Museum: - Year of opening, Founder & significant contributors

Area of the Museum: Area _____ in sq.m

Other rooms: 1) Preparation room—Area 2)

Storage room—Area 3) Artist room—Area.

Total No of staff:

Total no of specimens:

Specimen preparation method:

Method of preservation of specimens:

Method of display of specimens:

Method of museum care:

Whether any of the following sections are present:

1) Comparative anatomy section 2) Evolutionary anatomy 3) Section on history of anatomy 4) Biomechanics 5) Mummies 6) Plastinated specimens 7) Embryology section. 8) Crosssectional anatomy section 9) Histology 10) Normal specimens correlated with pathology specimens. 11) Special osteology section 12) Section on odontology. 13) Section on teratology. 14) Section on clinical anatomy. 15) Other innovative sections.

Application of computer software in the museum
Whether any computer software is used in the museum:

If yes any anatomy related software available & if yes source:

Pictorial catalogues if stored in computer for access to students:

Presence of informative catalogues about individual specimens:

Models: 1) Total no of gross anatomy models b)

Total no of embryology models c) Material used for models:

Mummies:

Radiology display:

1) X-Rays present / absent

2) C-T-Scans present / absent 3) MRI present / absent 4) Angiograms present / absent

Osteology:

1) Total number of bones 2) Method of bone preparation used 3) Method of display 4) Any special stains like alizarin used 5) Any embryological skeletons present

Newer methods of preservation of specimens like plastination: present/ absent

If present: -1. Total number of plastinated specimens 2. Technique of plastination A) Luminal plastination B) Sheet plastination C) Whole organ plastination 3. Region of body plastinated

Special attractive features that make the museum unique or innovative features

Future plans:

OBSERVATIONS

REGULAR SECTIONS

The formalin fixed specimens were arranged in six sections:

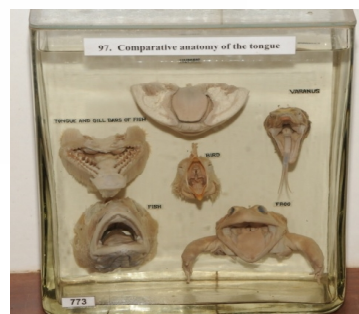1. Thorax
2. Abdomen and pelvis
3. Upper extremities
4. Lower extremities
5. Head & Neck
6. Neuroanatomy

These seven sections were present in all the museums.

SPECIAL SECTIONS

COMPARATIVE ANATOMY: In this section the anatomy of human species is compared with that of other species. This is an interesting method of expressing and understanding anatomy and also helps to understand the evolution of species. Any one anatomical structure can be compared in different species or even osteology of species can be compared. An example is shown in figure 1 where comparative anatomy of tongue is shown and in figure 2 which shows comparative osteology.

Fig. 1: Comparative Anatomy of Tongue.



Courtesy Kasturba Medical College Anatomy Museum, Manipal, Karnataka, India.

Fig. 2: Comparative Osteology Section.

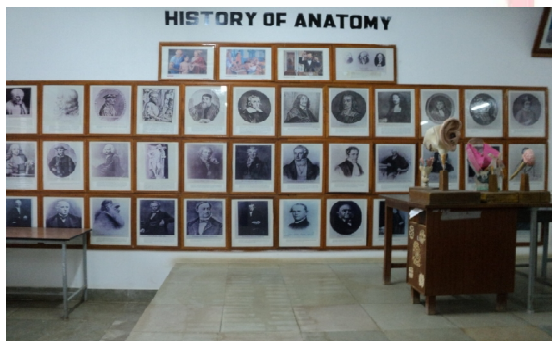

Courtesy Kasturba Medical College Anatomy Museum, Manipal, Karnataka, India.

EVOLUTIONARY ANATOMY: This section describes the process of evolution of species over the centuries. This was shown using pictures and artistic sketches. It is possible to improve this section using audio-visual aids and projectors that project videos on evolution and softwares explaining evolution to students. These explanations can also be transferred on to pen drives and I-pods and be seen later by the students.

HISTORY OF ANATOMY: The section describes the eminent anatomists who significantly contributed to the development of anatomical science. The section consists of portraits of anatomists as shown in figure 3 and can be used to pay tribute to the legendary scientists. Information regarding the problems faced by the early anatomists, the contributions of Michelangelo and Leonardo da Vinci and eminent modellers, the discovery of formalin, earlier grave robberies and implementation of anatomy laws and other significant chapters in anatomical history can be described in this section using artistic sketches or audio-visual aids.

Fig. 3: History of Anatomy Section Showing Eminent Anatomists.



Courtesy Anatomy museum of Devaraj Urs Medical College, Kolar, Karnataka, India.

EMBRYOLOGY SECTION: The embryological changes in the developing foetus can be expressed using models, sketches and specimens of embryo at various stages of development as shown in figure 4. The section can be improvised using relevant audio-visual aids and projector presentations and information related to embryogenesis can be typed beside the specimen or alternatively it can be stored in hard drives that that can be accessed by students. A computer section can be created within the museum for this purpose where students can learn and visiting the museum should be made mandatory for students by incorporating it as a part of their curricular assessment.

Fig. 4: Embryology Section: Section Shows Foetuses at Various Stages of Gestation.



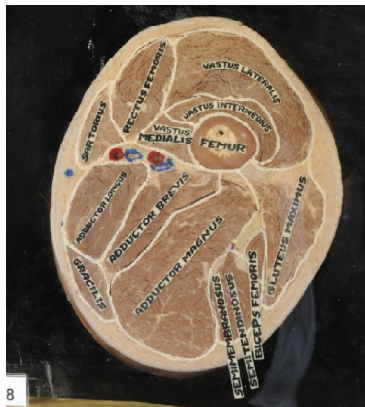Courtesy Kasturba Medical College Anatomy Museum, Manipal, Karnataka, India.

BIOMECHANICS: The physiological functions of various parts like heart, kidney and the lungs can be expressed using biomechanical models. This will help in better understanding of the subject. However preparing accurate and effective models involves active participation of anatomists, physiologists and technicians.

CROSS SECTIONAL ANATOMY: A section exhibiting cross sectional anatomy makes the museum more informative. Several cross sections at clinically important levels can be shown and these specimens can be compared with M.R.I and C. T. Scans at these levels. A cross section at the level of apex of femoral triangle is shown in figure 5.

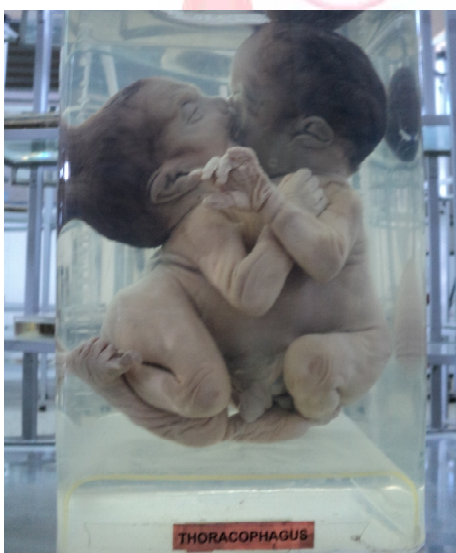TERATOLOGY SECTION: Teratology is the science that deals with various developmental anomalies. In this section various developmental anomalies such as spina bifida, anencephaly and thoracophagus can be exhibited as shown in figure 6.

Fig. 5: Crosssectional Anatomy of Thigh.



Section at the level of apex of femoral triangle.
Courtesy Kasturba Medical College Anatomy Museum, Manipal, Karnataka, India.

Fig. 6: Teratology section showing embryological defects and abnormalities.



Courtesy St. John's Medical College Anatomy Museum, Bangalore, Karnataka, India.

SECTION ON ODONTOLOGY: Odontology is a science that deals with teeth. A section on odontology can also be included in the museum.

SECTION ON GENETICS: In this section chromosome structure and genetic anomalies can be explained using charts and pictures. Models of D.N.A. structure and chromosomes can be prepared. Pictures showing genetic defects like Downs and Turners syndrome can be shown.

SECTION ON CLINICAL OR APPLIED OR PATHOLOGICAL ANATOMY: In this section normal and clinical anatomy of each specimen can be shown side by side. Example a specimen of normal uterus and fibroid uterus or normal stomach mucosa with a mucosa showing chronic peptic ulcer etc can be exhibited as this will facilitate a better understanding of the subject.

MUMMIES: Mummies of animals like deer, crocodile, snakes and mummies of humans can be added to make the museum more interesting to the visitors as shown in figure 7.

Fig. 7: A Mummy Section Makes the Museum More Attractive.



Courtesy Kasturba Medical College Anatomy Museum, Manipal, Karnataka, India.

OSTEOLOGY SECTION: In this section both the adult and foetal bones can be displayed. Alizarin stained foetal skeletons can also be displayed as shown in figure 8.

Fig. 8: Osteology Section with Alizarin Stained Embryology Specimens. Alizarin Stained Chick Embryo is Shown.

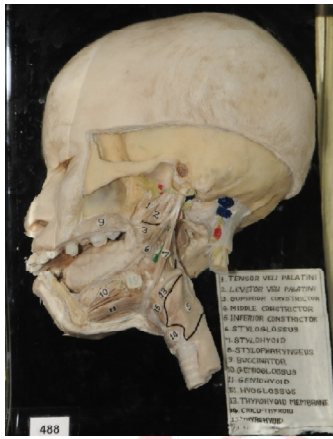

Courtesy Kasturba Medical College Anatomy Museum, Mangalore, Karnataka, India.

RADIOLOGY SECTION: X-rays, C-T scans, M.R.I.'s and Angiograms can be shown. Normal radiographs can be compared with abnormal ones and some literature related to the features seen in the radiographs can be documented along with it for the visitors.


PLASTINATION: Plastinated specimens of whole organs, body parts, luminal plastinates and sheet plastinates can be prepared. However

Fig. 9: A Well Dissected and Labelled Specimen.



Courtesy Kasturba Medical College Anatomy Museum, Manipal, Karnataka, India.

Fig. 10: Pictorial Catalogues That Describe the Specimens.



Courtesy Kasturba Medical College Anatomy Museum, Manipal, Karnataka, India.

preparing high quality plastinates involves a lot of expenditure.

SECTION FOR LEARNING: This can be created within the museum where arrangements can be made inside the museum for teaching students and for accessing all the information related to these sections in computers. The computer hardware should be regularly updated with the latest developments in anatomy. Three dimensional viewing is also possible these days using appropriate software. The computers should contain photographs of all the specimens, radiographs, sketches, pictures and models related information. Videos and power points prepared by appropriate faculty regarding important aspects of anatomy can also be stored in the computer. Such an information can be transferred to I pods and pen drives which the students can access later at their leisure. Such a digitalisation of museum certainly makes the museum more accessible and useful to the medical students.

DISCUSSION

The visit to the sixteen museums provided a great deal of information regarding museum layout, architecture, specimen preparation & preservation techniques, display, sectional arrangement and museum maintenance. Every museum was distinct and the methods of arrangement of specimens and models and their display varied considerably. It was observed that the medical institutes were giving more emphasis to establishing good anatomy museums.

A well equipped academic museum must have arrangement for medical students to sit and study, with tables, chairs, teaching boards and computers while observing the specimens. It must be designed such that the faculty can take lectures in the museum and simultaneously demonstrate the specimens.

The specimens must be dissected with great care and the entire process of specimen preparation, preservation, mounting and labelling must be done with artistic hands. A well dissected and labelled specimen is shown in figure 9.

The use of good pictorial catalogues in one of the museums is shown in figure 10. However, it is observed that several modern museums are now using computer based pictorial catalogues for educating the visitors. Packer from the Department of Anatomy of Royal Melbourne Institute of Technology, Australia has stated that the institute has prepared a computer based pictorial catalogue of 150 specimens and the pictures have been stored in the computer. The catalogue can be copied on to any storage device and can also be printed [12].

Several modern museums are digitalised. Digitalization of a museum, involves development of anatomy related computer software and audio-visual aids, preferably both in English and in the regional languages, so that both the medical students and the public are benefitted. Marreez et al have described two modern day museums, which include the Anatomy Museum of Leiden Medical University in Netherlands and the Museum of Kawasaki Medical School, in Japan. The museums have applied the advances in information technologies and audio-visual aids for educational

purpose. The museum also displays related pathology specimens with electronic screens that display educational information regarding each specimen. As a part of the Leiden Medical School curriculum, medical students are required to visit the medical museum several times during their undergraduate training. Audio recordings have been prepared by faculty from the different medical specialties at Leiden, and students have the option of downloading these from Blackboard to MP3 players, including iPods to guide them through their museum visits. Narrations, in the familiar voices of their regular faculty, commenting on each specimen are also present. Students are then quizzed on each topic, with correct answers to the quizzes strongly reliant on close observation of the museum specimens [13].

It was observed that all the museums use formalin as a fixative and a preservative. It was observed most of the museums use either glass jars or acrylic jars. Some of the museums used perspex jars for preserving the specimens. Perspex jars have the following advantages as they are more clear and transparent, light weight, tough and more durable, have better optical properties and are easy to cut and jars of any required size may be prepared.

SUMMARY AND CONCLUSION

A well structured anatomy museum can now be planned and built that incorporates all these sections and features. This study only provides a foundation based on which several improvisations are possible. Each of these sections like evolutionary anatomy, genetics, history of anatomy and embryology sections can be greatly improvised. Sections can also be made on histology. Anatomical specimens can be correlated with important pathological specimens. Computerised pictorial catalogues and audiovisual aids and robotics can also be used in museums to explain embryology, evolution, gross anatomy and related physiology. To sum up while establishing a museum the anatomy staff must have a more holistic approach so as to involve a huge sectional variety thereby covering all aspects of anatomy. Such an integrated approach would certainly make the future museums more scientific and informative and serve as an insti-

tute were a great deal of practical anatomical knowledge is made accessible to both medical students and the public.

Acknowledgements:

I would like to thank all the deans and head of the department of anatomy of all the sixteen medical colleges for their support and guidance.

Conflicts of Interests: None

REFERENCES

- [1]. Findlen P. The Museum: Its classical etymology and renaissance genealogy. *JHist Collections*. 1989;Vol 1:59-78.
- [2]. Rengachary SS, Colen C, Darr K, Guthikanda M. Development of anatomic science in the middle ages: The roles played by Mondino de'Liuzzi and Giudo da Vigenano. *Neurosurgery*. 2009;65(4):787-793.
- [3]. Eknayan G. Michelangelo: art, anatomy and the kidney. *Kidney Int*. 2000;57(3): 1190-1201.
- [4]. Di Ieva A, Tschabitscher M, Prada F et al. The neuroanatomical plates of Guido da Vigevano. *Neurosurg Focus*. 2007;23(1):15.
- [5]. Kemp D & Barner S. *Surgeons' Hall: A Museum Anthology*. Royal College of Surgeons. Edinburgh. 2009.
- [6]. Maraldi NM, Mazzotti G, Cocco L, Manzoli FA. Anatomical wax work modeling: The history of the Bologna Anatomy Museum. *Anat Rec*. 2000. 261(1):5-10.
- [7]. Riva A, Conti G, Solinas P, Loy F. The evolution of anatomical illustration and wax modelling in Italy from the 16th to early 19th centuries. *J Anat*. 2010;216(2): 209-222.
- [8]. Lotti S, Altobelli A, Bambi S, Poggesi M. Illustrations of the anatomical wax model collection in the La Specola Zoology Museum, Florence. *Arch Nat Hist*. 2006;33(2):232-240.
- [9]. Esposito V and Chiapparo S. Role of anatomy in our contemporary age and the history of the anatomy museum of Naples. *Anat Rec*. 2006. 289B:92-97.
- [10]. Hildebrandt S. Capital punishment and anatomy: history and ethics of an ongoing association. *Clin Anat*. 2008;21(1):5-14.
- [11]. Thomas RC. A Traffic of dead bodies: Anatomy and Embodied Social Identity in nineteenth century America by Michael Sappol. *J Am Hist*. 2003;90(1):223.
- [12]. Packer JE. A computer based pictorial anatomy museum catalogue. *Medical Teacher*. 1994;16(1):97-100.
- [13]. Marreez YM, Williams LN, Wells MR. The role of medical museums in contemporary medical education. *Anat Sci Educ*. 2010;3:249-253.