

# AN ANATOMICAL STUDY OF FORAMEN SPINOSUM IN SOUTH INDIAN DRY SKULLS WITH ITS EMPHASIS ON MORPHOLOGY AND MORPHOMETRY

Somesh M.S.<sup>1</sup>, Murlimanju B.V.<sup>2</sup>, Ashwin Krishnamurthy<sup>3</sup>, Sridevi H.B.<sup>\*4</sup>.

<sup>1</sup> Associate Professor, Srinivas Institute of Medical Sciences & Research Centre (SIMS &RC), Mangalore, India.

<sup>2,\*4</sup> Assistant Professor, Kasturba Medical College, Mangalore, Manipal University, India.

<sup>3</sup> Associate Professor, Kasturba Medical College, Mangalore, Manipal University, India.

## ABSTRACT

**Aim:** To study the morphological details and to evaluate the morphometry of the Foramen Spinosum in the base of dry human skulls in South Indian population.

**Methods:** 82 dry adult human skulls of unknown sex and of South Indian origin were obtained and variations in appearance were observed. The length and width of the Foramen Spinosum on both sides were determined using vernier calipers and area (A) was calculated and analyzed. Also, its mean distance from the midline on both the sides was noted and analyzed.

**Results:** The values for the right side were  $3.425 \pm 0.637$  mm,  $2.687 \pm 0.487$  mm and  $7.357 \pm 2.195$  mm<sup>2</sup> and for the left side the values were  $3.339 \pm 0.660$  mm,  $2.675 \pm 0.465$  mm and  $7.110 \pm 2.103$  mm<sup>2</sup> respectively, for the mean length, mean breadth and mean area of the Foramen Spinosum. Also, the shape of the Foramen Spinosum was typically round in most of the skulls studied (53.65%) and it was little away from midline on the left side.

**Conclusion:** By analyzing the length, width and area of the Foramen Spinosum on both the sides, there was no statistical difference for the values obtained and these values were comparable with the studies done in the past.

**KEY WORDS:** Foramen Spinosum, Morphology, Morphometry, Skull, Sphenoid.

**Address for Correspondence:** Dr. Sridevi H.B., Assistant Professor, Department of Pathology, Light House Hill Road, Kasturba Medical College, Manipal University, Mangalore – 575001, Karnataka, India. PH: 91 -9632880334 (Mob) **E-Mail:** [drsri.20@gmail.com](mailto:drsri.20@gmail.com)

## Access this Article online

### Quick Response code



DOI: 10.16965/ijar.2015.151

**Web site:** International Journal of Anatomy and Research  
ISSN 2321-4287  
[www.ijmhr.org/ijar.htm](http://www.ijmhr.org/ijar.htm)

Received: 30 Mar 2015      Accepted: 27 Apr 2015  
Peer Review: 30 Mar 2015    Published (O):31 May 2015  
Revised: None                Published (P):30 June 2015

## BACKGROUND

The Foramen Spinosum (FS) is one of important openings in the infratemporal surface of greater wing of the sphenoid, just posterolateral to the foramen ovale. It transmits middle meningeal artery, a venous component, the middle meningeal vein which connects the cavernous sinus with the pterygoid plexus and the nervous spinosus [1].

Developmental studies done in the past and have shown that well defined ring-shaped foramen spinosum can be seen between 8th months to 7 years after birth [2] and the length of the foramen spinosum in newborn was about 2.25mm and in adults, about 2.56mm and its width extends from 1.05 to about 2.1mm in adults [3]. Also, Lindlom (1936) in his study on the vascular channels of the skull, found that

the foramen spinosum was small or altogether absent in 0.4% cases and in these cases the middle meningeal artery arises from the ophthalmic artery [4]. In rare cases, early division of the middle meningeal artery into an anterior and posterior division may result in the duplication of the foramen spinosum. Similarly in another study, the foramen spinosum was incomplete in approximately 44% of the cases [5].

Thus, this foramen spinosum present in the greater wing of sphenoid is prone for many variations in its shape, size and number and it is an important landmark in various microsurgeries in the middle cranial fossa [6] and we intent to study this foramen in detail regarding its morphological and morphometrical features in our ethnic group.

### MATERIALS AND METHODS

The materials for the present study included 82 dry adult human skulls of unknown sex and of Indian origin obtained from Bone bank of the Department of Anatomy, Srinivas Institute of Medical Sciences & Research Centre (SIMS&RC) and Kasturba Medical college, Mangalore, Karnataka state, India. The posterior part of greater wing of sphenoid was carefully examined for the existence of foramen spinosum and the damaged skulls were excluded.

The antero-posterior diameter / Maximum diameter / (Length) or "L" & perpendicular to this, transverse diameter / Minimum diameter / (width) or "W"/Breadth or "B" of the foramina spinosum of the foramina spinosum of both sides are determined using Digital Vernier calipers with a precision of 0.1 mm [7]. Each dimension was measured thrice and the mean figure recorded. The data collected was checked for errors prior to analysis. From these obtained values area "A" of the foramina spinosum was calculated using the formula:  $(\pi \times L \times B) / 4$  or  $\{(3.142 \times L \times B) / 4\}$  [8].

Data analysis of the obtained values was analyzed statistically using SPSS software version 11.5 for windows. The mean and standard deviation (SD) of each dimension were computed. Right and left differences were analyzed. A comparison was made of the means of the dimensions using the Student's t-test. A probability (P) of less than 0.05 was considered statistically significant.

### RESULTS AND OBSERVATIONS

**Morphology:** Foramen spinosum is normally located in the greater wing of the sphenoid bone, and the present study was conducted on a total of 164 sides in 82 dry adult skulls and various shapes of foramen spinosum was noted. Foramen spinosum was typically round in 88 sides (table-1; 46 right, 42 left), oval shape in 58 sides (table-1; 28 right, 30 left), pinhole shaped in 11 sides (Table-1; 5 right, 6 left) and irregular shaped in 7 sides (Table-1; 3 right, 4 left). The total incidence of round, oval, pinhole, and irregular shaped foramen ovale observed in our study were 53.65%, 35.36%, 6.70% & 4.26% respectively and those on the respective sides are shown separately in table 1.

**Morphometric analysis:** Table 2 shows the frequency of the Maximum Diameter / Antero-posterior Diameter/ or Length (L) of the foramen spinosum while Table 3 shows the frequency of Minimum Diameter Diameter or Breadth (B) on both the sides. The length varied from 2mm to 5mm on right and 1.5 mm to 4.5mm on left side but the frequency of 3.5 mm was found to be the maximum on both sides. The breadth varied from 1.5 mm to 4mm on right and 2 mm to 3.5mm on left side. But the maximum frequency on right was 3mm as compared to 2.5mm on left side. Also, Compared mean values of the length, breadth and area of the foramen Spinosum on both the sides are shown in table 4 and they are also depicted in figures 1 & 2.

Shape of the foramen	Percentage & Number on right side (n= 82)	Percentage & Number on left side (n= 82)
Irregular	3.6% ( 3)	4.8% ( 4)
Pinhole	6.0% ( 5)	7.3% ( 6)
Oval	34.1% ( 28)	36.5% ( 30)
Round	56.0% ( 46)	51.2% ( 42)

**Table 1:** Showing the Frequency of different Shapes of Foramen Spinosum.

Also the mean distance of this foramen spinosum from the midline is shown in the figure 3. All the values were analyzed statistically and the comparative analysis between the two sides is shown the table 4.

**Table 2:** Antero-posterior Diameter (Length) of the Foramen Spinosum in mm on both sides.

Maximum Diameter/ Antero-posterior diameter/ Length (L) in (mm)	FREQUENCY In Right Side	FREQUENCY In Left Side
1.5	0	1
2	3	2
2.5	10	12
3	19	22
3.5	23	24
4	21	13
4.5	5	8
5	1	0
<b>ABSENT(AB)</b>	2	0

**Table 3:** Transverse Diameter (Width) of Foramen Spinosum in mm on both sides.

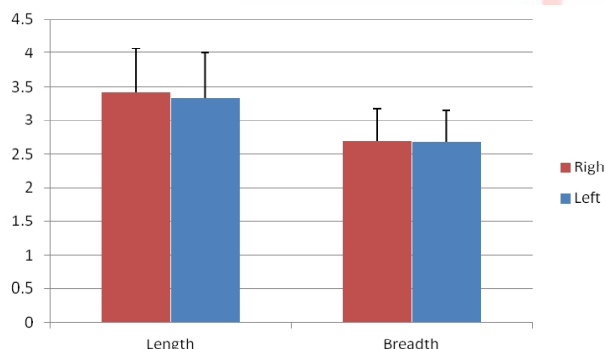
Minimum Diameter/ Transverse diameter / Breadth (B) in (mm)	FREQUENCY In Right Side	FREQUENCY In Left Side
1.5	3	2
2	11	13
2.5	29	32
3	32	26
3.5	6	9
4	1	0
<b>ABSENT(AB)</b>	2	0

**Table 4:** Side comparative results of Foramen Spinosum showing Mean & Standard deviations (SD).

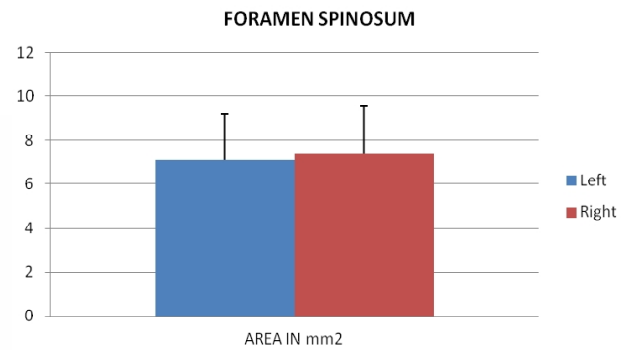
Parameters	Right Side (N = 82)	Left Side (N = 82)	"P" VALUE
	Mean ± SD	Mean ± SD (mm)	
Length(L) in mm	3.425 ± 0.637	3.339 ± 0.660	0.184
Breadth(B) in mm	2.687 ± 0.487	2.675 ± 0.465	0.831
Area (A) in mm <sup>2</sup>	7.357 ± 2.195	7.110 ± 2.103	0.304
Mean Distance From Midline ((MDM) in cm)	3.039 ± 0.179	3.086 ± 0.156	0.216

$P \leq 0.05$ , is considered as significant value.

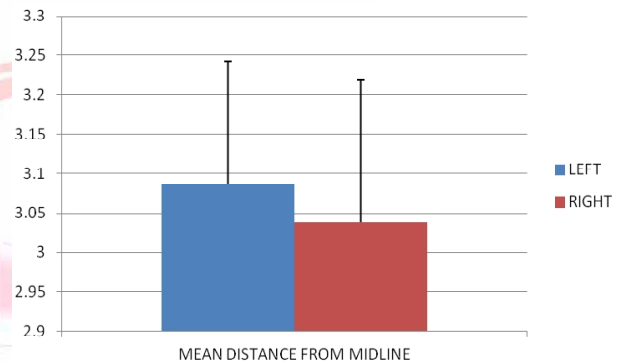
**Fig. 1:** Bar diagram showing Length & Breadth of Foramen Spinosum (in mm). The values are expressed as Mean ± SD.



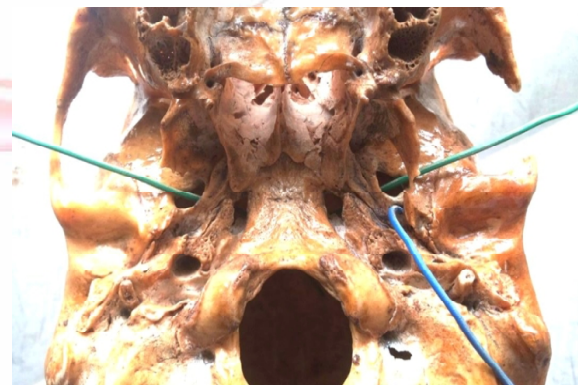**Fig. 2:** Bar diagram showing Area of Foramen Spinosum (in mm<sup>2</sup>). The values are expressed as Mean ± SD.



**Fig. 3:** Bar diagram showing the mean distance of Foramen Spinosum from the midline (in cm), on both the sides. The values are expressed as Mean ± SD.



**Fig. 4:** Figure showing base of the skull with absent foramen spinosum ( Arrow).



## DISCUSSION

The Foramen Spinosum is one of the important foramen in the greater wing of the sphenoid bone and the characteristics of the foramen spinosum were analyzed both from the skull base view as well as from the middle cranial fossa. In our study, most of the foramen Spinosum was typically round in shape followed by oval and the values are comparable with previous study by Anju et al, 2012 [9].

In the present study, the maximum diameter or Length (L) of the foramen spinosum were between 3.0 to 3.5mm (53%, 88 sides) and that of minimum diameter or Breadth (B) were

between 2.5-3mm (72%, 119 sides). Although the length of foramen spinosum were within the range reported previously, its breadth were slightly bigger than previous studies [3,7,9,10] but comparable with other south Indian study by Kulkarni & Nikade, 2013, where most of the foramen spinosum were round in shape as in the present one [11]. So we can attribute slightly greater width of the foramen spinosum to their round in shape as against asymmetry in size and shape noted before [3, 7]. The mean length of FS in our study was  $3.425 \pm 0.637$  mm on right and  $3.339 \pm 0.660$  mm on left side and even though the right foramen spinosum was slightly longer than left, this difference observed was not significant. In the previous studies by Anju et al, 2012, the mean length of foramen spinosum in male were  $3.31 \pm 0.84$  mm on left and  $3.73 \pm 0.63$  mm on right and that of female were  $3.20 \pm 0.83$  mm and  $3.81 \pm 0.71$  mm respectively and the difference between the sides and sexes was not statistically significant [9]. Also, the mean length of FS was  $2.92 \pm 0.65$  mm in females and  $2.67 \pm 0.62$  mm in males respectively [12] and in the newborn the Foramen spinosum is about 2.25 mm and in the adults about 2.56 mm in length, as noted by Lang et al, 1984 [3].

In our study, the mean breadth of FS on right side was  $2.687 \pm 0.487$  mm and  $2.675 \pm 0.465$  on left side and. We also calculated the area from the obtained values and it was  $7.357 \pm 2.195$  mm<sup>2</sup> on right and  $7.110 \pm 2.103$  mm<sup>2</sup> on left sides respectively. Also the mean distance of this foramen from the midline was measured and on right side it was  $3.039 \pm 0.179$  cm and left side the values were  $3.086 \pm 0.156$ . However there was no statistical significant difference on both the sides for all these parameters measured.

According to previous study by Lang et al, 1984 [3], the mean distance of FS to the median sagittal plane in the adults is 28.08 mm at the right side and 29.76 mm at the left side which is comparable to our study and FS on the left side was little away from midline; however the difference was not significant.

Regarding the variations in the shape of foramen spinosum noted, the maximum were round shaped (53.65%), followed by oval shapes,

similar to the studies conducted in the past [2, 12]. Also, we found FS to be absent on 2 right sides (Fig 4) similar to Singh et al 2001 [13], where they found duplicated FS in 2 cases & absent 1 case. We did not noticed any duplicated FS similar to many studies conducted in the past [9, 11, 12, 14,] however some of the authors have noticed double FS [15, 16, 17]. So, the exact reasons for double FS are not clear, but could be due to early division of the middle meningeal Artery [18].

The prevalence of Foramen Spinosum in the human skulls in various past studies varies from 98.5% [3] to 99.6% [4] and in our study it is 98.8%, which is comparable. Such absence of the foramen spinosum is clearly not understood, however it is to be noted that in many such cases, it is associated with altered course of the middle meningeal artery, where it arises from the ophthalmic artery and enters the middle cranial fossa through the superior orbital fissure [4]. Alternatively, the middle meningeal artery can also enter the cranial cavity through Foramen Ovale itself.

## CONCLUSION

The present study was aimed at having a detailed description of foramen spinosum in our ethnic origin; including its variant shapes, sizes, mean distance from midline etc in order to provide good insight for neurosurgeons, neuroradiologists and neurologists for undergoing many neurosurgical procedures in the middle cranial fossa. Not only that, this study is of clinical and anatomical significance to medical practitioners and radiologists as for the understanding and recognition of the morphometric variations of the foramen spinosum as they might come across during routine radiological and clinical investigation.

## ACKNOWLEDGEMENTS

The authors are grateful for the nonteaching staff of the department of anatomy of SIMS&RC & KMC, for their support in conducting the present study.

**Conflicts of Interests: None**

## REFERENCES

- [1]. Standring, S. *Gray's Anatomy; The Anatomical Basis of Clinical Practice*. 39th ed. London, Elsevier Churchill Livingstone, 2005. pp.462- 467
- [2]. Yanagi S. Developmental studies on the foramen rotundum, foramen ovale and foramen spinosum of the human sphenoid bone. *The Hokkaido Journal of Medical Science*.1987;62(3):485–96.
- [3]. Lang J, Maier R, Schafhauser O. Postnatal enlargement of the foramina rotundum, ovale et spinosum and their topographical changes. *Anatomischer Anzeiger*.1984;156(5):51–87.
- [4]. Lindblom K. A roentgenographic study of the vascular tumors and arteriovenous aneurysms. *Acta Radiol*.1936;30:1-146.
- [5]. Wood-Jones F. The non-metrical morphological characters of the skull as criteria for racial diagnosis. par 1: General discussion of the morphological characters employed in racial diagnosis. *J. Anat*. 1931;65:179-495.
- [6]. Ustun ME, Buyukmumcu M, Seker M, Karabulut AK, Uysal, II, Ziylan T. Possibility of middle meningeal artery-to-petrous internal carotid artery Bypass: an anatomical study. *Skull Base*. 2004;14(3):153-156.
- [7]. Osunwoke E A, Mbadugha CC, Orish CN, Oghenemavwe EL, Ukah CJ. A morphometric study of foramen ovale and foramen spinosum of the human sphenoid bone in the southern Nigerian population. *J. Appl. Biosci*. 2010; 26: 1631-1635.
- [8]. Chimmalgi M, Kulkarni Y, Sant SM. Sexing of skull by new metrical parameters in west India. *J. Anat. Soc. India*. 2007;56(1):28-32.
- [9]. Anju L R, Nirupma G, Rachna R. Anatomical Variations Of Foramen Spinosum. *Innovative Journal of Medical and Health Science*. 2012;2(5): 86–88.
- [10]. Berge JK, Bergman RA. Variations in size and in symmetry of foramina of the human skull. *Clin Anat*. 2001;14(6):406-413.
- [11]. Kulkarni SP, Nikade VV. A Morphometric Study of Foramen Ovale and Foramen Spinosum in Dried Indian Human Skulls. *International Journal of Recent Trends in Science And Technology*. 2013;7(2):74-75.
- [12]. Desai SD, Hussain SS , Muralidhar PS, Thomas ST, Mavishettar GF, Haseena S. Marphometric analysis of Foramen spinosum in south Indian skulls. *J. Pharm. Sci. & Res*. 2012;4(12):2022–2024.
- [13]. Singh, Brinjendra & Singh, Balbir. Study of middle cranial foramina GMC, Chandigarh. *J. Anat. Soc. India*. 2001;50(1):69-98.
- [14]. Reymond J, Charuta A, Wysocki J. The morphology and morphometry of the foramina of the greater wing of the human sphenoid bone. *Folia Morphol*. 2005;64(3):188-193.
- [15]. Karan B K, Prashant A B. Anatomical Study on the Foramen Ovale and the Foramen Spinosum. *Journal of Clinical and Diagnostic Research*. 2013;7(3):427-429.
- [16]. Karan BK , Surekha DJ , Umarji BN, Patil RJ, Ambali MP. Foramen Ovale & Foramen Spinosum: A Morphometric Study. *Anatomica Karnataka*. 2012;6(3):68-72.
- [17]. Khan, AA, Asari, MA and Hassan A. Anatomic variants of foramen ovale and spinosum in human skulls. *Int. J. Morphol*. 2012;30(2):445-449.
- [18]. Ginsberg LE, Pruett SW, Chen MY, Elster AD. Skull-base foramina of the middle cranial fossa: reassessment of normal variation with high-resolution CT. *Americal Journal of Neuroradiology*.1994;15(2):283–291.

### How to cite this article:

Somesh M.S., Murlimanju B.V, Ashwin Krishnamurthy, Sridevi H.B.  
AN ANATOMICAL STUDY OF FORAMEN SPINOSUM IN SOUTH INDIAN DRY SKULLS WITH ITS EMPHASIS ON MORPHOLOGY AND MORPHOMETRY. *Int J Anat Res* 2015;3(2):1034-1038.  
**DOI:** 10.16965/ijar.2015.151