

Case Report

VARIATIONS IN THE MUSCLES OF THE EXTENSOR COMPARTMENT OF THE FOREARM AND HAND AND ITS CLINICAL SIGNIFICANCE

Swati Tiwari ¹, Anita Mahajan ^{*2}, Rohini Pakhiddey ³.

¹ Senior Resident, Department Of Anatomy, Maulana Azad Medical College, New Delhi, India.

^{*2} Professor, Department Of Anatomy, Maulana Azad Medical College, New Delhi, India.

³ Assistant Professor, Department of Anatomy, Santosh Medical College, Ghaziabad, India.

ABSTRACT

Background: The extensor musculature of the forearm and hand shows diverse variations. These can lead to various clinical conditions.

Case Report: During routine cadaveric dissection, variations were observed in the muscles of extensor compartment of the forearm. Their anatomical relations were documented and the embryological basis and clinical importance was stressed upon. During routine cadaveric dissection in a formalin fixed 58 year old male cadaver, variations in the posterior compartment of the left forearm were noted, measured and appropriately photographed.

Observations: In the posterior compartment of the left forearm an accessory muscle was found originating from the posterior surface of ulna, just distal to the origin of extensor indicis. It traversed along with the tendons of extensor digitorum and extensor indicis in a common compartment underneath the extensor retinaculum and inserted onto the dorsal surface of the base of the proximal phalanx lateral to the tendon of extensor digitorum for the middle finger. Also, the extensor digitorum muscle divided only into three tendons instead of four- one each for the index, middle and ring finger. The three tendons inserted normally via the dorsal digital expansion but, the tendon for the ring finger gave an additional slip on the ulnar aspect, which inserted separately onto the base of the proximal phalanx of the ring finger.

Conclusion: Muscles in the extensor compartment of forearm may show diverse variations which have clinical relevance. Accessory muscles may be confused with soft tissue conditions like a ganglion. Supernumary tendons can be utilised for tendon transfers and muscle grafts. These variations must be brought to the knowledge of the surgeons performing hand surgeries.

KEY WORDS: Extensor muscles, forearm, accessory muscle, extensor digitorum, hand surgeries.

Address for Correspondence: Prof. Dr. Anita Mahajan, Professor, Department Of Anatomy, Maulana Azad Medical College, New Delhi, India. **E-Mail:** anitamahajan24@gmail.com

Access this Article online

Quick Response code



DOI: 10.16965/ijar.2015.145

Web site: International Journal of Anatomy and Research
ISSN 2321-4287
www.ijmhr.org/ijar.htm

Received: 20 Mar 2015 Accepted: 14 Apr 2015
Peer Review: 20 Mar 2015 Published (O):31 May 2015
Revised: None Published (P):30 June 2015

BACKGROUND

The skilled movements of human hand are vital in performing our routine activities. Hence a normal anatomy of this region is of immense importance. Any variations may hamper the movements of the forearm and hand. The arrangement of the human extensor muscles of

the forearm and wrist varies greatly. Knowledge of such variations is of importance for surgeons performing hand surgeries. Accessory muscles may cause compressive neuropathy and maybe misdiagnosed as soft tissue swellings [1]. As these variations are clinically significant, we hereby report a case of an accessory muscle in

the extensor compartment of forearm along with variations in the tendons of the extensor digitorum muscle.

Extensor digitorum normally arises from the common extensor origin on lateral condyle of humerus and the adjoining intermuscular septum. It divides distally into four tendons which pass in a common synovial sheath with the tendon of extensor indicis, through a tunnel under the extensor retinaculum. The tendon to the index finger is accompanied by extensor indicis, which lies medial to it. The digital attachments enter a fibrous expansion on the dorsum of the proximal phalanges. The tendons of extensor digitorum may be variably deficient or may be multiple in one or more digits, most often in the index finger or the middle finger.

On the dorsum of the hand, adjacent tendons are linked by three variable intertendinous connections, which are inclined distally and radially.

The arrangement of the intertendinous connections on the dorsum of the hand is highly variable. The medial connection is strong whereas the connection between the middle two tendons is weak and may be absent [2].

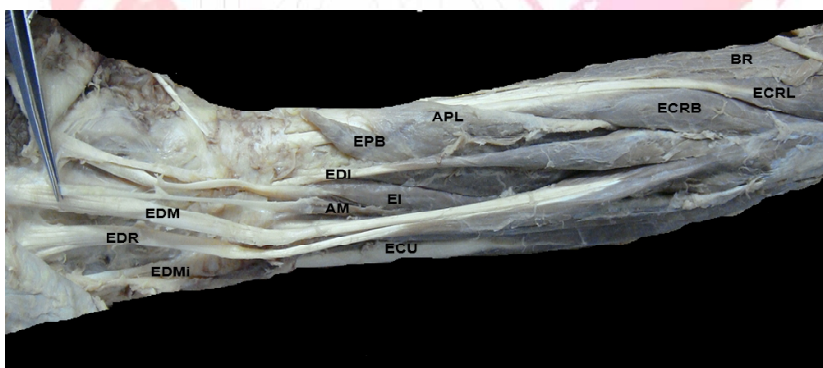
CASE REPORT

Routine cadaveric dissection of a 58 year old male, at Maulana Azad Medical College, New Delhi, India, revealed an accessory muscle in the posterior compartment of the left forearm and also, variations in the number of tendons of extensor digitorum (ED). The variations were dissected, photographed and appropriate measurements were taken.

OBSERVATIONS

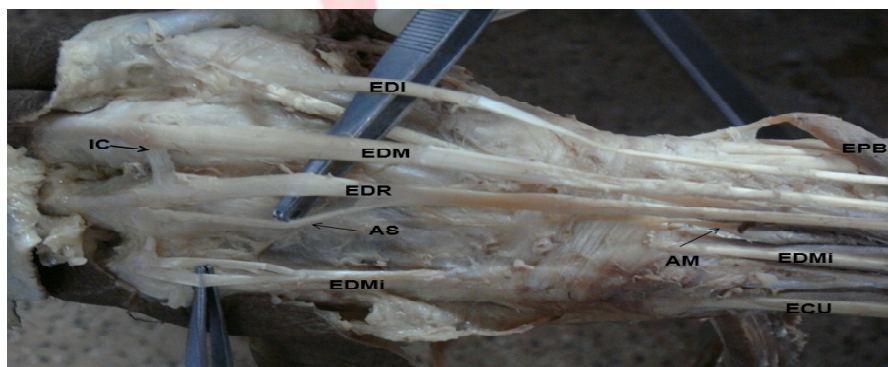
The accessory muscle was found originating from the posterior surface of ulna, just distal to the origin of extensor indicis (EI). It traversed along with the tendons of ED and EI in a common

Fig. 1a: Showing the variations in posterior compartment of left forearm:



BR=Brachioradialis, ECRL=Extensor carpi radialis longus, ECRB= Extensor carpi radialis brevis, APL= Abductor pollicis longus, EPB=Extensor pollicis brevis, EDI=Tendon of extensor digitorum for index finger, EDM=Tendon of extensor digitorum for middle finger, EDR=Tendon of extensor digitorum for ring finger, EI=Extensor indicis, AM= Accessory muscle, EDMi=Extensor digiti minimi, ECU=Extensor carpi ulnaris.

Fig. 1b: Showing the variant tendons on the dorsum of the hand:



EPB=Extensor pollicis brevis, EDI=Tendon of extensor digitorum for index finger, EDM=Tendon of extensor digitorum for middle finger, EDR=Tendon of extensor digitorum for ring finger, EI=Extensor indicis, AM= Accessory muscle, EDMi=Extensor digiti minimi, ECU=Extensor carpi ulnaris, AS=Additional slip. IC= Intertendinous connection.

compartment underneath the extensor retinaculum. Its tendon lay medial to the tendon of EI and lateral to the ED tendon for the middle finger. The posterior interosseous vessels and nerve lay dorsal to it. The length of the belly was 4.5 cm and the tendon was 8.4 cm long. It inserted onto the dorsal surface of the base of the proximal phalanx lateral to the tendon of extensor digitorum for the middle finger. The nerve supply to the accessory muscle was derived from the posterior interosseous branch of radial nerve.

Also, the extensor digitorum muscle divided only into three tendons instead of four- one each for the index, middle and ring finger. There was no tendon for the fifth digit. The three tendons inserted normally via the dorsal digital expansion. In addition, the tendon for the ring finger gave an additional slip from the ulnar aspect 2.6 cm distal to the distal border of extensor retinaculum. This slip inserted separately onto the base of the proximal phalanx of the ring finger. The extensor digiti minimi muscle was very well developed and gave a single tendon that split 4 cm distal to the distal border of extensor retinaculum.

DISCUSSION

Variations in the muscles of the extensor compartment of the forearm are often encountered during surgical and dissection procedures. The anomalous muscle observed here is usually described in literature as the extensor medius proprius (EMP) muscle. The EMP has a belly originating from the distal third of the ulna, near the origin of EI, and its tendon is inserted into the dorsal aponeurosis of the middle finger. von Schroeder et al [3] and Das P et al [4] have also noted the presence of this muscle in their dissections. . Bharambhe VK et al reported two EMP muscles on the dorsum of right hand in an adult male cadaver [5].

The absence of ED tendon for little finger has been documented by Celik S et al [6] and Das P et al [4]. Zilber S et al also reported similar variation in the ED tendons [7]. Das P et al have reported that the EDMi displayed a single tendon that finally divided into two slips in majority of their cases. However, they also documented few cases of EDMi with two tendons and rarely, three

tendons [4]. Seradge et al [8] and Jing Li et al [9] have reported an EDMi with three slips; two slips to the little finger and one to the ring finger. el Badawi et al found that in most of their cases, EDMi muscle had two tendons [10].

The presence of an accessory muscle can be explained embryologically by the appearance of an extra cleavage in the forearm muscle mass during development. The extensor muscle mass divides into three parts, a radial part, a superficial and a deep part. Brachioradialis, the extensor carpi radialis longus and extensor carpi radialis brevis arise from the radial part. The superficial part forms extensor digitorum, extensor carpi ulnaris and extensor digiti minimi. The deep part gives rise to abductor pollicis longus, the extensor pollicis brevis on the radial side with the extensor pollicis longus, extensor indicis on the ulnar side. The deep part is highly varied in the evolution of primates [11].

An accessory muscle can be utilised by the surgeon for muscle graft, thereby sparing the normal muscles. The additional muscle if small, may remain asymptomatic and unnoticed. However, if it is large, it may reduce the space in the respective compartment and increase the risk of tenosynovitis and extensor indicis proprius syndrome. Baker and Gonzalez have reported symptoms of pain on flexion of wrist, snapping wrist and subluxation of ring finger tendon due to the presence of a hypertrophied extensor indicis proprius muscle [12]. The belly may be confused with a soft tissue swelling such as a ganglion, synovial nodule or cyst. The diagnosis can be confirmed by non invasive imaging techniques such as Magnetic Resonance Imaging [13]. Additional tendinous slips can be used to replace ruptured tendons.

CONCLUSION

Considering the clinical significance of these variations, it is imperative that the clinicians be made aware of their incidence to enable better diagnosis and treatment.

ACKNOWLEDGEMENT

We are thankful to the staff of the dissection hall of the Department of Anatomy, MAMC, for their constant support.

Conflicts of Interests: None

REFERENCES

- [1]. Tan ST, Smith PJ. Anomalous extensor muscles of the hand: A review. *The Journal of Hand Surgery*. 1999 May;24(3):449-455.
- [2]. Johnson D. Forearm. In *Gray's Anatomy: The Anatomical Basis Of Clinical Practice*. 40th edition. Edited by Standring S. Spain: Elsevier Churchill Livingstone; 2008:839-856.
- [3]. Von Schroeder HP, Botte MJ. The extensor medii proprius and anomalous extensor tendons to the long finger. *J Hand Surg Am*. 1991 Nov;16(6):1141-5.
- [4]. Das P, Prabhu LV, Pai MM, Nayak V, Kumar G, Janardhanan JP. A Comprehensive Study of the Extensor Tendons to the Medial Four Digits of the Hand. *Chang Gung Med J*. 2011 Nov-Dec;34(6):612-619.
- [5]. Bharambe VK, Patel DK, Shevade SP, Manvikar PR. Presence of rare variation of double extensor medii proprius muscle on the dorsum of the hand. *OA Case Reports*. 2013 Jun 21;2(5):43.
- [6]. Celik S, Bilge O, Pinar Y, Govsa F. The anatomical variations of the extensor tendons to the dorsum of the hand. *Clin Anat*. 2008 Oct;21(7):652-9.
- [7]. Zilber S, Oberlin C. Anatomical variations of the extensor tendons to the fingers over the dorsum of the hand: a study of 50 hands and a review of the literature. *Plast Reconstr Surg*. 2004 Jan; 113(1):214-21.
- [8]. Seradge H, Tian W, Baer C. Anatomic variation of the extensor tendons to the ring and little fingers: a cadaver dissection study. *Am J Orthop*. 1999; 28(7):399-401.
- [9]. Jing Li, Mao QH. Accessory slips of the extensor digiti minimi. *Rom J Morphol Embryol*. 2014; 55(2):487-489.
- [10]. El-Badawi MG, Butt MM, al-Zuhair AG, Fadel RA. Extensor tendons of the fingers: arrangement and variations—II. *Clin Anat*. 1995;8(6):391-8.
- [11]. Straus WL. The phylogeny of the human forearm extensors. *Hum Biol*, 1941, 13(1-2):23-50, 204-238.
- [12]. Baker J, Gonzalez MH. Snapping wrist due to an anomalous extensor indicis proprius: A Case Report. *Hand*. 2008;3:363-365.
- [13]. Sookur PA, Naraghi AM, Bleakney RR, Jalan R, Chan O, White LM. Accessory Muscles: Anatomy, Symptoms, and Radiologic Evaluation. *Radio Graphics*. 2008;28:481-499.

How to cite this article:

Swati Tiwari, Anita Mahajan, Rohini Pakhiddey. VARIATIONS IN THE MUSCLES OF THE EXTENSOR COMPARTMENT OF THE FOREARM AND HAND AND ITS CLINICAL SIGNIFICANCE. *Int J Anat Res* 2015;3(2):1024-1027. **DOI:** 10.16965/ijar.2015.145