

## Case Report

# MEDIAN NERVE AS A NERVE OF ANTERIOR COMPARTMENT OF ARM WITH ITS VARIANT FORMATION

Charushila D. Shinde\*, Rekha Mane.

Assistant Professor, Dept. of Anatomy, MGM Medical College, Navi Mumbai, Maharashtra, India.

### ABSTRACT

Absence of Musculocutaneous nerve and unusual formation and innervation of Median nerve were noted in left upper limb during anatomical dissection of 60 yr old female cadaver. Median nerve normally does not give any branch in arm but in this case it innervates all the muscles of anterior compartment of arm in place of Musculocutaneous nerve. Here we discussed its embryology. It is important to be aware of such possible anatomical variations in routine clinical practice.

**KEY WORDS:** Brachial plexus, Median nerve, Musculocutaneous nerve, Flexor muscles, lateral cord, Medial cord.

**Address for Correspondence:** Dr. Charushila D. Shinde, Assistant Professor, Dept. of Anatomy, MGM Medical College, Navi Mumbai, Maharashtra, India. Mobile No.: +919420112269

**E-Mail:** charushila29@gmail.com

### Access this Article online

#### Quick Response code



DOI: 10.16965/ijar.2015.146

**Web site:** International Journal of Anatomy and Research  
ISSN 2321-4287  
[www.ijmhr.org/ijar.htm](http://www.ijmhr.org/ijar.htm)

Received: 23 Mar 2015      Accepted: 16 Apr 2015  
Peer Review: 23 Mar 2015    Published (O): 30 Apr 2015  
Revised: None                Published (P): 30 June 2015

## INTRODUCTION

Musculocutaneous nerve (C5-7) is a branch of lateral cord of brachial plexus and is its continuation. It is the nerve of anterior compartment of the arm. Its muscular branches are to Coracobrachialis, Biceps Brachii and Brachialis and it continues as Lateral Cutaneous nerve of forearm which supplies lateral aspect of forearm till the base of thenar eminence.

Median nerve is formed in axilla by union of lateral root (C5-7) and medial root (C8, T1) of lateral & medial cord of brachial plexus respectively [1].

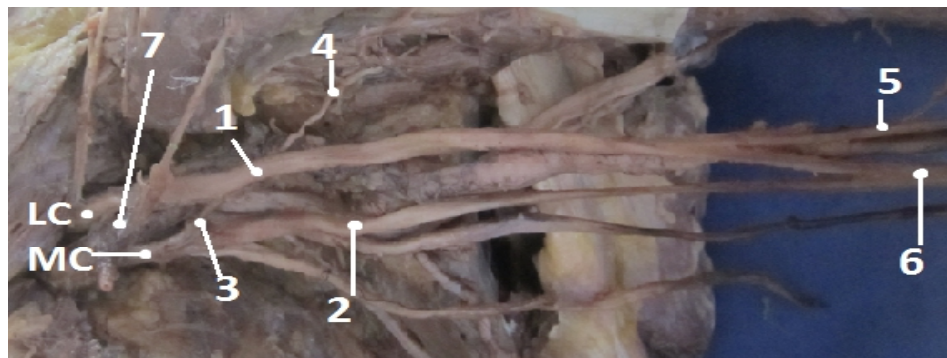Knowledge of anatomical variation of these nerves in axilla and arm are very important for surgical purpose.

## CASE REPORT

During the routine dissection of 60 yr old female cadaver at MGM Medical College, Navi Mumbai, in left upper limb we noticed:

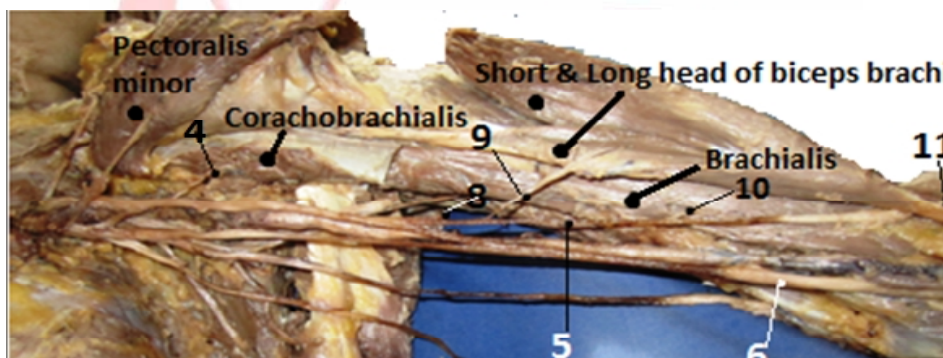
1. Absence of Musculocutaneous nerve
2. Median nerve receives III<sup>rd</sup> additional root from medial cord of brachial plexus Anterior to II<sup>nd</sup> part of Axillary artery.
3. Lateral root of Median nerve gives a branch to Coracobrachialis.
4. Lateral root of Median nerve gives a common trunk which supplies to-
  - a. Long and short head of Biceps Brachii individually
  - b. Branch to Brachialis

**Fig 1:** LC,MC-Lateral and Medial Cord of brachial plexus.



1- lateral root of Median nerve, 2- medial root of median nerve, 3-3<sup>rd</sup> root of median nerve, 4- br. To coracobrachialis, 5- common trunk, 6- Median nerve, 7- 2<sup>nd</sup> part of axillary artery.

**Fig . 2:** diagrammatic representation of variation Showing variation in formation of Median nerve and its supply to anterior compartment muscles.



5- common trunk, 8,9- Br. To short & long head of biceps, 10- Br. To brachialis, 11- Lateral cutaneous nr.

c. And it continues as Lateral Cutaneous nerve of forearm

5. Median nerve is formed in middle of the arm. In lower half of arm, in cubital fossa, in forearm and in hand its course and branches are normal.

## DISCUSSION

Median nerve as reported in literature is associated with several variations which include abnormal communication with other nerves such as Musculocutaneous nerve, Ulnar nerve, splitting of Median nerve and unusual innervation of flexor muscles in arm by median nerve [2].

In our study, Musculocutaneous nerve is absent and all flexor group of muscles in arm are supplied by Median nerve.

Uzan (2001) found that 3 roots of lateral cord and 1 root of medial cord form Median nerve [3].

In our study, 2 roots from medial cord and 1 root from lateral cord took part in formation of Median nerve.

Jahanshali (2003) found that, absence of Musculocutaneous nerve, and muscles supplied by it were supplied by Median nerve. Here the formation of Median nerve is normal i.e lateral and medial root from lateral and medial cord of brachial plexus respectively [4].

In our study, Musculocutaneous nerve is absent, and muscles supplied by it are supplied by Median nerve (Lateral root) which is formed at middle arm level and also receives III<sup>rd</sup> root from medial cord anterior to 2<sup>nd</sup> part of axillary artery. Satyanarayana (2009), described 3 unilateral cases of variation of formation of Median nerve. In 1<sup>st</sup> case he described Median nerve formed on medial side of Axillary artery at higher level. Later median nerve continued behind brachial artery and receives a communicating branch from lateral cord. In the 2<sup>nd</sup> case -formation of Median nerve by three roots- 2 from lateral and 1 from medial cord of brachial plexus. In 3<sup>rd</sup> case -formation of Median nerve by four roots- 3 from lateral and 1 from medial cord of brachial plexus [5].

In our case, lateral root receives additional communicating root from medial cord in front of II<sup>nd</sup> part of Axillary artery. Median nerve formation take place at middle of the arm. Additional to it it supplies flexor group of muscles in arm as Musculocutaneous nerve is absent.

Combination of absence of Musculocutaneous nerve, Median nerve receives 3<sup>rd</sup> root anterior to 2<sup>nd</sup> part of axillary artery and formation of Median Nerve at lower level (at middle of the arm) as seen in our case, is rare occurrence.

Knowledge of variable patterns of nerve formation and nerve supply to muscles, joints skin is essential to explain the unexpected clinical signs and symptoms. It is also helpful during surgical interventions like shoulder reconstructions, incision and drainage of abscesses, block dissection of axilla, axillary lymph nodes, reconstructive flab surgeries etc. Presence of such variations should always kept in mind while testing a muscle, after administration of neuromuscular block. It is important for surgeon, clinician and anatomist to be aware of possible anatomical variations to avoid unexpected complications.

**Embryology:** The embryological development of upper limb may help in explaining these anatomical variations.

Significant variations in nerve patterns may be result of altered signaling between mesenchymal cells and neuronal growth cones [6] or circulatory factors at the time of fusion of brachial cords [7].

The axons of somatic motor fibers in dorsal and ventral rami seek out specific muscle or bundle of muscles fibers and form synapses with the muscle fibers. The specific signals that guide motor fibers to their targets are unknown. Axons have remarkable ability to reach their appropriate targets.

The motor axons that innervate the limb perform an intricate feat of path finding to reach their target muscles. The axons destined for the limb apparently travel to the base of limb bud by growing axon permissive pathways. Once the motor axons arrive at the base of limb bud, they mix in specific pattern to form brachial plexus in upper limb. This zone constitutes the decision

making region. Once axons have sorted out in plexus, growth cones continue into the limb bud, travelling along permissive pathways that lead in general direction of appropriate muscle compartment [8].

In our case, the growth cone of ventral column motor axons coming for Musculocutaneous nerve takes different path to travel to target organs; it passes through lateral root of Median nerve. Growth cone recognize their target organs and innervate them. Median nerve has two medial roots as fibers from C8 and T1 spinal segment passes separately to form Median nerve.

## CONCLUSION

The variation in Median nerve formation and its innervation, and absence of Musculocutaneous nerve have no effect on the functions of upper limb but knowledge of various pattern of brachial plexus is essential for medical professionals who explores axilla for treatment, interventions' or block dissection.

**Conflicts of Interests: None**

## REFERENCES

- [1]. Gray's Anatomy, 40th edition. Edinburgh, London, Newyork, Philadelphia, Sydeny, Toronto:Churchill Livingstone, 2008: pp 781,790, 821, 822.
- [2]. Budhiraja V, Rastogi R, Astana AK. Anatomical variation of median nerve formation:embryological and clinical correlation. J. MorphocolSci. 2011;28(4):283-286.
- [3]. Uzan A, Seelig LL Jr. A variation in formation of median nerve: communicating branch between musculocutaneous and median nerve in man. Folia Morphocol (Warsz), 1997:60:99-101.
- [4]. Jahanshahi M, Moharreri AR, Golalipour MJ. A variation of brachial plexus: Absence of musculocutaneous nerve. MJH, 2003;6:87-88.
- [5]. Satyanarayan N, Vishvkarma N, Kumar GP, Guha R, Datta AK, Sunita P. Rare variations in formation of median nerve: embryological basis. Nepal Med Col J. 2009;11(4):287-290.
- [6]. Abhya A, Bhardwaj R, Prakash R. Dual origin of Musculocutaneous nerve. Journal of Anatomical society of India 2003;52(1):94.
- [7]. Brown MC, Hopkins WG, Keyneys RJ. essentials of neural development Cambridge: Cambridge univercity press, 1991: pp 46-66.
- [8]. Larsen's William J. 200—, Human embryology. 4th edition, Newyork, Edinburgh, Churchill Livingstone, pp 640-642.