

A STUDY ON FACIAL ARTERY VARIATION AND ITS CLINICAL IMPLICATION FOR FACIAL SURGERIES

Md Khaleel Ahmed ¹, Pradeep K. Murudkar ², Md.Kafeel Ahmed ³.

*¹ Assistant Professor, Department of Anatomy, KBN Medical College, Kalaburagi, Gulbarga, Karnataka, India.

² Professor and HOD, Department of Anatomy, KBN Medical College, Kalaburagi, Gulbarga, Karnataka, India.

³ Tutor, Department of Dentistry, KBN hospital, Kalaburagi, Gulbarga, Karnataka, India.

ABSTRACT

Introduction: Accurate knowledge of the normal and variant arterial anatomy of the facial artery is important for vascular radiology and will provide an anatomical basis to assist surgeons in performing maxillo-facial surgeries successfully.

Materials and Methods: Formalin-fixed faces of unknown sex adult cadavers were dissected following the Cunningham's manual of practical anatomy, volume 3. The age of the cadavers was not noted.

Results: The variations in the facial artery were grouped under three categories following the classification of Bayramet.al, 2010. Type I category – Facial artery terminated as angular artery ; Type II category – facial artery terminated as superior labial ; Type III – Facial artery terminated as inferior labial .In present study (type-II) is seen. Premasseteric branch was observed.

Discussion: Niranjana NS (1988) observed the variations of facial artery in 50 hemi-faces. According to him, facial artery terminated as angular artery in 68 % of hemi-faces, lateral nasal artery in 26% of hemi-faces, Superior labial artery in 4% of hemi-faces and 2% terminated at the alar base. In present study facial artery terminates as superior labial artery. A study conducted by Magden et.al (2009) , on the premasseteric branch, suggested that in 3% cases the diameter of premasseteric branch was larger than the facial artery.

Conclusion: This study shows that the variation in the branching pattern of facial artery variations, which help in avoiding the mishaps during certain surgical procedures.

KEY WORDS: Facial Artery, Inferior Labial Artery, Lateral Nasal Artery Premasseteric Branch, Superior Labial Artery.

Address for Correspondence: Dr. Md Khaleel Ahmed, Assistant Professor, Department of Anatomy, KBN Medical College, Kalaburagi, Gulbarga, Karnataka, India.

E-Mail: dr.mohammedkhaleel786@gmail.com

Access this Article online

Quick Response code



DOI: 10.16965/ijar.2015.134

Web site: International Journal of Anatomy and Research
ISSN 2321-4287
www.ijmhr.org/ijar.htm

Received: 10 Mar 2015 Accepted: 25 Mar 2015
Peer Review: 10 Mar 2015 Published (O):31 Mar 2015
Revised: 13 Mar 2015 Published (P):31 Mar 2015

INTRODUCTION

The facial artery and superficial temporal artery arise from the external carotid artery. The facial artery which is usually the main artery of the face, is superficial and pursues a tortuous course from the anteroinferior border of masseter

upto the medial angle of the eye. The tortuosity presumably allows it to stretch when the face is distorted during jaw opening. It supplies branches to the adjacent muscles and skin of the face. Its named branches on the face are the premasseteric artery, the superior and inferior

labial arteries and the lateral nasal artery. The part of the artery distal to its terminal branch is called the angular artery. Premasseteric artery is a small inconstant artery. When present, it passes upwards along the anterior border of masseter and supplies the surrounding tissues. The inferior labial artery arises just below the angle of the mouth, passes upwards and forward sinuously near the margin of the lower lip, between the muscle and the mucous membrane. Superior labial artery is larger and more tortuous than the inferior labial artery, and has a similar course along the superior labial margin. Lateral nasal artery is given off by the side of the nose. It may be replaced by a branch from the superior labial artery [1].

Facial artery is known to show some variations in its origin, course and branching pattern [2]. Superficial temporal artery arises as the terminal branch of external carotid in the parotid gland behind the neck of the mandible. Its named branches are the transverse facial, auricular, zygomatico-orbital, middle temporal, frontal and parietal arteries. Transverse facial artery traverses the gland, crosses the masseter between the parotid duct and the zygomatic arch and divides into numerous branches. The branches anastomose with the facial, masseteric, buccal, lacrimal and infraorbital arteries, and may have a direct origin from the external carotid artery¹. In a study conducted by to Lohn et.al (2011) [3] on 201 facial arteries, suggested that, the facial artery predominantly terminated as lateral nasal artery in 49% of cases and facial artery was undetectable with transverse facial artery dominance in 5% cases. Tubbs et.al (2005) [4] reported a case of enlarged transverse facial artery with the agenesis of facial artery. Bayram et.al (2010) studied the variations of facial artery in the fetuses. He divided the variations into three categories. Type I category – facial artery terminated as angular artery, Type II category – facial artery terminated as superior labial artery, Type III category – facial artery terminated as inferior labial artery [5]. The knowledge of such variations of facial artery becomes more important during maxillofacial, rhinoplastic and orofacial surgeries. It is also important in performing the facial artery musculo-mucosal flap [6] which has been used

for the reconstruction of oronasal fistulas [7] and closure of soft tissue defects in mandibular vestibule [8]. Facial artery is selected as a target for super selective intra arterial chemotherapy during the treatment of some cancers of the head [9].

MATERIALS AND METHODS

Formalin-fixed faces of unknown sex adult cadavers were dissected following the Cunningham’s manual of practical anatomy, volume 3. The age of the cadavers was not noted. Course, main branches and termination of facial artery on face was noted and photographed. Facial artery was noted at two regions, namely at the point of its origin and at the anteroinferior angle of masseter where it enters the face. Gross variations in the arterial supply of face were also noted.

RESULTS

The variations in the facial artery were grouped under three categories following the classification of Bayramet.al, 2010. Type I category – Facial artery terminated as angular artery ; Type II category – facial artery terminated as superior labial ; Type III – Facial artery terminated as inferior labial .In present study (type-II) is seen. Premasseteric branch was observed (Figure 1,2,3).

Table 1: Showing the variations of the facial artery.

	TYPE I	TYPE II	TYPE III
Right side	-	+	-
Left side	-	+	-

Fig. 1: Superior labial and inferior labial branches of facial artery is present, absent of lateral nasal branch & showing large pre masseteric which is arising from facial artery is present (right side).




Fig. 2: All the normal branches of facial artery are present , but one small extra branch i.e.pre masseteric is seen which arising from facial artery (right side).

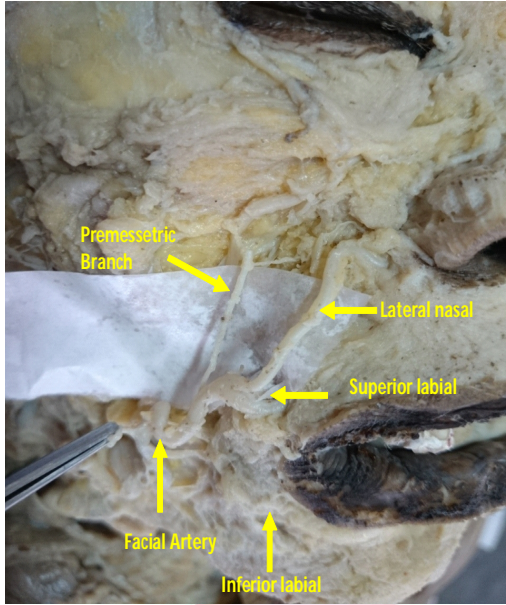
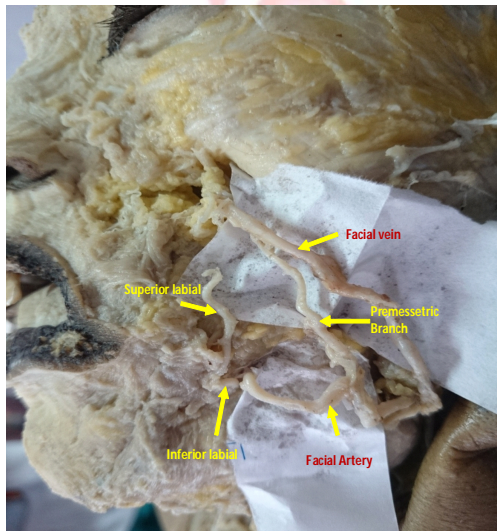


Fig. 3: Showing large pre masseteric which is arising from facial artery is present, superior and inferior labial branches of facial artery are present where as lateral nasal branch of facial artery is absent (left side).



DISCUSSION

In the present study facial artery showed wide range of variation. In case of its variation, arterial supply to the face may be furnished by branches of transverse facial artery and the arteries accompanying the cutaneous nerves of face. Premasseteric branch of facial artery which was first described by Adachi in 1928 is likely to be injured causing severe bleeding during maxillofacial surgeries [5]. A study conducted by Magden et al (2009), on the premasseteric branch, suggested that in 3% cases the diameter

of premasseteric branch was larger than the facial artery. Loukas et.al (2006) [10] divided the variations of facial artery under five categories. Type A- facial artery terminated by bifurcating into superior labial and lateral nasal arteries (47.5%); in Type B- facial artery terminated as superior labial and lateral nasal with the lateral nasal continuing as superior alar artery (38.7%); in Type C- facial artery terminates as superior labial artery (8.4%); in Type D angular artery arises directly from facial arterial trunk rather than as a termination of lateral nasal, with the facial artery ending as superior alar artery (3.8%); in Type E- facial artery terminated as a rudimentary twig without providing any significant branches (1.4%). He specially emphasized on the superior labial artery. Niranjana NS (1988) [11] observed the variations of facial artery in 50 hemi-faces. According to him, facial artery terminated as angular artery in 68 % of hemi-faces, lateral nasal artery in 26% of hemi-faces, Superior labial artery in 4% of hemi-faces and 2% terminated at the alar base. In present study facial artery terminates as superior labial artery. Bayram et.al (2010) [12] observed variations of facial artery in fetuses. He found Type I facial artery in 76%, Type II category in 12% and Type III category in 12% of hemi-face. In our study, Type II was observed (table I). Kumar N et.al (2011) [13] stated that the premasseteric branch is likely to be injured causing severe bleeding during maxillofacial surgeries. This artery may compress upon the facial vein or parotid duct where it crosses them. The masseter muscle is often exploited by craniofacial surgeons without the knowledge of the occurrence of premasseteric branch of facial artery. Gardetto et.al (2002) [14] analyzed a cutaneous branch of facial artery, which was named as cutaneous zygomatic branch according to its topographical location. In the present study, no such branch was found.

CONCLUSION

The facial artery musculo-mucosal (FAMM) flap has many advantages with its long rotational arc, but its use is limited by variations in the course of the facial artery. Therefore, knowledge about the precise course and branching pattern of the facial artery is required. Our main aim in

this study was to equip the surgeons, oncologists and academicians of the possible variations in the facial artery branches which would help in avoiding the mishaps during certain surgical procedures such as facelift operations, and may contribute to the ease and speed when performing the surgeries and also provide a confident approach to the plastic surgeons to perform reconstructive procedures in this region in order to increase the cosmetic value of an individual.

Conflicts of Interests: None

REFERENCES

- [1]. Standring S, ed. Gray's Anatomy. The Anatomical Basis of Clinical Practice. 40th Ed., Edinburgh, Churchill Livingstone. 2009; 490-491.
- [2]. Kumar N, Nayak SB, Shetty S, Guru A. Unusual posterior (premasseteric) branch of facial artery – a case report. IJAV.2011; 4:161-3.
- [3]. Lohn JW, Penn JW, Norton J, Butler PE. The course and variation of the facial artery and vein: implications for facial transplantation and facial surgery. Ann Plast Surg, 2011;67(2):184-8.
- [4]. Tubbs RS, Salter EG, Oakes WJ. Unilateral agenesis of the facial artery with compensation by a giant transverse facial artery. Folia Morphol(Warsz). 2005; 64(3):226-8.
- [5]. Adachi B. Arteriensystem der Japaner. Band I, Kyoto, Verlag der Kaiserlich-Japanischen Universitatzu Kyoto. 1928;73-7 (Japanese).
- [6]. Pribaz J, Stephens W, Crespo L, Gifford G. A new intra oral flap: facial artery musculomucosal (FAMM) flap. PlastReconstr Surg. 1992;90(3):421-9.
- [7]. Dupoirieux L, Plane L, Gard C, Penneau M. Anatomical basis and results of the facial artery musculomucosal flap for oral reconstruction. Br J Oral Maxillofac Surg. 1999;37(1):25-8.
- [8]. Hatoko M, Kuwahara M, Tanaka A, Yurugi S. Use of faciaartery musculomucosal flap for closure of soft tissue defects of the mandibular vestibule. Int J Oral Maxillofac Surg. 2002;31(2):210-11.
- [9]. Magden O, Gocmen-mas N, Senan S, Edizer M, Karacayli U, Karabekir HS. The premasseteric branch of facial artery: Its importance for craniofacial surgery. Turkish Neurosurgery. 2009;19(1):45-50.
- [10]. Loukas M, Hullet J, Louis RG Jr, Kapos T, Knight J, Nagy R, et al. A detailed observation of variations of the facial artery, with emphasis on the superior labial artery. SurjRadiol Anat. 2006;28(3):316-24.
- [11]. Niranjana NS. An anatomical study of the facial artery. AnnPlast Surg. 1988;21(1):14-22.
- [12]. Bayram SB, Kalaycioglu A. Branching patterns of facial artery in fetuses. The New Journal of Medicine. 2010; 27:227-30.
- [13]. Kumar N, Nayak SB, Shetty S, Guru A. Unusual posterior (premasseteric) branch of facial artery – a case report. IJAV.2011;4:161-3.
- [14]. Gardetto A, Moriggl B, Maurer H, Erdinger K, Papp C. Anatomical basis for a new island axial pattern flap in the perioral region. Surg Radiol Anat, 2002;24(3-4):147-54.

How to cite this article:

Md Khaleel Ahmed, Pradeep K. Murudkar, Md. Kafeel Ahmed. A STUDY ON FACIAL ARTERY VARIATION AND ITS CLINICAL IMPLICATION FOR FACIAL SURGERIES. Int J Anat Res 2015;3(1):966-969. DOI: 10.16965/ijar.2015.134