

## HEMIMELIA: MYSTERY UNRAVELLED

Subhra Mandal <sup>\*1</sup>, Prabir Mandal <sup>2</sup>, Basundhara Ghoshal <sup>3</sup>.

<sup>\*1</sup> Associate Professor, Dept. of Anatomy, Medical College Kolkata, West Bengal, India.

<sup>2</sup> Post Graduate Resident in DNB ( PMR ), S.N.P. Hospital , Kolkata, West Bengal, India.

<sup>3</sup> Dept. of Physical Medicine & Rehabilitation, R.G.Kar Medical College & Hospital, Kolkata, West Bengal, India.

### ABSTRACT

Hemimelia (Greek Hemi + melos i.e Half limb) is a developmental anomaly characterized by the absence or gross shortening of lower portion of one or more of the limbs. The condition may involve either or both bones of distal arm or leg. It is designated according to which bone is absent or defective as fibular, radial, tibial or ulnar hemimelia. In this study, I have analysed the details of a series of case reports, comprising of tibial (rarest form) and fibular (commonest form) hemimelia. The cases have been managed by physical medicine experts. The subjects are managing their ADL (Activities of daily living) by means of orthoprosthesis provided to them. Though the exact etiology is unknown, probable causes are- disruptions during the critical period of embryonic limb development (i.e 4<sup>th</sup> to 7<sup>th</sup> week of IUL), vascular dysgenesis, viral infections ,trauma and environmental influences ( like smoking) and thalidomide embryopathy etc. For optimum functional result in hemimelia patients our target is – “Reconstructive surgery and prosthesis adapted to growth together with regular post operative follow up and rehabilitation.”

**KEY WORDS:** Hemimelia, Orthoprosthesis, ADL (Activities of daily living), embryopathy, Rehabilitation.

**Address for Correspondence:** Dr. Subhra Mandal, Associate Professor, Dept. of Anatomy, Medical College Kolkata, West Bengal, India. Phone No.: +919477458100

**E-Mail:** drsuvramandal@gmail.com

### Access this Article online

#### Quick Response code



DOI: 10.16965/ijar.2015.129

**Web site:** International Journal of Anatomy and Research  
ISSN 2321-4287  
[www.ijmhr.org/ijar.htm](http://www.ijmhr.org/ijar.htm)

Received: 02 Mar 2015      Accepted: 16 Mar 2015  
Peer Review: 02 Mar 2015    Published (O):31 Mar 2015  
Revised: None                      Published (P):31 Mar 2015

### INTRODUCTION

Hemimelia [1] (Greek Hemi + melos i.e half limb) is a developmental anomaly characterised by the absence or gross shortening of lower portion of one or more of the limbs. The condition may involve either or both of the bones of distal arm or leg. It is designated according to which bone is absent or defective; as Fibular, Tibial, Radial or Ulnar hemimelia. In this study I have analysed the details of a series of case reports comprising of tibial (rarest form) and fibular (commonest form) hemimelia. Any type of limb deformity in a neonate can become a challenge for the child

as he or she grows. Hand deformities can be particularly disabling as the child learns to interact with the environment through the use of hands.

The Association of Children's Prosthetic-Orthotic clinics (ACPOC) [2] estimated the incidences of congenital limb deficiencies by comparing data from diverse sources.

Tibial Hemimelia [3]: Estimated incidence is about one in one million live births; being one of the rarest congenital malformations, and certainly the most uncommon of those of lower limbs. Males are more commonly affected.

Right tibia is affected more often than left. In partial absence of tibia, more commonly the defect lies at distal end; but predominantly total absence of tibia occurs.

Fibular Hemimelia [4]: Estimated incidence is about one in forty thousand live births; being the most common congenital absence of long bone of the extremities. Slightly male preponderance is present. Unilateral affection occurs in two third of cases with right fibula affected more often than the left.

Prenatal diagnosis by USG [5] (anomaly scan at 20 weeks) is possible in hemimelia; so as to prepare for amputation after birth or for complex bone lengthening surgeries.

The cases in the present study have been managed by physical medicine and rehabilitation experts and they are managing their activities of daily living (ADL) by means of the orthoprosthesis provided to them.

### MATERIALS AND METHODS

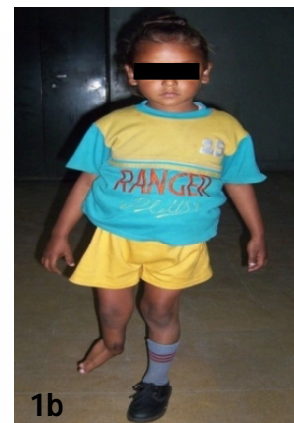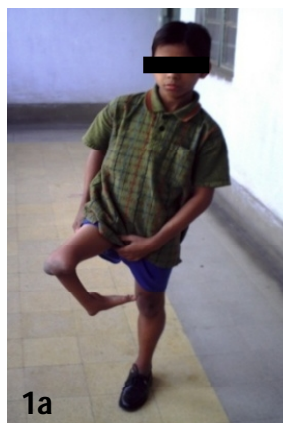The cases analysed in this case study have attended the outdoor of National Institute of Orthopedically Handicapped (NIOH), Baranagar, Kolkata, West Bengal (India). Also the excellent management of these cases has been done under the expert supervision of physiatrists present in the same institute.

#### Clinical Features-Tibial Hemimelia [6] (Photo – 1a & 1b)

1. Marked shortening of affected leg along with gross equinovarus deformity of foot.
2. Distal end of femur is hypoplastic and as tibia is absent, proximal dislocation of fibular head occurs.
3. Severe flexion contracture of knee joint leading to instability. (It's important to note weather knee joint and quadriceps are functional enough to use a Below Knee Orthosis or SYME'S prosthesis.)

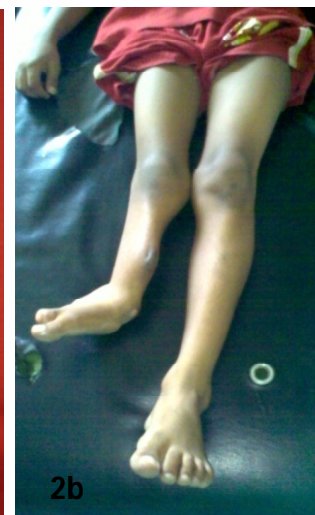**Associated syndromes:** Approximately 75% of all patients of tibial hemimelia have associated skeletal anomalies. TH may also be a part of more complex malformation syndromes like GOLLOP-WOLFGANG-COMPLEX and TRIPH-ALANGEAL THUMB POLYSYNDACTYLY SYNDROME [7]. (Distal femoral duplication, tibial

aplasia, oligoectrodactylus, toe defects and pre axial polydactyly.). DDH and Urogenital anomalies may also be associated with tibial hemimelia.



#### Clinical Features-Fibular Hemimelia [8]: (Photo – 2a, 2b)

1. Significant leg length discrepancy leading to foot or ankle instability, in unilateral cases and asymmetrical dwarfism in bilateral cases.
2. Due to absence of distal end of fibula, lateral part of ankle joint is absent causing Equino valgus deformity of affected foot.
3. Short deformed affected limb with anteromedial tibial bowing and skin dimpling over midanterior tibia.
4. Other associated findings:
  - a) Genu valgum secondary to lateral femoral condylar hypoplasia.
  - b) Deficiency of lateral rays leading to missing lateral toes.



**Associated syndromes:** Skeletal abnormalities [9] like craniosynostosis, synd-actyly, brachydactyly, oligodactyly, ectrod-actyly etc. are occasionally associated with fibular hemimelia. Rarely non skeletal malformations like anophthalmia, cardiac anomalies, renal dysplasias, spina bifida also coexist.

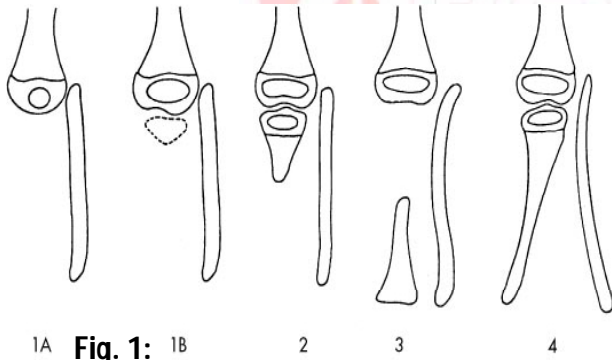
## DISCUSSION

### Classification of Hemimelia

**Tibial Hemimelia:** It is a preaxial longitudinal deficiency with variable degrees of absence of tibia. It may be total (most common), partial, unilateral or bilateral (in 30% cases)

#### Jone's Classification [3] ( Figure – 1 )

1. **Type-1:** a) Total absence of tibia, b) Congenital aplasia of tibia with intact fibula.
2. **Type-2-** Proximal tibia is present.
3. **Type-3-** Distal tibia is present (Rare).
4. **Type-4-** A divergence of distal tibia and fibula with proximal displacement of talus.



1A Fig. 1: 1B 2 3 4

**Fibular Hemimelia:** Paraxial fibular hemimelia is the most common manifestation in which only postaxial portion of the limb is affected.

#### Achterman And Kalamchi Classification [10] ( Figure – 2 ):

1. **TYPE 1 Deformity-** Hypoplasia of fibula (It is subdivided according to the percentage of fibula present) TYPE1A- The proximal fibular epiphysis is distal to the proximal tibial epiphysis and the distal fibular epiphysis is proximal to talar dome. TYPE1B- About 30 to 50% of the length of fibula is missing and there is no distal support for the ankle joint.
2. **TYPE 2 Deformity-** Complete absence of fibula.

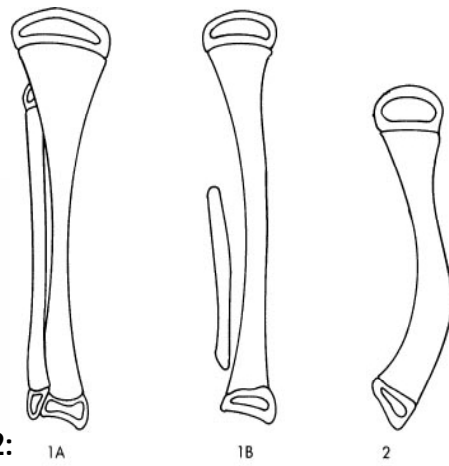


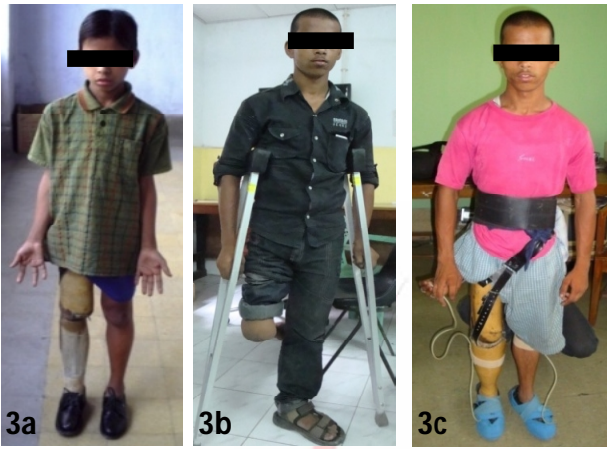Fig. 2:

**Birch Classification [11]:** It is based on affected limb length and residual foot function. This classification also determines the formulation of treatment schedule.

#### Management Of Tibial Hemimelia [12] (Photo – 3a, 3b, 3c):

Reconstructive surgery and a prosthesis adapted to growth together with regular post operative follow up are necessary for optimal functional results. According to the classification, cases are managed.

1. If the entire tibia is absent-there is often a fixed proximal and lateral positioning of fibula with severe flexion deformity. Here knee disarticulation is generally preferred, although centralisation of fibula (Brown's procedure<sup>12</sup>) combined with Syme's amputation<sup>12</sup> has been described for this situation.
2. In cases of total tibial hemimelia, with poor quadriceps function, long term results of Brown's procedure are not promising.
3. When proximal tibia is present, it can be fused to the fibula with a Syme's amputation and a very reasonable functional limb is achieved.
4. For the distal divergence- Syme's amputation has most often been performed as considerable limb length discrepancy often accompanies this condition.
5. For Type 4 deficiencies- Open reduction of ankle and lengthening is successfully reported, though the treatment is essentially on an individual basis.



### Management Of Fibular Hemimelia [13] (Photo – 4)

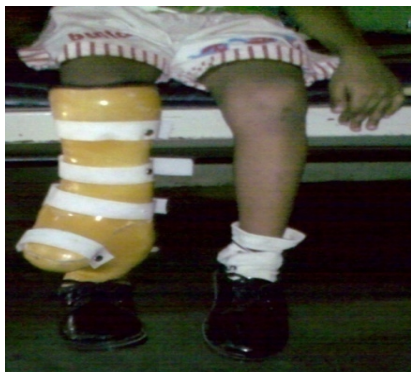Management is determined by the stability and level of foot and ankle function, as well as the degree of limb shortening. Treatment is not based on the amount of fibula present. Recommendations are-

1. Foot deformity correction—>
2. Staged serial lengthening—>
3. Overcorrection into varus deformity to avoid valgus rebound.

**Nonoperative Management- Observation [13]:** In less severe cases with minimal hypoplasia of fibula and only mild limb length discrepancy (LLD): Shoe lifts, bracings, accommodative insoles to equalize limb lengths.

### Operative Management [13]:

1. In mild projected LLD (<5cm) and in stable plantigrade foot- Contralateral (normal leg) Epiphysiodesis.
2. In LLD<30% and stable plantigrade foot with a stable ankle-Limb lengthening procedure (It involves resection of fibular anlage).
3. In LLD>30% and unstable non functional foot- Syme's or Boyd amputation done usually at one year of age.



4.

### Embryogenesis of Limb Deficiency:

Rudimentary upper and lower limb buds appear as outpouching from the ventrolateral part of embryonic foetus body wall at about 26<sup>th</sup> to 28<sup>th</sup> day of gestation. The upper limb buds appear at 26<sup>th</sup> day extending from C4 to T2 somites<sup>14</sup>. The lower limb buds develop at 28<sup>th</sup> day opposite L1 to S3 somites. Each rudimentary limb bud consists of a mass of mesenchyme covered by ectoderm. The mesenchyme is derived from lateral plate mesoderm. Limb development begins with the activation of groups of mesenchymal cells in the lateral mesoderm. Homeobox containing gene (HOX), regulate patterning of vertebral limb development. The upper limbs are fully formed by 12 weeks and lower limbs by 14 wks. During this period the muscles and nerves also develop and by 20<sup>th</sup> week, joint movement is possible.

**Aetiology [3]:** There are at least four ways in which limb deficiencies can be caused:

1. Intrauterine amputation from amniotic bands which can form a constriction around the developing limb that interferes with the growth of the developing limb. It results in any degree of damage from a minor constriction band around a limb that is otherwise normal, to a complete transverse amputation.
2. The disruption of the developing arterial supply may cause a severe ischemic aggression to the limb bud, thus producing the anomaly with variable degrees of severity and associated lesions.
3. Environmental causes have been identified in approximately 10% of malformations. Maternal infections or diseases cause uterine damage and exposure of embryo to recognised drugs, chemicals, irradiation or hyperthermia is the main culprit.
4. Errors in the genetic control<sup>15</sup> of limb development also cause hemimelia. Development of the limb is a complex phenomenon that requires the precise interaction of a large number of genes and their effects. A genetic cause is suspected when the congenital anomaly is bilateral and or symmetrical, and when there are other associated anomalies. Both tibial and

fibular deficiencies are more often sporadic and of unknown aetiology. Most cases are a part of a systemic syndrome. Although mostly inheritance mode of fibular hemimelia is autosomal recessive and that of tibial hemimelia is autosomal dominant. Careful scrutiny of the medical history and family tree as well as phenotypic details of the subjects of this case study revealed no significant defect in family lineage.

## CONCLUSION

The Usain Bolt of the paraplegic world- the Blade Runner Oscar Pistorious, was born without a fibula in both of his legs. His legs were amputated below his knee joints just before his first birthday. He took up running at 16 years, captured Gold medal at 2004 Athens Paralympics, and at 2012 London Summer Games became the first amputee to compete in the Olympics.

Sports fanatics as we Indians are, Pistorious's meteoric rise was enthusiastically applauded by us. But it is surprising, how almost none of us care to spare a little thought for all the hemimelia patients awaiting rehabilitation in our own country. This series of case studies can be concluded by words borrowed from Dr. Dror Paley, MD, FRSCS [16]., "Reconstructive surgery and a prosthesis adapted to growth together with regular post-operative follow up and rehabilitation are necessary for optimal functional results in hemimelia patients. Children who undergo early amputation are more active, have less pain, are more satisfied, have fewer procedures and incur less cost than those who undergo lengthening.

**Conflicts of Interests: None**

## REFERENCES

[1]. Mosby's Medical Dictionary, 8th edition. © 2009, Elsevier.

- [2]. The Nomenclature and Classification of Limb Anomalies; JACPOC 1971; Web.
- [3]. Turker R, Mendelson S, Ackman J, Lubicky JP. Anatomic considerations of the foot and leg in tibial hemimelia. *Journal of Pediatric Orthopedics* 1996; 16 (4):445-9.
- [4]. Gibbons PJ, Bradish CF. Fibular hemimelia: a preliminary report on management of the severe abnormality. *Journal of Pediatric Orthopaedics. Part B* 1996; 5(1): 20-6.
- [5]. Sepulveda W, Weiner E, Bridger JE, Fisk NM Prenatal diagnosis of congenital absence of the fibula. *J Ultrasound Med* 1994 Aug;13(8):655-7
- [6]. Schoenecker PL, Capelli AM, Millar EA, et al. Congenital longitudinal deficiency of the tibia. *J Bone Joint Surg (Am)* 1989; 71: 278-87.
- [7]. Göblyös P, Czeizel E, *Orv Hetil* 1995 Mar 12; 136(11):609-11
- [8]. Maffulli N, Fixsen JA. Fibular hypoplasia with absent lateral rays of the foot. *Journal of Bone & Joint Surgery -British Volume* 1991; 73(6): 1002-4.
- [9]. Sara Parada, MD; *Clinica Imagenologica Dres. Parada*, Montevideo, Uruguay.
- [10]. Achterman C, Kalamchi A. Congenital deficiency of the fibula. *Journal of Bone & Joint Surgery -British Volume* 1979; 61-B (2): 133-7.
- [11]. Herring JA, Birch JG. *The child with a limb deficiency*. Rosemont, IL: American Academy of Orthopaedic Surgeons; 1998.
- [12]. Simmons ED, Jr, Ginsburg GM, Hall JE. Brown's Procedure for Congenital Absence of Tibia Revisited. *Journal of Paediatric Orthopaedics* 1996;16(1): 85-9
- [13]. Fibular Hemimelia : Comparison of Outcome Measurements after Amputation and Lengthening in *The Journal of Bone and Joint Surgery*. 82:1732(2000)
- [14]. Langmans Medical Embryology T.W. Sadler, Chapter 10, Lippincott Williams and Wilkins, Published by Wolters Kluwer Health India Pvt. Ltd. New Delhi 2006, pp 146-49.
- [15]. Scott CI (1989). Genetic and Familial Aspects of Limb Defects with emphasis on the Lower Extremities, In:Kalamchi A(ed) *Congenital Lower Limb Deficiencies*. Springer, New York, pp 46-57
- [16]. Dror Paley, MD, FRCSC, Director, Paley Advanced Limb Lengthening Institute, West Palm Beach, Florida, USA .Principles of deformity correction (springer verlag,2002).

### How to cite this article:

Subhra Mandal, Prabir Mandal, Basundhara Ghoshal. HEMIMELIA: MYSTERY UNRAVELLED. *Int J Anat Res* 2015;3(1):958-962. DOI: 10.16965/ijar.2015.129