

## Case Report

# ASYMPTOMATIC ABSENT EPIGLOTTIS

Vaibhav Shahi \*<sup>1</sup>, Dhananjay Kumar Singh <sup>2</sup>.

Assistant Professor \* , Professor and Head <sup>2</sup>.

Department Of Anaesthesiology, Sri Guru Ram Rai Institute Of Medical Sciences & Health Sciences, Dehradun, Uttarakhand, India.

## ABSTRACT

Absence or hypoplasia of the epiglottis is a rare anomaly. Most patients, with absent or hypoplastic epiglottis, have presented, life-threatening symptoms of respiratory distress and severe aspiration in infancy or early childhood. We report a case of completely asymptomatic 30 year old female with absent epiglottis posted for modified radical mastoidectomy for chronic suppurative otitis media (CSOM).

**KEY WORDS:** Hypoplasia, Absent Epiglottis, Aspiration, Respiratory distress.

**Address for Correspondence:** Dr. Vaibhav Shahi, Department Of Anaesthesiology, Sri Guru Ram Rai Institute Of Medical Sciences & Health Sciences, Dehradun, Uttarakhand, India.

**E-Mail:** vaibhavshahi@hotmail.com

## Access this Article online

### Quick Response code



DOI: 10.16965/ijar.2015.123

**Web site:** International Journal of Anatomy and Research  
ISSN 2321-4287  
[www.ijmhr.org/ijar.htm](http://www.ijmhr.org/ijar.htm)

Received: 20 Feb 2015      Accepted: 05 Mar 2015  
Peer Review: 20 Feb 2015      Published (O):31 Mar 2015  
Revised: None      Published (P):31 Mar 2015

## INTRODUCTION

The function of the epiglottis is to prevent food and drink from falling down the airway. The epiglottis, a flap at the base of the throat, touches the back of the tongue and opens when swallowing occurs. It allows food and drink to safely pass into our digestive system. Failure of epiglottis functioning results in choking.

## CASE REPORT

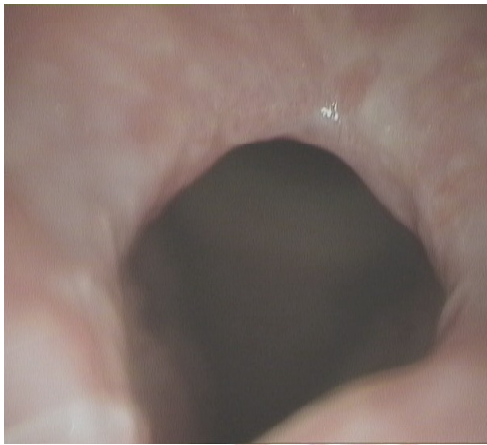
A 30 year old female patient weighing 53 Kgs, without any history of aspiration, sleep apnea or dysphagia. The patient was posted for Chronic suppurative otitis media (CSOM) under general anesthesia. She was taken for anesthesia under ASA class I. Her airway assessment was Mallampati Grade I.

In the operating room, when patient was induced for general anesthesia with Propofol (2mg/kg), Fentanyl (2mcg/kg) and direct laryn-

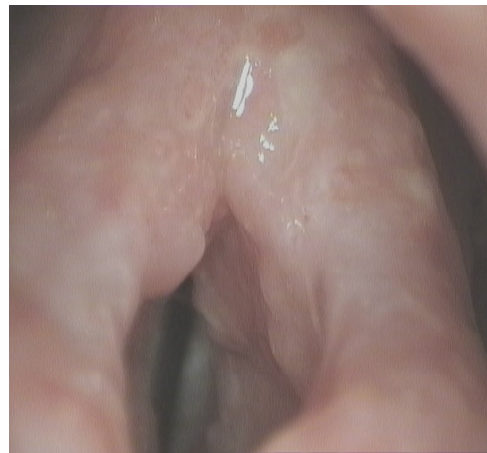gосcopy was attempted for oral endotracheal intubation with Macintosh laryngoscope with Vecuronium (0.1mg/kg) as muscle relaxant. The epiglottis was found to be absent (Figure 1). However, the vocal cords were found normally below the upper margin of the aryepiglottic folds. There was no abnormality of head, neck or other organ systems. But there was subglottic stenosis as endotracheal tube of internal diameter of 5.0 mm was also negotiated with difficulty. General anaesthesia was maintained with Oxygen and Nitrous oxide, Fentanyl, Vecuronium and Isoflorane. Neuromuscular relaxant was reversed with Neostigmine (0.05mg/kg) with Glycopyrrolate (0.01mg/kg).

Patient was monitored in post anesthesia care unit in left lateral position and there was no hemodynamic instability. No incidence of coughing and aspiration was observed in the view of absent epiglottis.

**Fig. 1:** Absent epiglottitis, vocal cord in open position.



**Fig. 2:** Absent epiglottitis, vocal cord in closed position.



## DISCUSSION AND CONCLUSION

The epiglottis, a flap at the base of the throat, touches the back of the tongue and opens when swallowing occurs. It allows food and drink to safely pass into our digestive system. Failure of functioning of the epiglottis results in choking.

Absence or hypoplasia of the epiglottis is a rare anomaly. Benjamin B et al [1] have reported the first in vivo photograph of the hypoplastic epiglottis in an infant. Previously reported cases either died shortly after birth due to multiple congenital anomalies or details of the outcome were lacking.

Most of the patients having hypoplastic epiglottis present with repeated aspiration pneumonitis. Rizk HG et al [2] have reported a case of a 26-month-old infant who was repeatedly treated for severe aspiration pneumonias that didn't resolve with gastrostomy.

Many patients present with a spectrum of symptoms like aspiration pneumonitis, OSA, hoarseness of voice, coughing during swallowing. Reyes BG et al [3] have reported a case of 3 month old girl with congenital absence of the epiglottis presents with inspiratory stridor. Over the next 8 years frank obstructive sleep apnea (OSA) developed, confirmed by polysomnography. She has no difficulty in swallowing or phonation as assessed clinically and with barium swallow.

Hypoplasia of the epiglottis diagnosed at adulthood is extremely rare, as in our case. Most patients with epiglottic hypoplasia have presented life-threatening symptoms of respiratory distress and severe aspiration in

infancy or early childhood. Roh JL [4] has reported a case of congenital epiglottic hypoplasia found in a 42-year-old man complaining of mild hoarseness and throat discomfort.

**Conflicts of Interests: None**

## REFERENCES

- [1]. Benjamin B, Dalton C. Hypoplasia of the epiglottis: case report and review. *Int J Pediatr Otorhinolaryngol* 1996 Dec 5;38(1):65-9.
- [2]. Rizk HG, Nassar M, Rohayem Z, Rassi SJ. Hypoplastic epiglottis in a non-syndromic child: a rare anomaly with serious consequences. *Int J Pediatr Otorhinolaryngol*. 2010 Aug;74(8):952-5.
- [3]. Reyes BG, Arnold JE, Brooks LJ. Congenital absence of the epiglottis and its potential role in obstructive sleep apnea. *Int J Pediatr Otorhinolaryngol*. 1994 Nov;30(3):223-6.
- [4]. Roh J L. Hypoplasia of the epiglottis in a middle-aged man. *Eur Arch Otorhinolaryngol*. 2005 Jun;262(6):470-2. Epub 2004 Nov 13.

### How to cite this article:

Vaibhav Shahi , Dhananjay Kumar Singh. ASYMPTOMATIC ABSENT EPIGLOTTIS: A CASE REPORT. *Int J Anat Res* 2015;3(1):945-946. DOI: 10.16965/ijar.2015.123