

## A COMPUTERIZED TOMOGRAPHIC STUDY OF UNCINATE PROCESS OF ETHMOID BONE

N. Vinay Kumar <sup>\*1</sup>, E. Kamala <sup>2</sup>, T. S. Guga Priya <sup>3</sup>, S. D. NalinaKumari <sup>4</sup>.

<sup>\*1,2</sup> Assistant professor, Department of Anatomy, Chennai Medical College Hospital and Research Centre, Trichy, Tamilnadu, India.

<sup>3</sup> Associate professor, Department of Anatomy, Chennai Medical College Hospital and Research Centre, Trichy, Tamilnadu, India.

<sup>4</sup> Professor and Head, Department of Anatomy, Chennai Medical College Hospital and Research Centre, Trichy, Tamilnadu, India.

### ABSTRACT

**Background:** The uncinat process is an important landmark in the anatomy of osteo-meatal complex of frontal recess which also plays a vital role in the ventilation of middle meatus and sinuses. Its superior attachment shows great anatomic variability. The aim of this study was to observe and classify superior attachment and presence of pneumatization in uncinat process.

**Materials and methods:** Computed tomographic images of paranasal region from 100 patients were studied retrospectively. In 100 patients, 54 belonged to male and 46 female and were in the age group of 11 to 75 years with an average of 32.7 years. The superior attachment of uncinat process was observed and tabulated according to Landsberg and Friedman classification and pneumatization of uncinat process was also noted. The results were analysed statistically.

**Results:** The superior attachment of uncinat process was observed in 200 sides out of 100 patients and its attachment to the agger nasi cells (type - 2) was found in 36% while its attachment to lamina papyracea (type - 1) and to middle turbinate (type - 6) were found in 19% and 20% respectively. Uncinat process ending at the junction of middle turbinate with cribriform plate (type - 4), at the ethmoid skull base (type - 5), bifurcating towards lamina papyracea and junction of middle turbinate with cribriform plate (type - 3) were seen in 2%, 8% and 5% respectively. In 11%, the superior end showed no attachment to surrounding structures. The uncinat process was pneumatized in 34 of 200 sides (17%), among which 45.5% was unilateral and 54.5% bilateral.

**Conclusion:** Preoperatively evaluating variations of uncinat process and its pneumatization helps to avoid intraoperative damage to surrounding structures. The detailed knowledge of extent of uncinat process may also help to deduce the reason for refractory chronic sinusitis.

**KEY WORDS:** Uncinat process, Osteomeatal complex, Pneumatization, Chronic rhinosinusitis, Paranasal sinuses.

**Address for Correspondence:** Dr. N. Vinay Kumar, Assistant Professor, Department of Anatomy, Chennai Medical College Hospital and Research Centre, Irungalur, Trichy 621105, Tamilnadu, India.

**E-Mail:** [vinaydr1981@gmail.com](mailto:vinaydr1981@gmail.com)

### Access this Article online

#### Quick Response code



DOI: 10.16965/ijar.2015.114

**Web site:** International Journal of Anatomy and Research  
ISSN 2321-4287  
[www.ijmhr.org/ijar.htm](http://www.ijmhr.org/ijar.htm)

Received: 07 Feb 2015

Accepted: 19 Feb 2015

Peer Review: 07 Feb 2015

Published (O): 31 Mar 2015

Revised: None

Published (P): 31 Mar 2015

### INTRODUCTION

Lateral wall of the nasal cavity consists of an osteo-meatal unit that lies in between the constant anatomical structures, the Uncinat process (UP) and bulla ethmoidalis.

Uncinat process is a thin curved bony process projecting posteroinferiorly from ethmoidal labyrinth. The concave posterosuperior free margin of uncinat parallels the anterior surface

of bulla ethmoidalis and the convex anterior margin of uncinata is in contact with lateral nasal wall. Inferiorly it ends by joining the ethmoidal process of the inferior nasal concha. During endoscopic sinus surgeries, the uppermost segment of uncinata process is a blind spot for the surgeons [1,2].

A study had classified the superior attachment of uncinata process as follows [3]: (Fig. 1)

Type 1: Insertion into the lamina papyracea (LP).

Type 2: Insertion into the posterior wall of agger nasi cell (ANC).

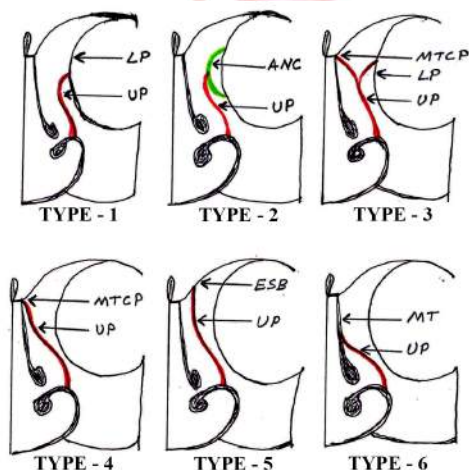
Type 3: Insertion into the lamina papyracea and junction of the middle turbinate with the cribriform plate (MTCP).

Type 4: Insertion into junction of the middle turbinate with the cribriform plate.

Type 5: Insertion into the ethmoid skull base (ESB).

Type 6: Insertion into the middle turbinate (MT).

**Fig. 1:** Showing Classification of Superior attachment of UP.



Yet another study proposed only 3 types where the uncinata process is attached superiorly to lamina papyracea or ethmoid skull base or middle turbinate while categorizing deviations and pneumatizations separately [1].

Osteo meatal region is frequently prone for anatomical variations that results in osteomeatal obstruction and blockage of mucus drainage leading to chronic rhinosinusitis. One such variation is deviation in superior attachment of uncinata process that impairs ventilation of anterior ethmoid, frontal and infundibular sinus regions leading to chronic pathology warranting uncinectomy [4]. Few

other authors opine that uncinata process probably prevents direct ventilation of sinuses with contaminated inspired air [1,5,6].

The impact of superior attachment of uncinata process in producing sino nasal pathology stands debatable and there is a lacuna in the knowledge about the incidence of various modes of its attachment in different populations. So this study was done to observe and classify superior attachment and presence of pneumatization in uncinata process.

## MATERIALS AND METHODS

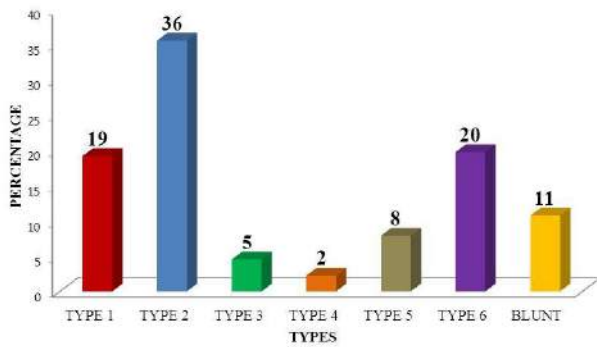
In this study, computed tomographic (CT) scans of 100 consecutive patients from the department of Radiodiagnosis were analyzed retrospectively. Among 100 Computed tomographic images, 54 belonged to male and 46 female in the age group of 11 to 75 years with an average of 32.7 years. The CT scan images of 3mm thickness were taken using GE VCT multi slice scanner. All the images were analysed using RadiAnt DICOM viewer. The CT images of patients with previous history of sinonasal surgery, carcinoma, trauma and extensive polyposis were excluded from this study.

The type of superior insertion of UP was observed in coronal CT scan images and classification was done according to the criteria of Landsberg and Friedman and tabulated. The existence of pneumatization in the uncinata process was also noted.

The results were analyzed statistically. The study was carried out after clearance from institutional ethical committee.

## RESULTS

The superior attachment of UP was noted in 200 sides and categorized (Graph – 1). Type-2 superior attachment of uncinata process was the most common variety (Fig. 2). While Type - 1 and 6 were found in equal numbers (Fig. 3 & 4). The less common varieties were type- 4, 5 and 3 (Fig. 5, 6 & 7). In 11%, blunt uncinata was noticed which showed no superior attachment to surrounding structures (Fig. 8). The uncinata process was pneumatized in 34 of 200 sides (17%) out of which it was unilateral in 45.5% (Fig. 9) and bilateral in 54.5% (Fig. 10).



Graph 1: Classification of Uncinate Process.

Fig. 2: Showing UP of Type -2.

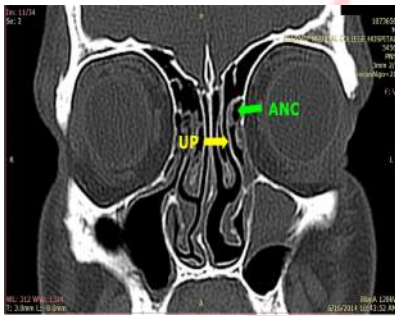


Fig. 3: Showing UP of Type -1.

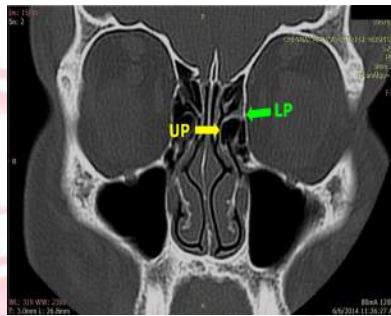


Fig. 4: Showing UP of Type -6.

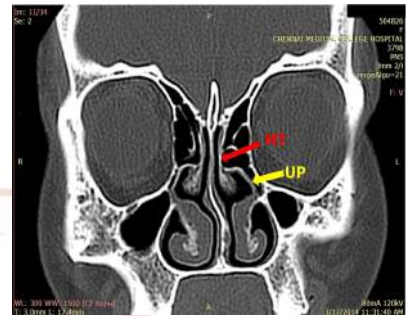


Fig. 5: Showing UP of Type -4.

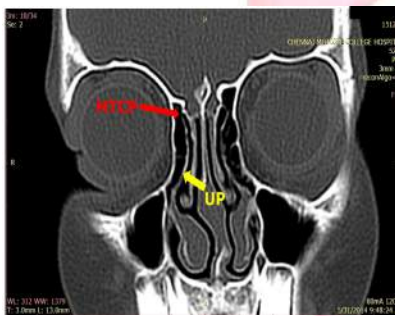


Fig. 6: Showing UP of Type -5.

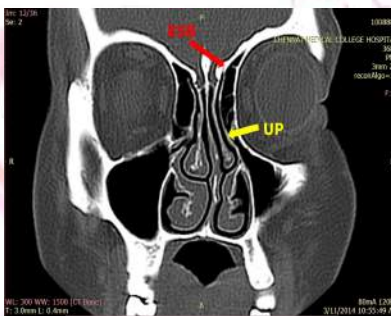


Fig. 7: Showing UP of Type -3.

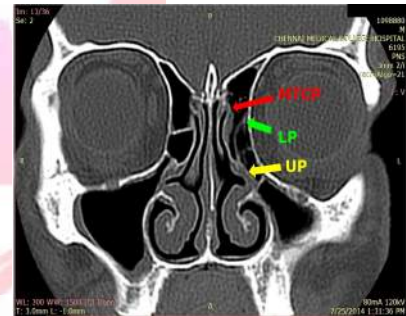


Fig. 8: Showing blunt UP (BUP).

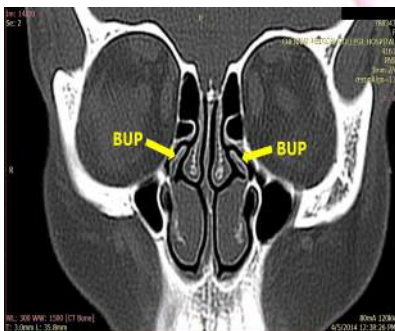


Fig. 9: Showing unilateral pneumatisation UP (ULP).

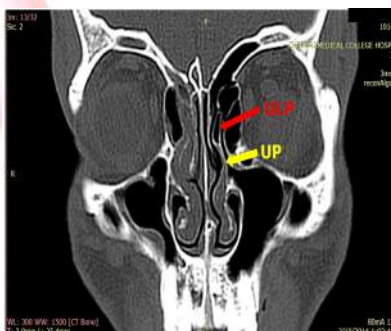


Fig. 10: Showing Bilateral pneumatisation UP (BLP).

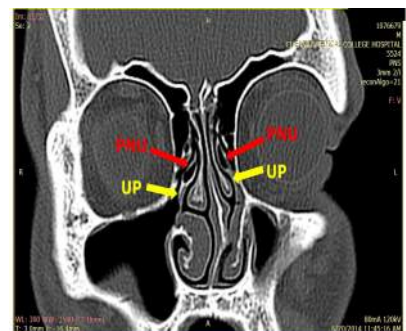


Table 1: Comparative tabulation of superior attachment of Uncinate process.

Author	Types of superior attachment of Uncinate process (in %)						
	Type -1	Type -2	Type-3	Type-4	Type-5	Type-6	Blunt
Turgut s et al [8]	63		3	12	14	8	-
Tuli et al [9]	79.8	-	-	-	16.67	3.57	-
Krzeski A et al [10]	17.83	-	-	-	33.12	14.33	-
Min Y et al [11]	54	-	-	-	24.5	21.5	-
PRESENT STUDY	19	36	5	2	8	20	11

## DISCUSSION

The uncinat process had been claimed to perform a definite functional role in the ventilatory physiology of the nasal cavity and the sinuses rather than being just a vestigial remnant [7].

The superior attachment of uncinat process had been studied and documented by few studies. In the present study apart from the six types of superior attachment a blunt type of uncinat process which had no superior attachment was also documented and compared with incidences of previous studies (Table-1).

The incidence of Pneumatization of uncinat process from previous reports ranged from 0.4%-4% and among them few studies have also described 0.5%-2.5% extensive pneumatisation of uncinat process called uncinat bulla [5,9,10,12,13]. Also a study declared that anterosuperior region was the predominant position for pneumatisation [5]. It has been proposed that pneumatisation is due to growth of agger nasi cells into the most antero-superior region of the uncinat process [14]. The very high incidence observed in this study necessitates large scale future study in the general population and its association with pathological conditions of sino nasal region.

Few studies had described deviations of uncinat process either medially or laterally leading to narrowing of the infundibulum, frontal and anterior ethmoidal recess producing impaired sinus ventilation in maxillary, frontal and ethmoidal sinuses [14-17]. Contradicting claims by some studies that deviations of uncinat process prevents contaminated air entering the sinuses [1,5,6]. Thus this challenges injudicious removal of the uncinat process during endoscopic sinus surgery.

## CONCLUSION

Almost all chronic sinusitis are associated with anatomical variation that alters ventilation. So the preoperative evaluation of variations of uncinat process and its pneumatisation helps to avoid intraoperative damage to surrounding structures that alters normal ventilation. The detailed knowledge of extent of superior attachment of uncinat process may also help

to deduce the reason for refractory chronic sinusitis in many cases.

The revolutionary changes in the surgical treatment of rhino sinusitis in recent years, particularly in endoscopic surgery, require the surgeons to have detailed knowledge of the anatomy of osteometal unit and of the large number of anatomical variants in the region. Preoperative detection of anatomic variations of the uncinat helps avoid intra-operative damage to the nasolacrimal duct, medial orbital wall, sphenopalatine artery.

**Conflicts of Interests: None**

## REFERENCES

- [1]. Anita Aramani, R.N.Karadi, Saurabh Kumar. A Study of Anatomical Variations of Osteomeatal Complex in Chronic Rhinosinusitis Patients-Ct Findings.2014;8(10):KC01 - KC04
- [2]. Soames RW. Skeletal system. In Williams PL(Ed.), Grays's anatomy. 38th edn. Edinburg: churchill livingstone.597
- [3]. Landsberg R, Friedman M. A computer-assisted anatomical study of the nasofrontal region. Laryngoscope. 2001;111:2125-2130
- [4]. Gupta, A. K., Bansal, S., & Sahini, D. Anatomy and its variations for endoscopic sinus surgery. Clin Rhinol An Int J. 2012; 5: 55-62.
- [5]. Bolger WE, Woodruff W, Parsons DS.CT demonstration of pneumatization of the uncinat process. Am J Neuroradiol.1990;11(3):552
- [6]. Groves J. and Gray R. F. Applied physiology of the nose and paranasal sinuses. In a Synopsis of otolaryngology. 4th edition. John Wright and Sons, Bristol, pp 167-168:1995.
- [7]. D. R. Nayak, R. Balakrishnan, K. Deepak Murty.Functional anatomy of the uncinat process and its role in endoscopic sinus surgery. Indian J Otolaryngol Head Neck Surg. Jan 2001; 53(1): 27-31.
- [8]. Turgut S, Ercan I, Sayin I, Ba<sup>o</sup>ak M.The relationship between frontal sinusitis and localization of the frontal sinus outflow tract: a computer-assisted anatomical and clinical study.Arch Otolaryngol Head Neck Surg. 2005 Jun;131(6):518-22.
- [9]. Tuli I P, Subhabrata sengupta, Sudeep Munjal, Santosh Prasad Kesari, Suvamoy Chakraborty. Anatomic Variations of Uncinat rocess Observed in Chronic Sinusitis. Indian J Otolaryngol Head Neck Surg.DOI 10.1007/s12070-012-0612-8
- [10]. Krzeski A, Tomaszewska E, Jakubczyk I, Galewicz-Zielinska A (2001) Anatomic variations of the lateral nasal wall in the computed tomography scans of patients with chronic rhinosinusitis. Am J Rhinol 15(6):371-375

- [11]. Min Y, Koh T, Rhee C, Han M. Clinical implications of the Uncinate process in paranasal sinusitis: radiological evaluation. *Am J Rhinol.*1995; 9(3):131-135
- [12]. Arslan H, Aydinlioglu A, Bozkurt M, Egeli E (1999) Anatomic variations of the paranasal sinuses: CT examination for endoscopic sinus surgery. *Auris Nasus Larynx* 26(1):39-48.
- [13]. Shambaugh GE. The construction of the ethmoid labyrinth. *Ann Otol Rhino/Laryngo/1907;16:771-775*
- [14]. Bolger WE, Butzin CA, Parsons DS. Paranasal sinus bony anatomic variations and mucosal abnormalities: CT analysis for endoscopic sinus surgery. *Laryngoscope* 1991; 101:56-64.
- [15]. Zinreich SJ, Kennedy DW, Rosenbaum AE, Gayler BW, Kumar AJ, Stammberger H. Paranasal sinuses: CT imaging requirements for endoscopic surgery. *Radiology* 1987; 163: 769-775.
- [16]. Stammberger H. Secretion transport. In: *Functional endoscopic sinus surgery*. Philadelphia: BC Decker, 1991: 17-46.
- [17]. Kopp W, Stammberger H, Fötter R. Special radiologic image of the paranasal sinuses. *Eur J Radiol* 1988; 8:152-156.

**How to cite this article:**

N. Vinay Kumar, E. Kamala, T. S. Guga Priya, S. D. NalinaKumari.  
A COMPUTERIZED TOMOGRAPHIC STUDY OF UNCINATE  
PROCESS OF ETHMOID BONE. *Int J Anat Res* 2015;3(1):917-921.  
**DOI:** 10.16965/ijar.2015.114