

## Case Report

# ANOMALOUS ORIGIN OF ANTERIOR INTEROSSEOUS ARTERY

Banani Kundu <sup>\*1</sup>, Abhijit Biswas <sup>2</sup>, Phalguni Srimani <sup>3</sup>, Alpana De <sup>4</sup>.

<sup>\*1</sup> Assistant Professor of Anatomy, R G Kar Medical College, Kolkata, India.

<sup>2,3</sup> Post Graduate Trainee of Anatomy, R G Kar Medical College, Kolkata, India.

<sup>4</sup> Professor and Head of the Department of Anatomy, R G Kar Medical College, Kolkata, India.

## ABSTRACT

**Background:** The Brachial Artery, usually a continuation of the axillary artery begins at the distal border of teres major and ends about a centimetre distal to the elbow joint by dividing into the radial and ulnar artery.

**Objectives:** A. To document the origin of anterior interosseous artery from brachial artery. B. To establish embryological and clinico-anatomical correlation of such variations.

**Methods:** These findings were observed after meticulous dissection of the upper limbs of both sides of a 43 year old adult male cadaver in the department of anatomy, R.G. Kar Medical College, Kolkata.

**Results:** The brachial artery present in the right limb gave a branch in the upper 1/3 of the arm from its lateral aspect. This branch of brachial artery went downwards and became deep to pronator teres and continued as the anterior interosseous artery. The brachial artery itself descended and remained superficial to pronator teres. Just below the elbow joint it underwent bifurcation into radial and ulnar artery. The subsequent course of those two arteries was normal. And there was absence of common interosseous artery. So the anterior interosseous artery instead of arising from the common interosseous artery which was the branch of the ulnar artery took origin from brachial artery.

**Conclusion:** This variation was explained in the light of embryological development and such variations were useful for physicians, surgeons, nephrologists, radiologists and interventionist in various surgical procedures and also for diagnostic and therapeutic approaches.

**KEY WORDS:** Brachial artery, Radial artery, Ulnar artery, Anterior Interosseous artery.

**Address for Correspondence:** Dr. Banani Kundu, R G Kar Medical College, 1, Khudiram Bose Sarani, Kolkata 700 004, India. Mobile: +91 9433366549 **E-Mail:** [dr.bmitra@yahoo.com](mailto:dr.bmitra@yahoo.com)

## Access this Article online

### Quick Response code



DOI: 10.16965/ijar.2015.108

**Web site:** International Journal of Anatomy and Research  
ISSN 2321-4287  
[www.ijmhr.org/ijar.htm](http://www.ijmhr.org/ijar.htm)

Received: 28 Jan 2015

Accepted: 16 Feb 2015

Peer Review: 28 Jan 2015

Published (O): 31 Mar 2015

Revised: None

Published (P): 31 Mar 2015

## BACKGROUND

Brachial artery is a continuation of the axillary artery. It begins at the distal border of the teres major muscle and ends by dividing into two branches, lateral one is the radial artery and medial one is the ulnar artery [1]. The division takes place at the level of neck of radius (one centimetre distal of the elbow joint).

Sometimes the artery divides proximally into two trunks, which may reunite. Previous study done by Compendium of Human Anatomic Variation [2] highlighted that major variations were present in about 25% of the subjects studied for the brachial artery. The artery undergoes high up division than normal and this short brachial artery may bifurcate normally or sometimes it may trifurcate into

radial (15%), ulnar (2%) and common interosseous artery. This high division may occur at any point in the normal course of the vessel, but it is more common in the middle third. The two vessels run parallel to each other to the bend of the elbow, in the usual position of the brachial artery. From this point, one branch follows the normal course of the radial artery through the forearm and the other one takes the normal course of the ulnar artery. This arrangement is considered a simple high division of the brachial artery.

Occasionally radial artery arises more proximally leaving a common trunk for ulnar and common interosseous artery [1]. Proximal division of brachial artery is due to failure of disappearance of the proximal origin of radial artery and the radial artery does not establish new connection with the main trunk near the origin of the ulnar artery [3].

High up division of the brachial artery can also be explained by Arey where he commented that, there may be persistence of vessels which normally obliterate and disappearance or failure of development of vessels which normally persist [4]. This reversal of the normal process of vascular development is largely due to altered local hemodynamic environment [5].

Finally, knowledge of variation of the branching pattern of brachial artery is noteworthy especially in the field of orthopedic, radiology, vascular and plastic surgeries [6].

In the present case report, we focused on the anatomical and embryological basis of this arterial variation and discussed its clinical significance along with relevant review of literature.

### CASE REPORT

These findings were observed during routine dissection of the upper limbs of both sides of a 43 year old adult male cadaver in the department of anatomy, R.G. Kar Medical College, Kolkata. The brachial artery present in right limb gave one branch in upper 1/3rd of arm. Then the main artery descended and

remained superficial to pronator teres. Just below the elbow joint it underwent bifurcation into radial artery laterally and ulnar artery medially. Subsequent course of those two arteries was normal. The other branch of brachial artery went downwards and became deep to pronator teres and continued as the anterior interosseous artery. So the anterior interosseous artery instead of arising from the ulnar artery it took origin from brachial artery and there was absence of common interosseous artery.

### RESULTS AND DISCUSSION

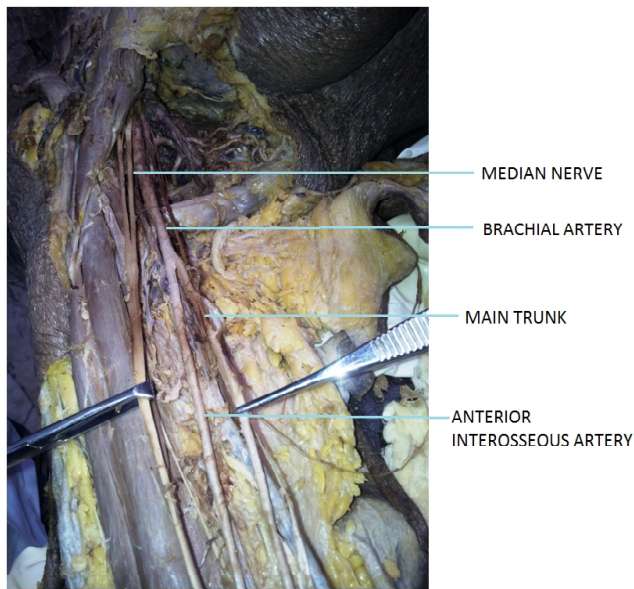
Anomalies of the upper limb arterial tree are very much common. This is mainly because of their multiple and plexiform sources, the temporal succession of emergence of principal arteries, anastomoses and periarticular networks and functional dominance followed by regression of some paths [7]. Several variations with regard to the origin and termination of the brachial artery have been reported by many earlier research workers.

High origin of radial and ulnar artery forms the highest percentage of variations of brachial artery. High origin of radial artery occurrence is 3 to 15%, as reported by different authors. The parent trunk being axillary artery in 12.5%, proximal 1/3 of brachial artery in 62.5% and middle 1/3 of brachial artery in 25% [8].

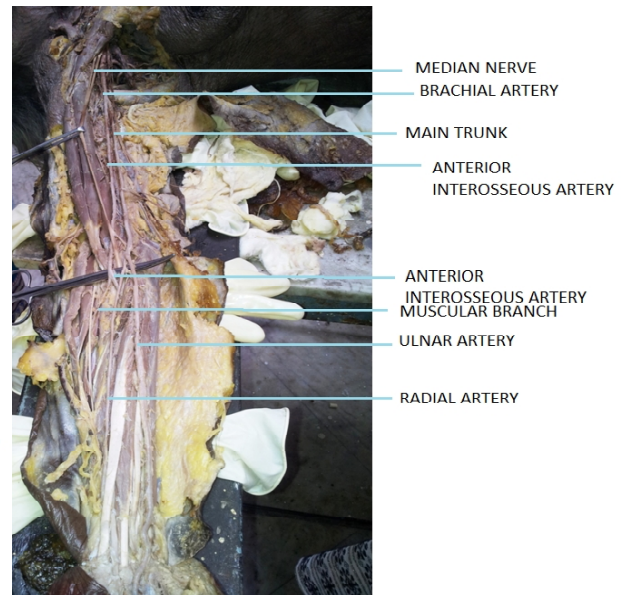
Occasionally the brachial artery divides proximally into two trunks, which may reunite. Frequently it undergoes high up division more than usual, and this short brachial artery may bifurcate as usual or it may trifurcate into radial, ulnar and common interosseous arteries. More often the radial branches arise proximally, leaving a common trunk for the ulnar and common interosseous; sometimes the ulnar artery arise proximally, the radial and common interosseous arteries forming the other division; the common interosseous artery may also arise proximally [7].

Guha et al. reported a case where in the middle of the arm brachial artery undergoes divisions into radial and ulnar arteries. This variation was associated with variant median

**Fig. 1:** Showing origin of anterior interosseous artery from brachial artery.



**Fig. 2:** Origin of the Radial, Ulnar & Anterior Interosseous arteries From Brachial artery.



nerve and absent musculocutaneous nerve [9].

**Embryological Explanation:** Every variations in the peripheral vascular anatomy can be related to genesis, regression or persistence of one or other segment of the embryologic axial artery [10].

Arey and Jurjus reported six explanations for the variations in the blood vessels of upper limb [4,11]. These are the choice of unusual paths in the primitive vascular plexus, the persistence of vessels which are usually obliterated, the disappearance of vessels which are normally retained, an incomplete development, the fusion and absorption of parts which are normally distinct and a combination of factors leading to an atypical pattern normally encountered.

The axis artery of the upper limb bud is derived from the lateral branch of the seventh intersegmental artery. Proximal part of the main trunk forms the axillary and brachial arteries and its distal part persists as the anterior interosseous artery, close to the bend of the elbow the axis artery gives rise to radial and ulnar artery which are the latest arteries to appear in the forearm from the axis artery. Probably in this case the axis artery undergoes bifurcation. It is important to mention that the normal vascular development including the patterning of the

blood vessels is influenced greatly by the local hemodynamic factors. Altered hemodynamic environment may give rise to variant patterning of blood vessels [6]. In this case also due to difference of flow gradient the lateral division of the axis artery gradually became narrower and it formed the anterior interosseous artery. The medial branch became dominant and it was continued as the brachial artery and gave two more branches the radial and ulnar artery.

## CONCLUSION

Thus any factors affecting during development of the limb vessels will lead to anomalies in the level of division of major arteries. Knowledge regarding such variations are very much important for the radiologists, cardiologists, orthopaedic and vascular surgeon. Diagnostically this type of variation may disturb the evaluation of angiographic images. Surgeon should be aware of such variation before doing any upper limb surgery to prevent injury, thrombosis specially in patients requiring dialysis or arteriography.

We hope that our study has provided valuable data to the clinicians and anatomists by enhancing their knowledge regarding the variation of the blood vessels of the upper limb as it helps to avoid serious complications in surgery and angiographic procedures.



## ACKNOWLEDGEMENT

The authors express their heartfelt gratitude to all the members of the Department of Anatomy, R G Kar Medical College, Kolkata for their kind support, cooperation and generosity in the conduct of this study.

**Conflicts of Interests: None**

## REFERENCES

- [1]. Standring S. Gray's anatomy: The anatomical basis of clinical practice. In: Upper arm Chapter 50. Spain: 39th edn. 2006; pp.856, Elsevier Churchill Livingstone, New York.
- [2]. Bergman RA, Thompson SA, Afifi AK, Saadeh FA. Compendium of human anatomic variation. Baltimore: Urban & Schwarzenberg; 1988.
- [3]. Shewale SN, Sukre SB, Diwan CV. Bifurcation of brachial artery at its commencement: A case report. Biomedical research. 2012;23(3):453-456.
- [4]. Arey LB. Developmental Anatomy. 6th Ed. Philadelphia, W.B. Saunders. 1957;375-377.
- [5]. Rodriguez-Baeza A, Nebot J, Ferreira B, Reina F, Perez J, Sanudo JR, Roig M. An anatomical study and ontogenetic explanation of 23 cases with variations in the main pattern of the human brachioantebrachial arteries. J Anat. 1995;187:473-479.
- [6]. Gonzalez-Compta X. Origin of the radial artery from the axillary artery and associated hand vascular anomalies. Journal of Hand Surg. 1991;16A:293-296.
- [7]. Williams PL, Bannister LH, Berry MM, Collins P, Dyson M, Dussek JE, Ferguson MW, eds. Gray's Anatomy. 38th Ed., London, Churchill Livingstone. 1999;319,1539.
- [8]. Teli C, K N Nilesh, N Paarthipan. A case report of high division and variation in brachial artery branching pattern. IOSR Journal of Dental and Medical Sciences. Jan-Feb2013;3(6):68-70.
- [9]. Guha R, Palit S. A rare variation of anomalous median nerve with absent musculocutaneous nerve and high up division of brachial artery. J Interacad. 2005;9:398-403.
- [10]. Anuradha L, Prabhu LV, Kumar A. Report on an anomalous pattern in the upper limb with its anatomical and clinical implication. J Anat Soc India, 2001;50(1):69-98.
- [11]. Jurjus A, Sfeir R, Bezirdjian R. Unusual variation of the arterial pattern of the human upper limb. Anat Rec. 1986;215:82-83.

### How to cite this article:

Banani Kundu, Abhijit Biswas, Phalguni Srimani, Alpana De. ANOMALOUS ORIGIN OF ANTERIOR INTEROSSEOUS ARTERY. Int J Anat Res 2015;3(1):906-909. DOI: 10.16965/ijar.2015.108