

## MORPHOMETRIC MEASUREMENT OF MENTAL FORAMEN IN DRY HUMAN MANDIBLE IN NORTH INDIAN POPULATION

Rakesh Kumar Shukla <sup>1</sup>, Prerna Gupta <sup>\*2</sup>, Muktyaz Hussein <sup>3</sup>, Fida Hussain <sup>4</sup>, Abhishek Bahadur Singh <sup>5</sup>.

<sup>1</sup> PG Student, Department of Anatomy, Integral Institute of Medical Sciences and Research, Lucknow, U.P. India.

<sup>\*2</sup> Assistant Professor, Department of Anatomy, Integral Institute of Medical Sciences and Research, Lucknow, U.P. India.

<sup>3</sup> Assistant Professor, Department of Anatomy, Govt. Medical College, Ambedkar Nagar, U.P. India.

<sup>4</sup> Professor, Department of Anatomy, Integral Institute of Medical Sciences and Research, Lucknow, U.P. India

<sup>5</sup> Senior Resident, Department of Otorhinolarygology, King George Medical University, Lucknow, U.P. India.

### ABSTRACT

**Background:** The mental foramen is one of the two holes ("foramina") located on the anterior surface of the mandible. It permits passage of the mental nerve and vessels. The mental foramen descends slightly in edentulous individuals.

**Methods:** The present study was carried out in the department of anatomy on 70 Adult North Indian dry Mandibles of unknown age and sex which were obtained from the osteology section of Integral Institute of Medical Sciences and Research & King George medical university. The Mandibles were observed macroscopically for the presence of mental foramen.

**Results:** In our study we observed that the oval shape of mental foramen was 87.1% on right side and 88.6% on left side. Round mental foramen was observed to be 12.9% on the right side and 11.4% on left side. The Position of Mental foramen in relation to borders left side were found Central (87.1%), upper border (7.1%), lower side (5.7%) and right side Central (85.7%), upper border (10%) and lower side (4.3%).

**Conclusions:** Knowledge of the mental foramen and its variation in different population is essential for dentists, orthopedicians and anatomists. A future prospect of interest lies in their possible contribution to the maxillofacial anthropologic characteristic identification for different population and races.

**KEY WORDS:** Mental foramen, Morphometric, Measurement, Human Mandible.

**Address for Correspondence:** Dr. Prerna Gupta, Assistant Professor, Department of Anatomy, Integral Institute of Medical Sciences and Research, Lucknow, U.P. India. Contact No: +919451793415, +919721504474. **E-Mail:** [dr.prerna2009@gmail.com](mailto:dr.prerna2009@gmail.com)

### Access this Article online

#### Quick Response code



DOI: 10.16965/ijar.2015.106

**Web site:** International Journal of Anatomy and Research  
ISSN 2321-4287  
[www.ijmhr.org/ijar.htm](http://www.ijmhr.org/ijar.htm)

Received: 28 Jan 2015

Accepted: 16 Feb 2015

Peer Review: 28 Jan 2015

Published (O):31 Mar 2015

Revised: None

Published (P):31 Mar 2015

### INTRODUCTION

Quantification of skeletal data has been shown to be an effective and reliable method of demonstration of variation in location, orientation, shape, appearance, and relation with surrounding landmarks as well as monitoring &

interpreting the maximum possible location and dimensions. Despite numerous study has been conducted on morphometric measurement of mental foramen by Igbigbi P. S. & Lebona S [1], Santini A. and Land M [2] and Siddiqui AU et al [3] in the region of Africa, Britain, China, India,

USA and other parts of country, but less research has been done in the region of North Indian population, specially U.P. The mental foramen (MF) is situated on the anterolateral aspect of the body of mandible. It gives path to mental nerve and vessels [4,5]. Variations of the mental foramen are often encountered ranging from difference in shape and positions by Agarwal D. R. and Gupta S. B [6] to presence of accessory foramen [7] or even complete absence in some cases [8,9]. The mental nerve and vessels radiate through the mental foramen and supply sensory innervation and blood supply to the soft tissues of the chin, lower lip and gingival on the ipsilateral side of the mandible. Any foramen which is in addition to MF is considered as an Accessory Mental Foramen [7] and it is usually located below the 1st molar teeth by Cag Iranakaya LB and Kansu [10]. This accessory mental foramen may transmit the branches of the mental nerve. The precise knowledge on the variations in the position, shape, and the size of the mental foramen and the presence of the accessory mental foramen would be of much use for dental surgeons while they do surgical procedures on the mandible, such as the Curettage of the premolars, Filling procedures, Dental implants, Root Canal Treatments (RCT), Orthognatic surgeries, etc by Udhaya K. et al [11]. Gershenson et al. in 1986 examined 525 dry mandibles focusing on variation, shape and location of the mental foramen related to the teeth, reported that 4.3% mandibles had double mental foramina and 0.7% mandibles had triple mental foramina. They found one mandible that had four mental foramina on one side 0.1% [12].

Furthermore, the radiographic assessments result in a high percentage of false negative findings. These false findings can cause sensory dysfunction due to inferior alveolar nerve damage in the foraminal area. The foramen may occasionally misdiagnose with a radiolucent lesion in the apical area of the mandibular premolar teeth. Additionally, local anesthesia of the terminal incisive branches of the inferior alveolar and mental nerves can be obtained effectively if the mental foramen is correctly identified. Therefore, computerized tomography (CT) is more accurate for detecting the mental

foramen than conventional radiographs reported by Sonick M. et al [13]. Therefore, the current study involves in analyzing the morphology and morphometry of the mental foramen in a dry adult mandibles in north Indian population, which may be useful for future implication in our north Indian population.

**AIMS AND OBJECTIVES:** The knowledge of the mental foramen is very important in clinical dentistry and in surgical procedures which involve that area to avoid nerve injury during surgery in the foraminal area. The aim of this study was to determine the following parameter in the dry human mandible of north Indian population and to compare our findings with international values.

1. Location of mental foramen.
2. Shape and size of mental foramen.
3. Relation of mental foramen with surrounding landmarks.
4. Relation of mental foramen with Mandibular teeth.

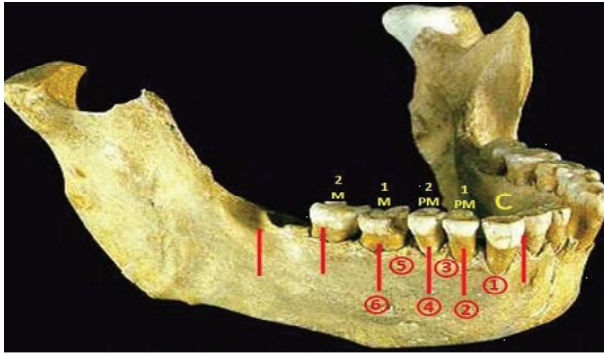
## **MATERIALS AND METHODS**

This study was conducted in the Department of anatomy of Integral Institute of Medical Sciences and Research & King George medical universities on 70 Adult North Indian population dry Mandible of unknown age and sex. Preferably 9 human adult dry Mandible obtained from the Department of anatomy of Integral Institute of Medical Sciences and Research, 31 human adult dry Mandible obtained from Department of Anatomy & King George medical university Lucknow, U.P. and 30 human adult dry Mandible obtained from UP RIMS & R, Saifai, U.P are examined for Morphometric measurement of mental foramen. Damaged and diseased Mandibles were excluded from the study. The Mandibles were observed macroscopically for the presence of mental foramen. The data obtained was tabulated and analyzed by descriptive statistics.

**Method of collection of data:** The number, shape and the orientation of the MF were determined by a visual examination. The positions of the mental foramens were measured with respect to the teeth, for which we followed the Tebo and Telford classification [14].



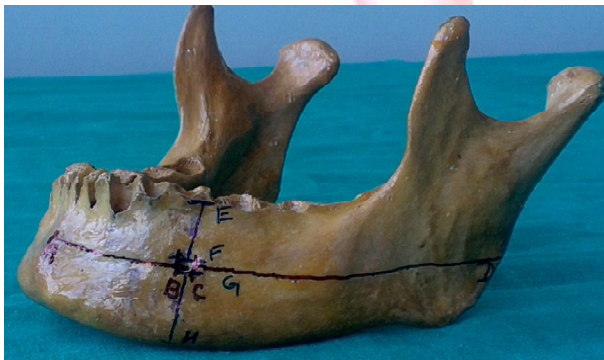
**Fig. 1:** Position of Mental Foramen in relation to teeth (Tebbo & Telford Classification).



- 1-Foramen lying on a longitudinal axis of passing between the canine and first premolar.
- 2-Foramen lying on the longitudinal axis of the first premolar.
- 3-Foramen lying on the longitudinal axis passing between first and second premolar
- 4-Foramen lying on the longitudinal axis of the second premolar
- 5-Foramen lying on the longitudinal axis passing between the second premolar and first molar.
- 6-Foramen lying on the longitudinal axis of first molar.

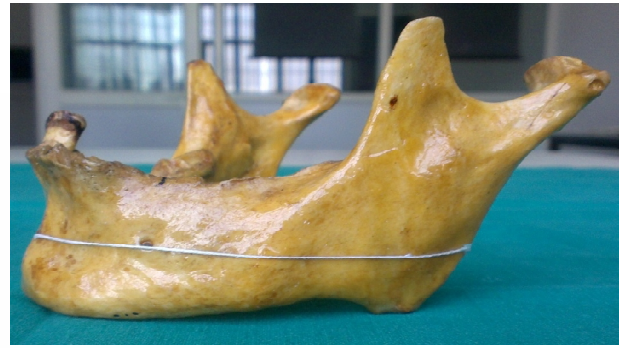The positions of the mental foramens with respect to the borders were also measured with the help of a digital vernier caliper, at a measuring accuracy of 0.01mm. From the transverse and the vertical diameters which were obtained, the size of the MF was calculated in Figure 2.

**Fig. 2:** Position of Mental Foramen & its size calculated by transverse & vertical measurements of mandible in relation to borders.



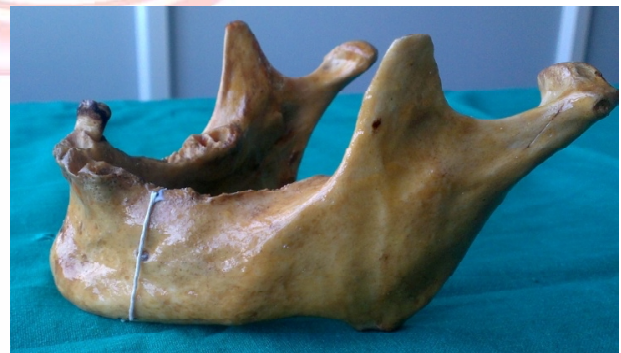- AD-Distance from symphysis menti to posterior border of mandible.
- AB- Distance from symphysis menti to anterior margin of MF.
- CD- Distance from posterior margin of MF to posterior border of mandible.
- BC-Transverse Diameter (TD) of MF.
- EH- Distance from alveolar margin to base of mandible.
- EF- Distance from alveolar margin to superior margin of MF
- GH- Distance from inferior margin of MF to base of mandible.
- FG-Vertical Diameter (VD) of MF

**Fig. 3:** Position of Mental Foramen & its size calculated by transverse measurements of mandible in relation to borders.



The transverse diameters were measured by using various parameters viz., the distance from the symphysis menti, the posterior border of the mandible, the base of the mandible and from the alveolar margins by use of digital vernier caliper. Thread was placed on reference point A and B and cut the thread at point B, placed the thread over Glass Slab, such that complete length of thread is in a linear shape and measured the two end of thread. This has given the measurement of mandible from symphysis menti to the anterior margin of mental foramen.

**Fig. 4:** Position of Mental Foramen & its size calculated by vertical measurements of mandible in relation to borders.



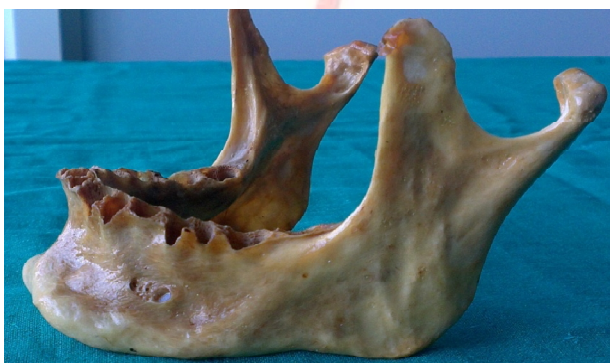Similar method employed for measurement of the reference point CD, AD, EF, GH and EH.

The mandible measurements was taken on both sides, that was right and left sides and then the average of both was to be considered for statistical analysis.

The mandible measurement was obtained with sliding calliper to the nearest millimeters (mm) as per standard anthropological conventions and then the morphometric analysis of mental foramen is calculated. All the measurements were taken after taking biometric training and

by single observer to avoid any inter-observer error. The SPSS, version 16.0 software were used for the statistical analysis, to find out the minimum and the maximum incidences, the mean and the standard deviation. For the accessory mental foramen, the number, location, shape, size and the orientation were recorded (Fig-5).

**Fig. 5:** Left side of a mandible showing two mental foramen. MF-Mental Foramen and AMF-Accessory Mental Foramen.



**RESULTS AND TABLES**

**Table 1:** Statistical analysis of position of MF and its size in relation with borders Left side.

	N	Minimum	Maximum	Mean	Std. Deviation
AB	70	21.34	62	26.19	4.79
CD	70	55.93	73.93	65.05	4.14
AD	70	82.43	106.52	94.33	5.07
EF	70	3.63	40.5	10.69	4.83
GH	70	10.66	16.93	13.88	1.59
EH	70	19.1	35.19	27.07	3.6

The statistical analysis of position of MF and its size in relation with borders in left side is presented in the Table-1. The distance of AB was 26.19±4.79 mm in left side. However, CD was 65.05±4.14 mm in left side. The distance of AD was observed to be 94.33±5.07 mm in left side (Table-1).

**Table 2:** Statistical analysis of position of MF and its size in relation with borders -Right side.

	N	Minimum	Maximum	Mean	Std. Deviation
AB	70	2.79	30.2	25.72	3.24
CD	70	56.22	73.85	64.61	4.4
AD	70	84.5	105.82	94.22	4.87
EF	70	3.56	16.48	10.84	2.94
GH	70	10.26	96.07	15.02	9.94
EH	70	19.77	55.29	27.74	4.97

The statistical analysis of position of MF and its size in relation with borders in right side is presented in the Table-2. The distance of AB was 26.72±3.24 mm in right side. However, CD was 64.61±4.40 mm in right side. The distance of AD was observed to be 94.22±4.87 mm in right side (Table2).

**Table 3:** Position of Mental foramen in relation to borders-Left side.

	Frequency	Percent	Valid Percent	Cumulative Percent
Lower border	4	5.7	5.7	5.7
Central	61	87.1	87.1	92.9
Upper border	5	7.1	7.1	100
Total	70	100	100	

Central (87.1%) was commonest side in left side followed by upper border (7.1%) and lower side (5.7%) (Table3).

**Table 4:** Position of Mental foramen in relation to borders-Right side.

	Frequency	Percent	Valid Percent	Cumulative Percent
Lower border	3	4.3	4.3	4.3
Central	60	85.7	85.7	90
Upper border	7	10	10	100
Total	70	100	100	

Central (85.7%) was commonest side in right side followed by upper border (10%) and lower side (4.3%) (Table 4).

**DISCUSSION**

In the present study we found the location of mental foramen lying in longitudinal axis to 2<sup>nd</sup> premolar in majority about 52.9 % cases, which indicate its maximum possible place, other locations were, 2.9 % lying in longitudinal axis of 1<sup>st</sup> pre molar, 11.3% lying in between 1<sup>st</sup> and 2<sup>nd</sup> premolar and 32.9% lying between 2<sup>nd</sup> premolar and 1<sup>st</sup> molar in left side of mandible. Whereas 4.3 % lying in longitudinal axis of 1<sup>st</sup> premolar, 14.3% lying in between 1<sup>st</sup> and 2<sup>nd</sup> premolar and 28.5% lying between 2<sup>nd</sup> premolar and 1<sup>st</sup> molar in right side of mandible. Others authors worked on this subject and support our study are as mention. Fishel D et al [15] reported in the horizontal plane that 70%of the mental foramina were found to be located between the two premolars and 22% were in the apical area



of the premolars. Wang T.-M. et al [16] who reported that the location of the mental foramen below the apex of the lower second premolar (relation IV: 58.98%) was the most common. Gershenson A. et al [12] said 43.66% of MF was located in front of the apex of the root of the second premolar.

Santini A. et al [2] result indicates the modal position of the foramen in the Chinese sample was along the long axis of the second premolar, whereas in the British sample it lay between the apices of the first and second premolar.

Phillips John L. et al [5] reported. Panoramic radiographs were made of 75 dry, adult human mandibles. The size and position of the mental foramen in relation to the second premolar was determined. Jasser Al NM et al [17] reported the commonest position of the mental foramen was in line with the longitudinal axis of the second premolar (45.3%) followed closely by location between the first premolars and second premolars (42.7%). Agarwal et al [6] said in most of the cases the foramen situated in the line with the longitudinal axis of the 2nd premolar tooth. Ahmet et al [18] found the most common anterior-posterior position of the MF was bilaterally symmetrical and located on the same vertical line with the long axis of the lower second premolar. In this study we found mental foramen was centrally placed, about 87.1% in left side and 85.7% in right side of mandible. Other location were 5.7 % toward lower border and 7.1% toward upper border in left side of mandible, where as 4.3 % toward lower border and 10.0 % toward upper border in right side of mandible.

Mbajjorgu EF et al [19] said in the vertical plane, the mental foramen lay slightly below the midpoint of the distance between the lower border of the mandible and the alveolar margin (44.1% and 45.5% for the right and left sides respectively). Udhaya k et al [11] reported mental foramen located midway between the inferior margin and the alveolar margin of the mandible. In this study I found the distance from the symphysis menti to the anterior margin of the mental foramen was 26.19±4.79 mm in left side & 25.72±3.24 mm in right side, the distance from the posterior margin of the mental foramen to

the posterior border of the mandible was 65.05±4.14 mm in left side & 64.61±4.40 mm in right side, the distance from the symphysis menti to the posterior border of the mandible was 94.33±5.07 mm in left side & 94.22±4.87 mm in right side, the distance from the alveolar margin to the superior margin of the mental foramen was 10.69±4.83 mm in left side & 10.84±2.94 mm in right side, the distance from the inferior margin of the mental foramen to the base of the mandible was 13.88±1.59 mm in left side & 15.02±9.94 mm in right side and the distance from the alveolar margin to the base of the mandible was 27.07±3.60 mm in left side & 27.74±4.97 mm in right side of mandible. Wang T.-M. et al [16] reported on average, the distance between the most anterior portion of the anterior border of the mental foramen and the mandibular symphysis menti was 28.06 mm, between the most anterior portion of the anterior border of the mental foramen and the posterior border of the ramus was 74.14 mm, between the inferior border of the mental foramen and the lower border of the mandibular body was 14.70 mm, between the superior border of the mental foramen and the bottom of the lower second premolar socket was 2.50 mm.

The distance across the mental foramen between the alveolar crest and the lower border of the mandibular body was 30.29 mm. Ilayperuma, I. et al [20] said, that the mental foramen was located 24.87 ± 6.07 mm (right side) and 24.77 ± 6.07mm (left side) lateral to the symphysis menti. In this study we found the orientation (direction in which mental foramen open) of mental foramen was posterior superior direction in high majority, about 72.9% in left side and 67.1% in right of mandible. Orientation of mental foramen was in horizontal direction in minority about, 27.1% in left side and 32.9% in right of mandible. In this study I found five accessory mental foramen. Three on left side and two on right side of mandible. Which indicate its occurrence of 4.3% in left side of mandible and 2.9 % in right side of mandible. Total incidence of Accessory mental foramen was 7.2 % and bilateral single mental foramen was present in 92.8% of mandible. Naitoh Munetaka et al [21] result shows the accessory mental foramen was observed in 7% of patients.

Shankland WE 2<sup>nd</sup> [22] said 6.62% of the mandibles possessed accessory mental foramina. Pokhrel R. et al [23] said accessory mental foramen was found in 7.22% sides, bilaterally in 4.81% and was more common in males and in right side.

## CONCLUSION

The recent trend of replacement of missing teeth by dental implants and the increasing frequency of orthognathic surgeries have highlighted the clinical significance of the mental foramen. Mental foramen variation often remains unnoticed and undiagnosed. In order to obtain effective nerve block and to avoid post procedural neurovascular complications in the mental region, particular attention should be paid to the morphology of the mental foramen.

This study helps in understanding the probability of the location, orientation, shape, appearance, relation with surrounding landmark, relation with mandibular teeth of mental foramen in the region of U.P. A prior CT scan can elucidate jaw structures and prevent patient morbidity. Therefore, a detailed knowledge of the mental foramen and it's variation in different population is essential for dentists, orthopedicians and anatomists. A future prospect of interest lies in their possible contribution to the maxillofacial anthropologic characteristic identification for different population and races.

**Conflicts of Interests: None**

## REFERENCES

- [1]. Igbigbi P. S. and Lebona S. The position and dimensions of the mental foramen in adult Malawian mandibles, West African Journal of Medicine. 2005;24(3):184–189.
- [2]. Santini A. and Land M. A comparison of the position of the mental foramen in Chinese and British mandibles. Acta Anatomica 1990;137(3):208–212.
- [3]. Siddiqui Abu Ubaida, Daimi Syed Rehan, Mishra Parmatama Prasad, Doshi Suraj Sudarshan, Date Jay Yashwant, Khurana Guruditta. Morphological and morphometric analysis of mental foramen utilizing various assessment parameters in dry human mandibles. International Journal of Students Research 2011;1(1).
- [4]. Agthong S, Huanmanop T, Chentanez V. Anatomical variation of the supraorbital, infraorbital, and mental foramina related to gender and side. J oral maxillofac surg. 2005;63:800-904.
- [5]. Phillips John L., Weller R. Norman, Kulild James C. The mental foramen: Part III. Size and position on panoramic radiographs. Elsevier publication. Journal of Endodontics 1992;18(8):383-386.
- [6]. Agarwal D. R., Gupta S. B. Morphometric analysis of mental foramen in human mandibles of south Gujarat. People's Journal of Scientific Research 2011;4(1):15–18.
- [7]. Sawyer, Kiely MI, Pyle Ma. The frequency of accessory mental foramina in four ethnic groups. Arch oral boil. 1998;43:417-20.
- [8]. Defreitas V., Mdeira M. C., Tsledofilhs J. L., and Chagas C. F. Absence of the mental foramen in dry human mandible. Acta Anatomica 1979;104(3):353–355.
- [9]. Hasan T., Fauzi M., and Hasan. Bilateral absence of mental foramen, a rare Variation. International Journal of Anatomical Variations 2010;3:167–169.
- [10]. Cag Irankaya LB and Kansu H. An accessory mental foramen: a case report. J Contemp Dent Pract. 2008;9:98-104.
- [11]. Udhaya K., Saraladevi K.V., Sridhar J. The morphometric analysis of mental foramen in dry human mandible: a case report Journal of Clinical and Diagnostic Research. 2013 Aug;7(8):1547-1551.
- [12]. Gershenson A., Nathan H., Luchansky E. Mental Foramen and Mental Nerve: Changes with Age. Acta Anatomica 1986;126:21–28.
- [13]. Sonick M, Abrahams J, Faiella Ra. A comparison of the accuracy of periapical, panoramic, and computerized tomographic radiographs in locating the mandibular canal. Int. J oral maxillofac implants 1994;9:455-68.
- [14]. Tebo HG, Telford IR. An analysis of the variations in position of the mental foramen. Anat Rec. 1950;107:61–66.
- [15]. Fishel D., Buchner A., Hershkowith A., Kaffe I. Roentgenologic study of the mental foramen. Original Research Article, Elsevier Publication, Oral Surgery, Oral Medicine, Oral Pathology 1976;41(5):682-686.
- [16]. Wang T.-M., Shif C., Liu J.-C., Kuo K.-J., A Clinical and Anatomical Study of the Location of the Mental Foramen in Adult Chinese Mandibles. Acta Anatomica 1986;126:29–33.
- [17]. Jasser NM Al and Nwoku AL done Radiographic study of the mental foramen in a selected Saudi population -Dentomaxillofacial Radiology 1998;27:341-343.
- [18]. Ahmet Ercan Sekerci, Halil Sahman, Yildiray Sisman, Yusuf Aksu. Morphometric analysis of the mental foramen in a Turkish population based on multi-slice computed tomography. J Oral Maxillofac Radiol 2013;1:2-7.
- [19]. Mbajjorgu EF, Mawera G, Asala SA, Zivanovic S. Position of the mental foramen in adult black Zimbabwean mandibles: a clinical anatomical study. The Central African Journal of Medicine. 1998;44(2):24-30.

- [20]. Ilayperuma, I.; Nanayakkara, G. & Palahepitiya, N. Morphometric analysis of the mental foramen in adult Sri Lankan mandibles. *Int. J. Morphol.*, 2009;27(4):1019-1024.
- [21]. Naitoh Munetaka, Hiraiwa Yuichiro, Aimiya Hidetoshi, Gotoh Kenichi, Aiji Eiichiro. Accessory mental foramen assessment using cone-beam computed tomography. Original Research Article by Elsevier Publication. *Oral Surgery, Oral Medicine, Oral Pathology, Oral Radiology, and Endodontology* 2009;107(2):289-294.
- [22]. Shankland WE 2nd. The position of the mental foramen in Asian Indians. *The Journal of Oral Implantology* 1994;20(2):118-123.
- [23]. Pokhrel R, Bhatnagar R. Position and number of mental foramen in dry human mandibles: Comparison with respect to sides and sexes. *OA Anatomy* 2013 Dec 01; 1(4):31.

**How to cite this article:**

Rakesh Kumar Shukla, Perna Gupta, Muktyaz Hussein, Fida Hussain, Abhishek Bahadur Singh. MORPHOMETRIC MEASUREMENT OF MENTAL FORAMEN IN DRY HUMAN MANDIBLE IN NORTH INDIAN POPULATION. *Int J Anat Res* 2015;3(1):899-905.  
**DOI:** 10.16965/ijar.2015.106