

## Case Report

# ANOMALOUS LEFT VERTEBRAL ARTERY FROM ARCH OF AORTA-A THOUGHT FOR SURGEONS?

Deepa Somanath <sup>\*1</sup>, Shivali Srivastava <sup>2</sup>.

<sup>\*1</sup> Assistant Professor, Dept. of Anatomy, Sri Manakula Vinayagar Medical College, Puducherry, India.

<sup>2</sup> Post Graduate Student, Dept. of Anatomy, Sri Manakula Vinayagar Medical College, Puducherry, India.

## ABSTRACT

Arterial variations in the branching pattern of arch of aorta are uncommon and may occur as a result of developmental changes in the fusion and absorption of various pharyngeal arch arteries into the aortic sac. The present case report describes a finding in a male cadaver aged between 60- 65 years about the origin of left vertebral artery directly from the arch of aorta. Such variations should be kept in mind during surgical procedures in the superior mediastinum.

**KEYWORDS:** Left vertebral artery, Arch of aorta, Arch artery, Anomaly.

**Address for Correspondence:** Dr. Deepa Somanath, Assistant Professor, Dept. of Anatomy, Sri Manakula Vinayagar Medical College, Madagadipet, Puducherry- 605 107, India.

**E-Mail:** [deepa.somanath@gmail.com](mailto:deepa.somanath@gmail.com)

## Access this Article online

### Quick Response code



DOI: 10.16965/ijar.2015.102

**Web site:** International Journal of Anatomy and Research  
ISSN 2321-4287  
[www.ijmhr.org/ijar.htm](http://www.ijmhr.org/ijar.htm)

Received: 08 Jan 2015

Accepted: 04 Feb 2015

Peer Review: 08 Jan 2015

Published (O):28 Feb 2015

Revised: None

Published (P):31 Mar 2015

## INTRODUCTION

The vertebral artery contributes to the blood supply of the brain by helping in the formation of circle of Willis. It forms a major part of the posterior cerebral circulation.

60- 85% of the population have three direct branches from the arch of aorta, namely brachiocephalic trunk, left common carotid and left subclavian artery. Sometimes, the arch of aorta can give rise to the vertebral arteries of one or both sides, commonly the left side.

The vertebral artery on either side usually arises from the first part of the subclavian artery, medial to the scalenus anterior muscle. It ascends vertically to enter the foramen transversarium of sixth cervical vertebra and

traverses all cervical foramina transversaria up to the first cervical vertebra (atlas). This part of the artery from its origin to the entry into the foramen transversarium is called the pre vertebral segment. Then the artery lies on the posterior arch of the atlas in the sub occipital triangle, following which it pierces the atlanto-occipital membrane and dura mater. The vertebral artery then enters the foramen magnum and unites with the corresponding artery of the opposite side to form the basilar artery which in turn terminates as two posterior cerebral arteries [1].

The present case report depicts the anomalous origin of the left vertebral artery from the arch of aorta.

## CASE REPORT

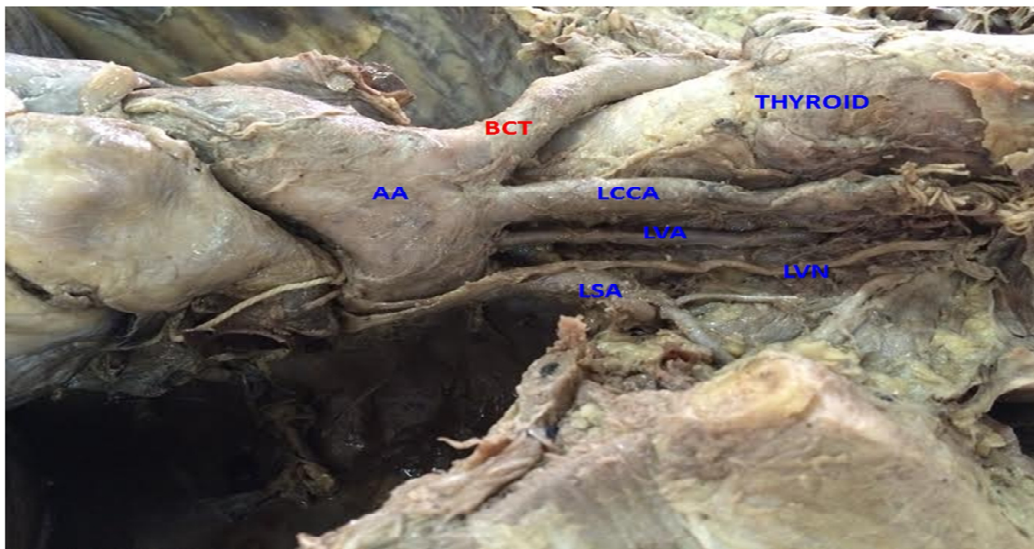
During routine dissection of a formalin fixed male cadaver aged 60- 65 years, for undergraduate students of Sri Manakula Vinayagar Medical College and Hospital, Pondicherry, the left vertebral artery was seen to be originating from the arch of aorta between the left common carotid and the left subclavian arteries, whereas, the vertebral artery on the right side had a normal origin from the first part of the right subclavian artery.

In the superior mediastinum, the left vertebral artery was seen ascending to reach the neck to

enter scaleno vertebral triangle. The artery then ran a vertical course to enter the foramen transversarium of the sixth cervical vertebra. It traversed the cervical foramina transversaria up to the foramen transversarium of the atlas. The artery had a non tortuous course and the pre vertebral segment measured about 51 mm.

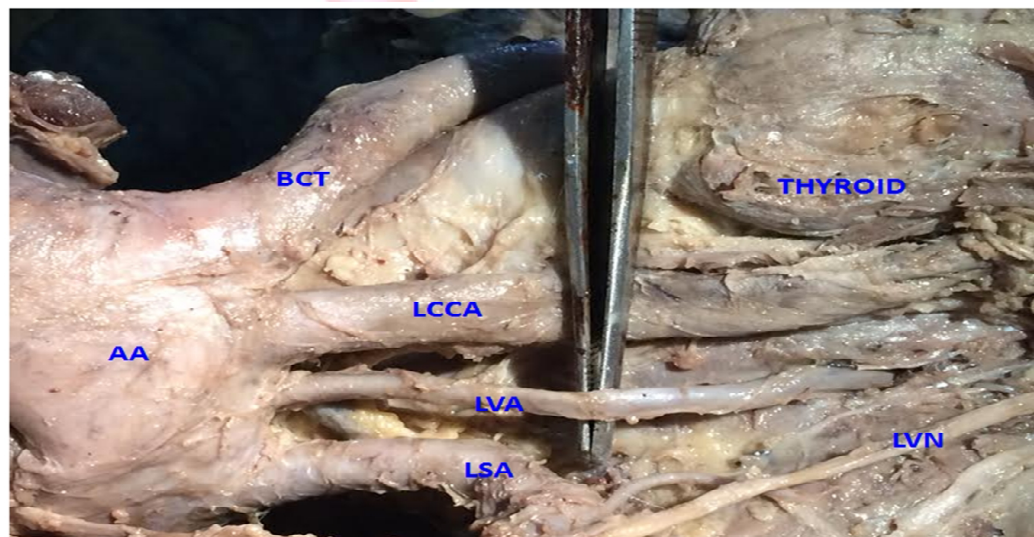
The vertebral artery on the right side originated from the first part of right subclavian artery medial to scalenus anterior muscle and followed a normal course of pre vertebral segment entering the foramen transversarium of the sixth cervical vertebra.

**Fig. 1:** Showing Anomalous Left vertebral artery.



AA-arch of aorta,BCT-Brachiocephalic trunk,LCCA-Left common carotid artery,LVA-Left vertebral artery, LSA-left subclavian artery,LVN-Left vagus nerve

**Fig. 2:** Showing Anomalous Left vertebral artery.



AA- Arch of Aorta, BCT- Brachiocephalic trunk, LCCA- Left common carotid artery, LVA- Left vertebral artery, LSA- Left subclavian artery, LVN- Left vagus nerve

## DISCUSSION

The vertebral artery is divided into four parts; the first part is derived from the proximal part of dorsal division of the seventh cervical intersegmental artery. The second part is derived from the longitudinal communications of the postcostal anastomoses between the first to sixth cervical intersegmental arteries. The third part develops from the spinal branch of the first cervical intersegmental artery and the fourth part develops from its pre neural division [1, 2].

Albayram et al. have stated that an aberrant left vertebral artery from arch of aorta is due to the persistence of eighth intersegmental artery [3].

Aortic arch anomalies are seen in chromosomal abnormalities such as 22q11 deletion [4]. In a study by Shin et al. it was noted that the left vertebral artery arose from the arch of aorta between the left common carotid and left subclavian arteries in 5.8% of cases [5]. In another study by Lemke et al. it was observed that 2.4- 5.8% cases had the above said variation[6].

Rekha et al. stated the occurrence of left vertebral artery branching from the arch of aorta in 4.5% of cases in a sample size of 110 formalin fixed cadavers [7].

The incidence of the left vertebral artery arising from the arch of aorta was found to be 3.33% in a study on 30 cadavers by Oza Sunil et al [8].

An unusual observation by Goray et al. depicted five direct branches arising from the arch of aorta which included both vertebral arteries [9]. 1.6% of 62 cadavers were found to have an anomalous left vertebral artery from the arch of aorta in a study by Nayak et al. [10]

Hassan et al. reported a case of a 40 year old female with symptoms of cervicomedullary stenosis due to compression of the cervicomedullary junction by an anomalous left vertebral artery from the arch of aorta [11].

An anomalous vertebral artery may or may not cause clinical symptoms. However it is necessary to be vigilant during procedures of the mediastinum and the neck to avoid misdiagnosis and iatrogenic complications. Since the vertebral artery forms an important part of the posterior cerebral circulation, aberrations in its origin,

course, diameter and length can affect the cerebral hemodynamics. This may contribute to the development of intracerebral malformations and dissection aneurysms [12]. As aforementioned, an anomalous vertebral artery with or without aneurysm can cause compression of various structures on its course.

Vertebral artery anomalies may also indicate the presence of many other congenital malformations of the cardiovascular system, eg. Absence of inferior thyroid artery, cardiac malformations, facial hemangiomas etc. [12]

Since the proximal part of direct branches of arch of aorta are more prone for atherosclerosis, any thromboembolic disorder in the vertebral artery can be hazardous as it contributes the blood supply to the brain.

Knowledge of such variations is essential for surgeons and diagnostic radiologists in various procedures which require the exposure of the arch of aorta and its branches, such as aortic arch reconstruction, graft technique for total arch replacement, aneurysm repair and endarterectomy. Other procedures which require a thorough knowledge of vertebral artery and its variations include angiography, lower cervical spine surgeries, transpedicular fixation, excision of cranio-cervical junction masses, endovascular procedures etc.

## CONCLUSION

It is obvious from the review of literature that left sided variations of the vertebral artery are much more common than those of the right side. Certain chromosomal aberrations may give rise to changes in the developmental pathway of the arteries leading to such anomalies. Variations such as the present case should be borne in mind during the above mentioned surgeries and procedures.

## Acknowledgement:

We would like to thank Master Pranavan S, for helping us with the photographs.

## Conflicts of Interests: None

## REFERENCES

- [1]. Hadimani GA, Desai SD, Bagoji IB, Sahana BN. Bilateral Variation in the Origin of Vertebral Artery.

- Journal of Pharmaceutical Sciences and Research 2013;5(10):196-198.
- [2]. Moore KL. The Developing Human. Clinically Oriented Embryology. 3rd Ed. WB Saunders, Philadelphia. 1982;291–318.
- [3]. Albayram S, Gailloud P, Wasserman BA. Bilateral Arch Origin of the Vertebral Arteries. American Journal of Neuro Radiology 2002;23:455–458.
- [4]. Momma K, Matsuoka R, Takao A. Aortic arch anomalies associated with chromosome 22q11 deletion (CATCH 22). Pediatr Cardiol 1999;20(2):97-102.
- [5]. Shin Y, Chung Y, Shin W, Im S, Hwang S, Kim B. A morphometric study on cadaveric aortic arch and its major branches in 25 Korean adults: the perspective of endovascular surgery. Journal of Korean Neuro Surgery Society 2008;44(2):78-83.
- [6]. Lemke AJ, Benndorf G, Liebig T, Felix R. Anomalous origin of the right vertebral artery: review of the literature and case report of right vertebral artery origin distal to the left subclavian artery. American Journal of Neuro Radiology 1999;20(7):1318-1321.
- [7]. Rekha P, Senthilkumar S. A study on branching pattern of human aortic arch and its variations in south indian population. Journal of Morphological Sciences 2013;30(1):11-15.
- [8]. Oza S, Gujar S, Modasia U, Prajapati S, Shekhavat J, Panda P et al. A study on the variant origins of vertebral artery. International Journal of Medical Science and Public Health 2014;3(3):349- 351.
- [9]. Goray VB, Joshi AR, Garg A, Merchant S, Yadav B, Maheshwari P. Aortic arch variation: a unique case with anomalous origin of both vertebral arteries as additional branches of the aortic arch distal to left subclavian artery. American Journal of Neuro Radiology 2005;26(1):93-95.
- [10]. Nayak SR, Pai MM, Prabhu LV, D'Costa S, Shetty P. Anatomical organization of aortic arch variations in the India: embryological basis and review. J Vasc Bras 2006; 5(2):95-100.
- [11]. Hassan HA, Ayad CE, Ibrahim TEM, Hassanand IA. Anomalous left vertebral artery. International Journal of Case Reports and Images 2014;5(3):247–249.
- [12]. Merwe B, Ackermann C, Scheepers S, Moosa S. Is anomalous origin of the left vertebral artery indeed a rare finding? S Afr J Rad 2012;16(4):144-146.

#### How to cite this article:

Deepa Somanath, Shivali Srivastava. ANOMALOUS LEFT VERTEBRAL ARTERY FROM ARCH OF AORTA-A THOUGHT FOR SURGEONS?. Int J Anat Res 2015;3(1):861-864. DOI: 10.16965/ijar.2015.102