

STUDY OF SACRAL HIATUS IN DRY HUMAN SACRA IN NEPAL, PARSA REGION

Malarvani T ^{*1}, Ganesh E ¹, Nirmala P ².

^{*1} Department of Anatomy, Tribhuvan University, National Medical College, Birgunj, Nepal.

² Department of Anatomy, Kathmandu University, Nobel Medical College & Teaching Hospital, Biratnagar, Nepal.

ABSTRACT

Introduction: The sacrum is a large triangular bone, formed by the fusion of five sacral vertebrae. The opening at the caudal end of sacral canal is known as sacral hiatus. It is formed due to the failure of fusion of laminae of the fifth (occasionally fourth) sacral vertebra. Sacrum is one of the bones which exhibit variations and the variation of sacral hiatus is of great clinical significance because it may also leads to mechanical low back pain. Previous works on the morphometrical study on the sacral hiatus is limited, especially in Nepal, Parsa population. The present study was undertaken to help in filling this gap at least to a certain extent and also made an attempt to find out the variations of sacrum.

Materials: One hundred dry human sacra were collected from the Department of Anatomy of National medical college & Teaching Hospital, Nepal.

Methods & Observations: The morphometrical studies were done, and the parameters (Shape, length, Transverse width & Antero-posterior width of sacral hiatus and level of apex & base of sacral hiatus) were measured with the help of divider, the observations were recorded, tabulated & analyzed.

Result: The study showed a significant co-relation between anatomical variations of sacral hiatus with the previous studies.

KEYWORDS: Sacral hiatus, Epidural anaesthesia, Caudal analgesia, Sacral canal.

Address for Correspondence: Malarvani T, Assistant Professor, Department of Anatomy, Tribhuvan University, National Medical College, Birgunj, Nepal. **E-Mail:** malarweddrop@gmail.com

Access this Article online

Quick Response code



DOI: 10.16965/ijar.2014.527

Web site: International Journal of Anatomy and Research
ISSN 2321-4287
www.ijmhr.org/ijar.htm

Received: 03 Nov 2014 Accepted: 02 Dec 2015
Peer Review: 03 Nov 2014 Published (O): 28 Feb 2015
Revised: 25 Nov 2015 Published (P): 31 Mar 2015

INTRODUCTION

Sacrum is a large triangular bone and is formed by the fusion of five sacral vertebrae in the adult. Sacrum forms the Postero-superior wall of the pelvic cavity, wedged between the two innominate bones [1]. The word sacrum means "Sacred" in Latin. In English it is the large heavy bone at the base of the spine. The name is derived from the Latin word, "sacred" a translation of the Greek word hieron (osteon),

meaning sacred or strong bone. The Romans called the bone, the "Os Sacrum" which literally meant the "Holy bone". In Greek "hieron" meant not only sacred but also a "Temple". It was in the sense that in its bony concavity laid the sacred organs of procreation, the ovaries and uterus. Due to its great in size, the sacrum is usually the last bone of a buried body to rot. There is some archaeological evidence to support the use of sacrum as a vessel to hold the sacrifice in ancient sacred rites. Egyptians

considered this bone sacred to "Osiris" the god of resurrection and of agriculture [2,3].

Its blunted, caudal apex articulates with the coccyx and its superior wide base with the fifth lumbar vertebra at the lumbosacral angle. The sacrum presents a base, an apex, pelvic, dorsal & lateral surfaces and a sacral canal.

The opening at the caudal end of sacral canal is known as sacral hiatus. It is formed due to the failure of fusion of laminae of the fifth (occasionally fourth) sacral vertebra. It is located inferior to the fourth (or third) fused sacral spines or lower end of median sacral crest [1].

The sacral hiatus is identified by palpation of the sacral cornua. Sacral cornua are felt at the upper end of the natal cleft 5 cm above the tip of the coccyx. Alternatively it may be identified by constructing an equilateral triangle based on a line joining the posterior superior iliac spines: the inferior apex of this triangle overlies the sacral hiatus.

The sacral hiatus contains fifth sacral nerve, coccygeal nerve roots, filum terminale externa and fibro fatty tissue. In recent state the sacral hiatus is covered by superficial posterior sacrococcygeal ligament which is attached to the margins of the sacral hiatus and the deep posterior sacrococcygeal ligament to the floor of the sacral hiatus [4].

The sacral hiatus shows variations during its development. Non -fusion of laminae of 4th or the upper vertebrae results in an elongated sacral hiatus. Non fusion of all the sacral vertebrae, results in sacral spina bifida. This leads to decreased surface area for the attachment of extensor muscle at the back; which may be a cause of backache [5].

Clinical importance of sacral hiatus:

Anesthetic agents are injected through the sacral hiatus in caudal epidural anaesthesia to act on the sacral and coccygeal nerves and these are often employed to relax the perineal musculature for painless child birth [6].

In orthopaedic practice – Transpedicular & lateral mass screw replacement.

It functions as a landmark when caudal analgesia is given in urology, proctology, general surgery and obstetrics & gynecology practice.

The anatomical variation of sacral hiatus as observed by various authors is one of the reasons for the decrease in the reliability and success of the above mentioned clinical applications.

It has now been noted that, the anatomical variations of sacral hiatus may also be one of the important cause for mechanical low back pain in the middle age.

The present study was undertaken to find out the anatomical variations of sacral hiatus in dry human sacra found in Nepal, Parsa region.

MATERIALS AND METHODS

The present study was conducted in the Department of Anatomy, National Medical College & Teaching Hospital, Birgunj, Parsa, Nepal. 100 dry human sacra were used for this study. The measurements were taken with the help of caliper, divider and steel measuring tape. Observations were substantiated with photographs. Damaged, mutilated & deformed sacra were excluded. Each sacrum was observed for different features of sacral hiatus with regards to:

1. Shape of the sacral hiatus
2. Apex of the sacral hiatus
3. Base of the sacral hiatus
4. Length of the sacral hiatus
5. Transverse width of the sacral hiatus
6. Antero - Posterior width of the sacral hiatus

OBSERVATIONS AND RESULTS

1. Shape of the sacral hiatus:

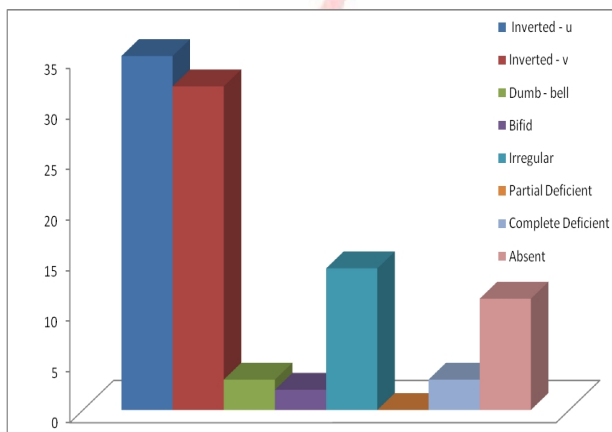
There were many variations in the shape of sacral hiatus. In 35% of sacra the shape was Inverted – U and in 32% of sacra Inverted – V. Both the above types were considered as normal. In 3% Dumb-bell shaped sacral hiatus was observed with a nodular bony growth projecting medially from both margins. In 2% of cases the shape of sacral hiatus was bifid. In 14% of cases the sacral hiatus was irregular in shape. The dorsal wall of sacral canal was entirely incomplete in 3% of cases. Absence of sacral hiatus was observed in 11% of cases.

Table 1: Shape of sacral hiatus.

FEATURES	Different shapes of Sacral Hiatus							
	Inverted U-Shaped	Inverted V-Shaped	Dumb - bell Shaped	Bifid Shaped	Irregular Shaped	Partial Deficient	Complete Deficient	Absent
Percentage of Specimens	35	32	3	2	14	0	3	11

Graph 1: Shape of sacral hiatus.

Percentage Of Specimens



Different shapes of Sacral Hiatus

Fig. 1: Specimen no. 2 shows Inverted - U shape Sacral Hiatus.

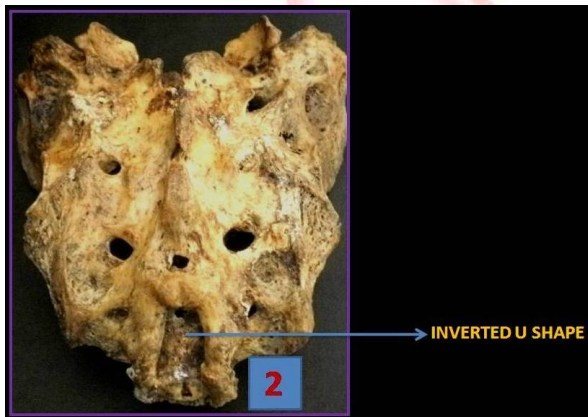


Fig. 2: Specimen no. 37 shows Inverted - V shape Sacral Hiatus.

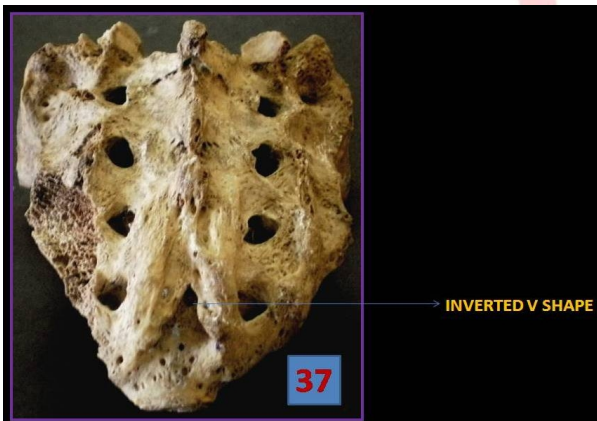


Fig. 3: Specimen no. 35 shows Dumb - Bell shape Sacral Hiatus.

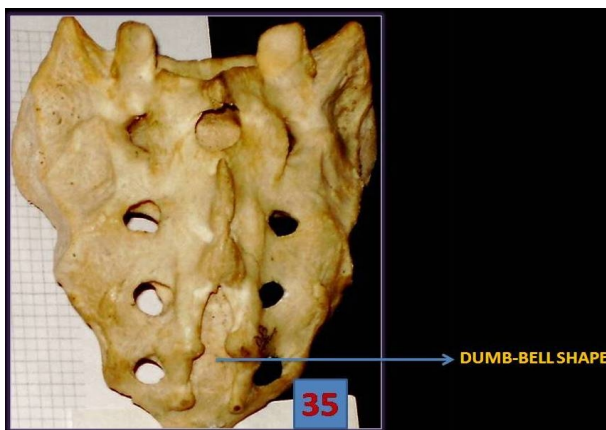


Fig. 4: Specimen no. 43 shows Bifid shape Sacral Hiatus.

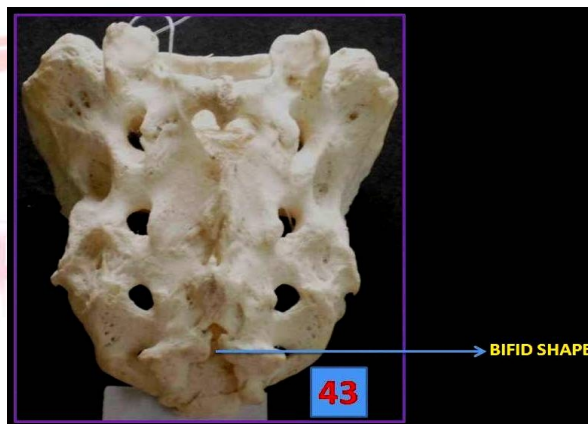


Fig. 5: Specimen no. 20 shows Irregular shape Sacral Hiatus.

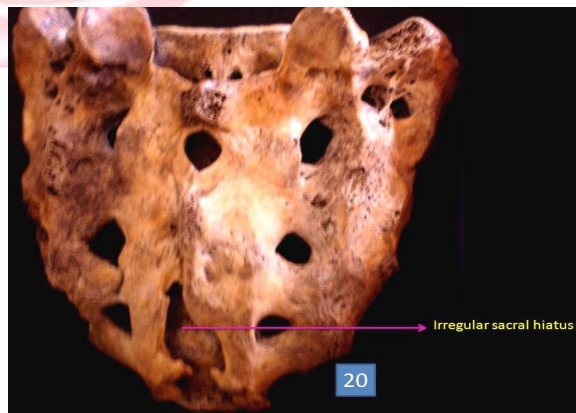


Fig. 6: Specimen no. 38 shows Partial Deficient Dorsal Sacral wall.

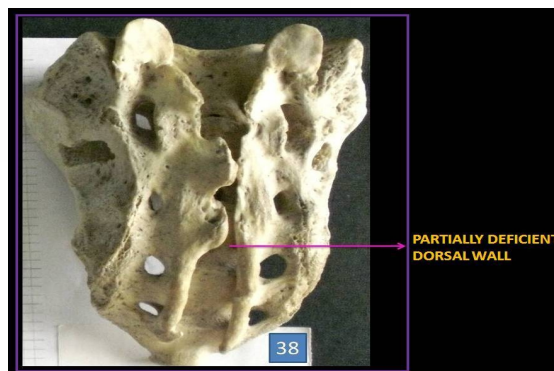


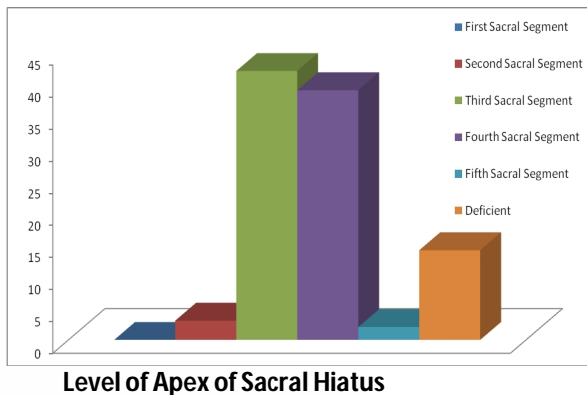
Fig. 7: Specimen no. 95 shows the Complete Deficient Dorsal Sacral wall.

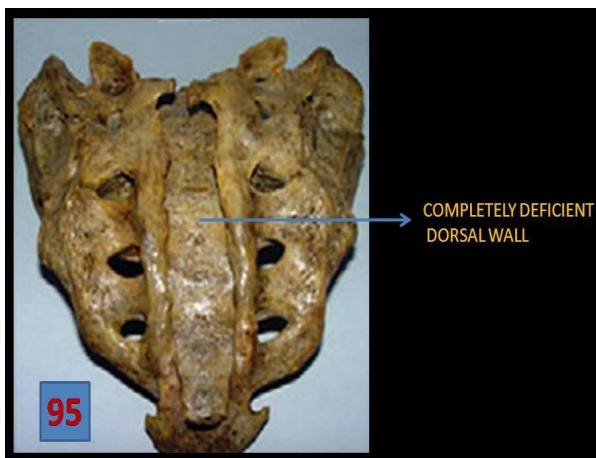
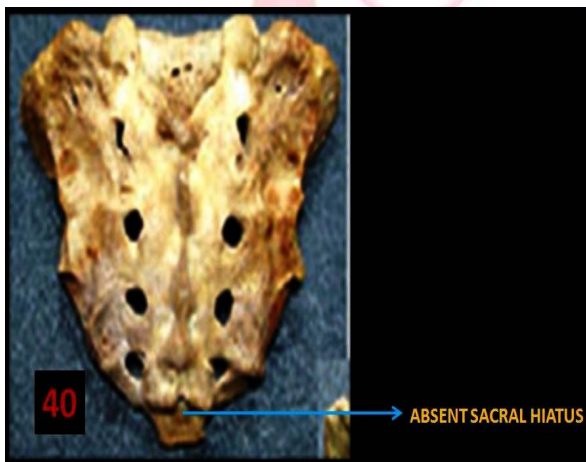
Fig. 8: Specimen no. 40 shows Absent Sacral Hiatus.



Graph: 2 Level of Apex of Sacral Hiatus Percentage Of Specimens



Level of Apex of Sacral Hiatus

Fig. 9: Specimen no. 24 shows Apex of Sacral Hiatus at S2 Level.




Fig. 10: Specimen no. 10 shows Apex of Sacral Hiatus at S3 Level.

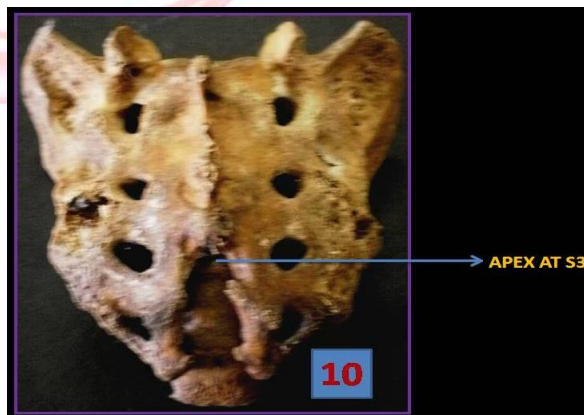
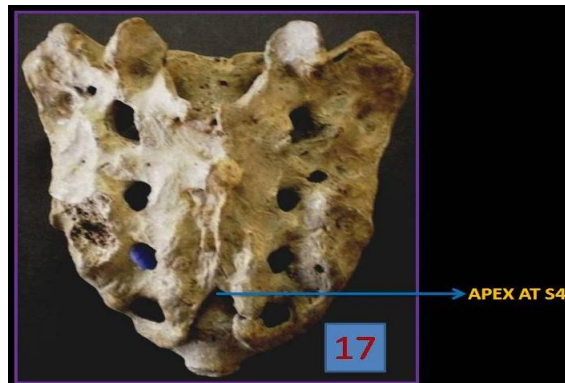


Fig. 11: Specimen no. 17 shows Apex of Sacral Hiatus at S4 Level.



2. Apex of the sacral hiatus:

The level of the apex was quite variable and extended between middle of second and middle of fifth sacral segments. In 42% of cases the apex was found at the third sacral segment. In 39% of cases the apex was found to be present at the fourth sacral segment while in 2% of cases it extended only up to the fifth sacral segment. In 3% of cases it extended up to second sacral segment. In 14% of sacra the apex of the sacral hiatus could not be ascertained due to complete sacral spina bifida in 3 specimens & absence of sacral hiatus in 11 specimens.

Table 2: Level of Apex of Sacral Hiatus.

FEATURES	Level of Apex of Sacral Hiatus					
	First Sacral Segment	Second Sacral	Third Sacral	Fourth Sacral	Fifth Sacral Segment	Deficient
Percentage of Specimens	0	3	42	39	2	14

Fig. 12: Specimen no. 36 shows Apex of Sacral Hiatus at S5 Level.

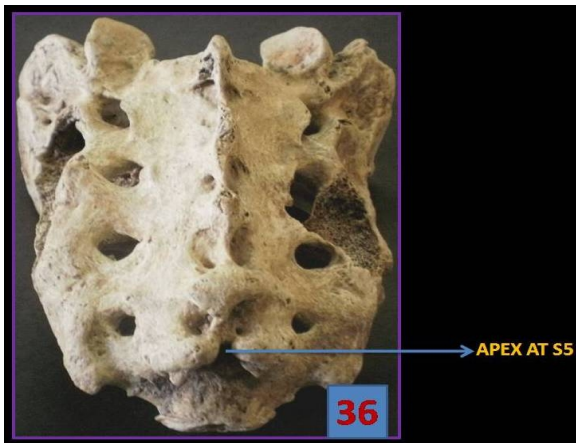
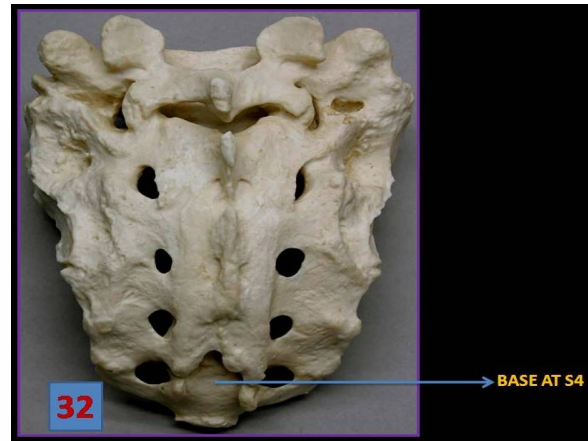

Fig. 13: Specimen no. 32 shows Base of Sacral Hiatus at S4 Level.



3. Base of the sacral hiatus:

The level of base varied in its presence between the middle of fourth sacral segment and middle of first piece of coccyx. In 14% of cases, the base of sacral hiatus could not be ascertained due to complete sacral spina bifida in 3 specimens and absence of sacral hiatus in 11 specimens. In 1% the base was found at the first coccygeal level. In 54% of cases it was present at the fifth sacral segment while in 31% of cases it was found at the fourth sacral segment.

Graph 3: Level of Base of Sacral Hiatus.

Percentage Of Specimens

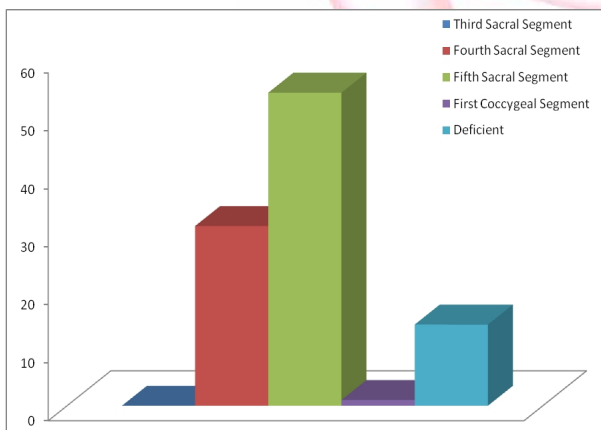


Table 3: Level of Base of Sacral Hiatus.

FEATURES	Level of Base of Sacral Hiatus				
	Third Sacral Segment	Fourth Sacral Segment	Fifth Sacral Segment	First Coccygeal Segment	Deficient
Percentage of Specimens	0	31	54	1	14

Fig. 14: Specimen no. 5 shows Base of Sacral Hiatus at S5 Level.

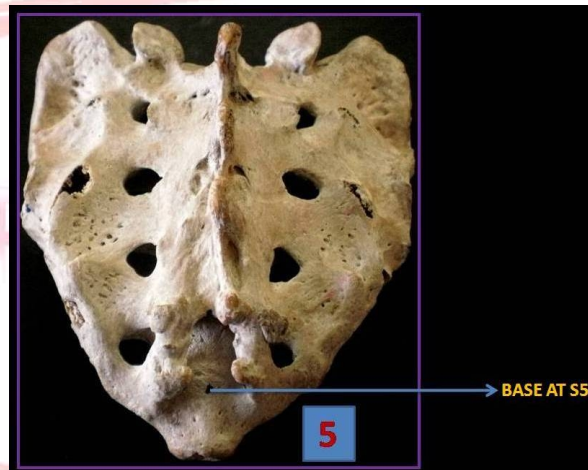
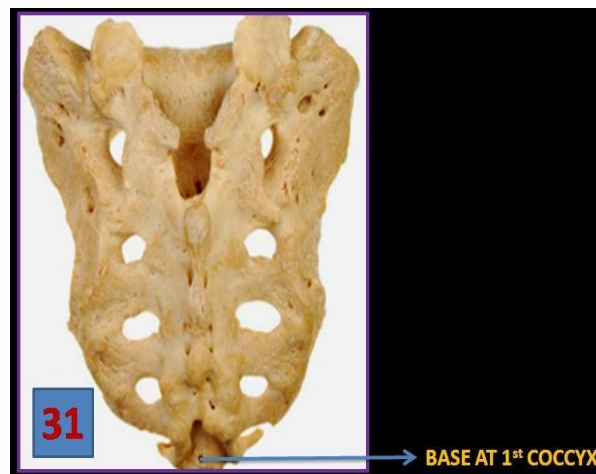

Fig. 15: Specimen no. 31 shows Base of Sacral Hiatus at 1st Coccyx Level.

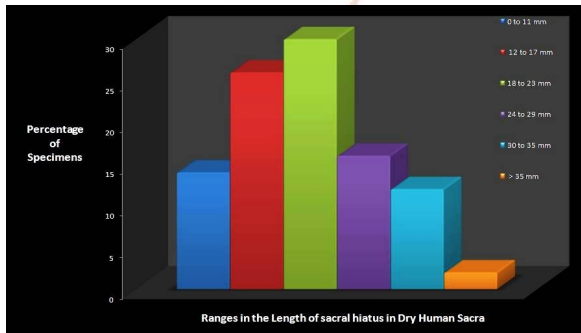


4. Length of the sacral hiatus:

The length of the sacral hiatus ranged between 12mm to 37mm. Deficient dorsal wall was observed in 3 specimens and absence of sacral hiatus in 11 specimens. These 14 specimens were not considered for the measurements of length.

Table 4: Ranges in the Length of sacral hiatus.

FEATURES	Ranges in the Length of sacral hiatus					
	0 to 11 mm	12 to 17 mm	18 to 23 mm	24 to 29 mm	30 to 35 mm	> 35 mm
Percentage of Specimens	14	26	30	16	12	2

Graph 4: Ranges in the Length of sacral hiatus.

5. Transverse width of sacral hiatus:

The transverse width of sacral hiatus ranged between 7mm to 27mm.

6. Antero posterior width of sacral hiatus:

Antero posterior width of sacral hiatus varied between the values 2mm to 9mm.

DISCUSSION

The detailed morphometric study of sacral hiatus is of great relevance, since this route is frequently utilized for caudal epidural anaesthesia. The variations of sacral hiatus may also lead to mechanical low back pain.

A. Shape of sacral hiatus:

In the present study the shapes of sacral hiatus were variable; the most common shape observed was Inverted-U in 35% of sacra and Inverted-V in 32% of sacra and Nagar SK [7]. Also noted similar variations most common being Inverted-U in 41.5% and Inverted-V in 27% of sacra but this was contradictory to the observations reported by Vishal kumar et al [8] in which Inverted-U was 23.6% and Inverted-V was 39.6% and Vinod kumar et al [9] in which Inverted-V was 46.53% and Inverted-U was 29.7%. But both the above types were considered as normal.

In 3% of sacra it was like a dumb-bell shape which is very low when compared to previous workers namely Nagar SK [7] in 36(13.3%) sacra and Vinod kumar et al⁹ in 15(7.43%) sacra. Bifid

sacral hiatus was seen in 2% sacra which was similar to that reported by Nagar SK [7] in 1.5% of sacra. There was complete agenesis of sacral hiatus in 3% of sacra which is nearly equal to that reported by previous workers namely Trotter et al[11] 1.8%, Vinod kumar et al [9] in 1.49% and Nagar SK. [9] in 1.5% of sacra but it was high in the report of Vishal kumar et al [8] as 7.2%. Irregular shape was observed in 14% of sacra which is almost equal to that observed by Nagar SK [7]. in 14.1% of sacra but very low when compared to the previous worker Vishal kumar et al [8] in 30% of sacra. In the present study absence of sacral hiatus due to bony over growth was observed in 11% of sacra which are high compared to the other authors like Nagar SK [7] in 0.7%, Vinod kumar et al [9] in 0.99% and Sekiguchi M et al¹⁰ in 3% of sacra only.

B. Apex of the sacral hiatus:

Susan standing et al states that the apex of sacral hiatus is present at the level of fourth sacral vertebra. In the present study the apex of sacral hiatus was seen at the level of fourth sacral vertebra in only 39% of sacra which is much lower when compared to the previous authors like Vinod kumar et al [9] in 76.23% of sacra, Vishal kumar et al⁸ in 72% of sacra, Sekiguchi M et al [10] in 65% of sacra and Nagar SK.⁷ in 55.9%. In the present study, the apex was seen most commonly at the level of third sacral vertebra in 42% of sacra. All previous studies including the present study noted that the location of apex can vary from upper part of second sacral vertebra to lower part of fifth sacral vertebra.

C. Base of the sacral hiatus:

Base of the sacral hiatus was seen at the level of fifth sacral vertebra in 54% of sacra in the present study which was lower when compared to the study conducted by Nagar SK [7] where he noted in 72.6% of sacra and much lower when compared to Vishal kumar et al [8] seen in 83.17% of sacra.

D. Length of the sacral hiatus:

Length of the sacral hiatus varied from 12mm to 37mm in the present study. The earlier workers namely Trotter et al [11] and Rajapur parachuram[12] reported that the length of sacral hiatus varied from 0mm to 60mm and

4mm to 51mm respectively which was high compared to the values of present study. But the present study value is somewhat similar to the study done by Vinod kumar et al [9] where he got the values between 3mm to 37mm.

E. Transverse width of sacral hiatus:

In the present study the transverse width of sacral hiatus varied between 7mm to 27mm which was similar to the study conducted by Trotter et al [11] who noted the transverse width to vary from 7mm to 26mm with arithmetic mean of 17mm. The study conducted by Nagar SK. [7] and Rajapur parashuram [12] showed the variations of transverse width between 3mm to 19mm and 1mm to 19mm respectively which is less compared to the present study. Lanier et al [13] reported arithmetic mean of transverse width at base to be 19.3mm. Vinod kumar et al [9] noted the transverse width to vary from 5mm to 20mm in male sacra and 8mm to 18mm in female sacra which is lower when compared to the present study.

F. Antero posterior width of sacral hiatus:

Antero-posterior width of sacral hiatus is important as it should be sufficiently large to admit a needle. Various diameters lead to subcutaneous deposition of anaesthetic drug. In the present study the antero-posterior depth ranged from 2mm to 9mm. The studies reported by the previous workers are almost similar to the present study only. Trotter et al¹¹ noted that antero-posterior depth varies between 0mm to 11mm and Vinod kumar et al⁹ reported that antero-posterior depth ranges from 0mm to 12mm. Nagar SK.⁷ noted that the range of antero-posterior depth is from 2mm to 14mm.

CONCLUSION

The opening at the caudal end of sacral canal is known as sacral hiatus. It is formed due to the failure of fusion of laminae of the fifth (occasionally fourth) sacral vertebra. It contains fifth sacral nerve, coccygeal nerve roots, filum terminale externa and fibro fatty tissue. The dural sac ends at the level of second sacral vertebra above the sacral hiatus.¹⁴ Sacrum is one of the bones which exhibit variations. Therefore the importance of the normal sacral hiatus and its variations is of great clinical significance.

Previous works on the morphometrical study on the sacral hiatus is limited, especially in Nepal, Parsa population. The present study was undertaken to help in filling this gap at least to a certain extent and also made an attempt to find out the variations of sacrum. One hundred (100) dry human sacra were collected from the Department of Anatomy of National medical college & Teaching Hospital from Birgunj, Parsa, Nepal. The morphometrical studies on sacral hiatus were done under the following parameters – Shape, length, Transverse width & Antero-posterior width of sacral hiatus and level of apex & base of sacral hiatus were measured with the help of divider and were recorded, tabulated & analysed. The study showed a significant co-relation between anatomical variations of sacral hiatus with the previous studies.

There are anatomical variations in the sacral hiatus and the understanding of these variations may improve the success of caudal epidural anaesthesia which was reported by various workers in the previous studies.

The variations of sacral hiatus due to developmental malformations (i.e. incomplete fusion of the laminae of the sacral vertebrae) may lead either to highly placed apex or sometimes even deficient dorsal wall (partial or complete). This leads to the decreased surface area for the attachment of extensor muscles of the back and so even a mild stress to these muscles will make it strain more and will result in painful conditions of the back.

ACKNOWLEDGEMENT

Authors are very much thankful to Mr. Ajit Kumar, Physiotherapist, Department of Physiotherapy, Nethaji Subash Chandra Bose Medical College & Hospital for his technical & financial support to complete this study.

Conflicts of Interests: None

REFERENCES

- [1]. Standring S. Gray's Anatomy, 39th Ed, Elsevier Churchill Livingstone, London, 2005; 731 & 749 – 754.
- [2]. Sugar O. How the sacrum got its name. *Jama and Archives* 1987; 257(15):1.

- [3]. The Sacrum – The Holy Bone, Oct 2003.
- [4]. Ernest J Frazer. Anatomy of the Human skeleton. J and A Churchill Ltd, London, 1914; 37 -42.
- [5]. Brailsford JF. Deformities of lumbosacral region of spine. British Journal of Surgery 1929; 16: 562 – 570.
- [6]. Edwards WB, Hingson RA. Continuous caudal anaesthesia in obstetrics. American Journal of Surgery 1942; 57: 459 – 464.
- [7]. Nagar SK. A study of sacral hiatus in dry human sacra. Journal of Anatomical Society of India 2004; 53(2): 18 – 21.
- [8]. Vishal kumar et al. Sacral hiatus in relation to low back pain in South Indian population: Anatomico – Radiological study. Bratisl Lek Listy 2009; 110(7): 436 – 441.
- [9]. Vinod kumar et al. Morphometrical study of sacral hiatus. Journal of Anatomical society of India 1992; 41(1): 7 – 13.
- [10]. Sekiguchi M, Yabuki S, Satoh K, Kikuchi S. An Anatomical study of the sacral hiatus: A basis for successful caudal epidural block. Clinical journal of pain 2004; 20(1): 51 -54.
- [11]. Trotter M. and Letterman GS. Variations of the female sacrum: Their significance in continuous caudal anaesthesia. Surg. Gynecol. Obstet 1944; 78(4): 419 -424.
- [12]. Rajapur parachuram. Morphometrical study of sacral hiatus using isolated dry human sacra: Dissertation 2008.
- [13]. Lanier VS, Mcknight HE, Trotter M. Caudal analgesia: An experimental and anatomical study. American journal of Obstetrics and Gynaecology 1944; 47(5): 633 – 641.
- [14]. Hollinshead WH. Anatomy for Surgeons. 2nd Ed, Harper and Row publishers, Philadelphia, 1969; 176 – 180.
- [15]. Chen PC, Tang STF, Hsu, et al. Ultrasound guidance in caudal epidural needle placement. Anaesthesiology 2004; 101: 181 – 184.
- [16]. Datta AK. Essentials of human osteology, 1st Ed, Current Books International, Calcutta, 1997: 53.
- [17]. David L Brown. Regional Anaesthesia and Analgesia, Saunders and Company, 1986; 346 -347.
- [18]. Esses SI, Botsford DJ, Huler RJ, et al: Surgical anatomy of the sacrum. A guide for rational screw fixation. Spine 1991; 16(suppl 6):283 – 288.
- [19]. Esses SE, Botsford DJ: Surgical Anatomy and Operative Approaches to the sacrum, in Frymoyer JW, Ducker TB, Hadler NM et al(eds): The Adult Spine: principles and practise, 2nd Ed. Philadelphia: Lippincott-Raven, 1997;2:2329 – 2341.
- [20]. Estin D, Cohen AR. Caudal agenesis and associated caudal spinal cord malformations. Neurosurg Clin N Am 1995; 6: 377 – 391.
- [21]. Letterman GS, Trotter M. Variations of the male sacrum: Their significance in caudal analgesia. Surg. Gynecol. Obstet 1944; 78(5):551 – 555.
- [22]. Marina Baptist et al. Sex differences in sacra in the Punjab region: E:/Biomedica vol.24, Jul. – Dec. 2008/ Bio – 23. Doc (WC) :152 – 157.
- [23]. Mishra et al. Identification of sex of sacrum of Agra region: J Anat. Soc. India 2003; 52(2):132 - 136.
- [24]. N.Senoglu, et al. Landmarks of the sacral hiatus for caudal epidural block: An Anatomical study. British Journal of Anaesthesia 2005;95(5): 692 – 695.
- [25]. Saberski L, Kitahata L. Direct visualization of lumbosacral epidural space through the sacral hiatus. Anaesth Analg 1995; 80: 839 – 840.
- [26]. Siddiqui A. Variations in sacral hiatus. Journal of Anatomical Society of India 2003; 52(1):113.
- [27]. Tapan kumar jana et al. Variations in sacral hiatus and significance of hiatal index in sexing of sacrum. Journal of Anatomical society of India 1986; 42
- [28]. Thompson JE. An Anatomical and Experimental study of sacral anaesthesia. Ann. Surg 1917; 66:718 – 727.
- [29]. Trotter M. Variations of the sacral canal: Their significance in the administration of caudal analgesia. Anaesth. Analg 1947; 26(5):192 – 202.
- [30]. Bernard Rosner. Fundamentals of Biostatistics, 5th Ed, Duxbury, 2000.
- [31]. Venkataswamy Reddy. Statistics fir mental health care research, NIMHANS publication, India, 2002.

How to cite this article:

Malarvani T, Ganesh E, Nirmala P. STUDY OF SACRAL HIATUS IN DRY HUMAN SACRA IN NEPAL, PARSIA REGION. *Int J Anat Res* 2015;3(1):848-855. DOI: 10.16965/ijar.2014.527