

## CASE REPORT

# ATYPIC DRAINAGE PATTERN OF POSTERIOR INTERCOSTAL VEINS INTO THE AZYGOS VENOUS SYSTEM

Rimpi Gupta <sup>\*1</sup>, Deepak Goyal <sup>2</sup>, APS Batra <sup>3</sup>, Shveta Swami <sup>4</sup>.

<sup>\*1</sup> Assistant professor, Dept of Anatomy, BPS GMC For Women, Khanpur Kalan, Sonipat, India.

<sup>2</sup> Medical officer HCMS-1, PHC Dubheta, Dist Sonapat, Haryana, India.

<sup>3</sup> Professor & Head, Dept of Anatomy, BPS GMC For Women, Khanpur Kalan, Sonipat, India.

<sup>4</sup> Associate professor, Dept of Anatomy, BPS GMC For Women, Khanpur Kalan, Sonipat, India.

## ABSTRACT

The azygos venous system vary greatly in their mode of origin, course, tributaries, anastomoses and termination which result predominantly due to its complex embryological development. Azygos venous system develops as right and left azygos venous lines. Right azygos venous line develops into vertical part of azygos vein whereas the left one develops into accessory hemiazygos and inferior hemiazygos veins. These are connected by subcentral/ transvertebral veins. In the present case, we found an atypic drainage pattern of posterior intercostal veins into azygos venous system, left being more variable. Right superior intercostal vein formed by 2<sup>nd</sup> and 3<sup>rd</sup> posterior intercostal veins whereas left superior intercostal vein was found to be absent. 2<sup>nd</sup>, 3<sup>rd</sup>, 4<sup>th</sup> & 5<sup>th</sup> left posterior intercostal veins thus drained into accessory hemiazygos vein. Sixth and seventh left PICVs formed a common trunk with accessory hemiazygos vein and drained into the azygos vein at T6 level. Eighth one united with the hemiazygos vein and formed a common trunk which drained into azygos vein at T8 level. Such variations of the azygos venous system are important for a clinician during mediastinal surgeries to prevent inadvertent hemorrhagic complications.

**KEY WORDS:** Azygos vein, accessory hemiazygos vein, hemiazygos vein, superior intercostal vein.

**Address for Correspondence:** Dr. Rimpi Gupta, MBBS, MS Anatomy, Assistant professor, Dept. of Anatomy, BPS GMC For Women, Khanpur Kalan, Sonipat, India. **E-Mail:** dr.rimpigupta15@gmail.com

## Access this Article online

### Quick Response code



DOI: 10.16965/ijar.2014.537

**Web site:** International Journal of Anatomy and Research  
ISSN 2321-4287  
[www.ijmhr.org/ijar.htm](http://www.ijmhr.org/ijar.htm)

Received: 13 Nov 2014

Peer Review: 13 Nov 2014 Published (O): 31 Dec 2014

Accepted: 02 Dec 2014 Published (P): 31 Dec 2014

## INTRODUCTION

Variations related to azygos venous system are not rare [1]. They vary much in their mode of origin, course, tributaries, anastomosis and termination. Azygos veins are important caval-caval and portocaval junctions, thus forming collateral circulation in caval vein occlusion and in portal hypertension [2]. Several variations are reported in the literature viz agenesis of accessory hemiazygos vein with a predominant left superior intercostal vein draining the upper intercostals spaces, agenesis of hemiazygos

vein [3], variant accessory hemiazygos vein with persistent cranial segment of posterior cardinal vein, incomplete accessory hemiazygos vein with posterior intercostals veins draining bilaterally into the azygos vein [5], pre-aortic interazygos vein [6] etc. Deviation in the pattern of azygos venous system result predominantly due to its complex embryological development [1,7,8,9]. It is important to report and document the different variations of the azygos venous system because especially in CT and MRI scans some variations of the azygos

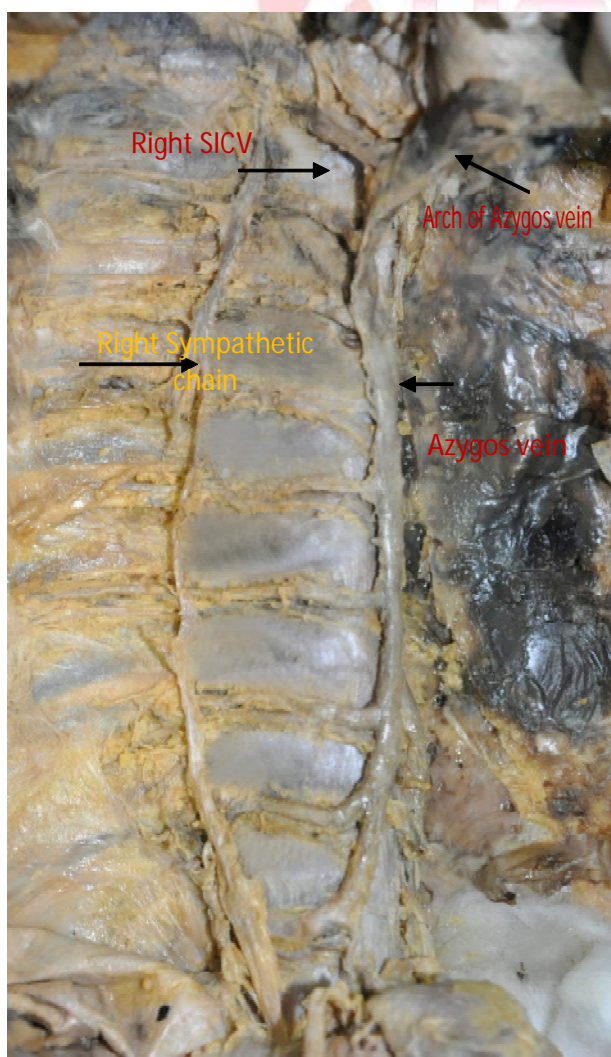
venous system can easily be confused with pathological conditions such as aneurysms, tumors and enlarged lymph nodes [3]. Finally, it is of utmost importance for surgeons to keep in mind the possibility of a variation of the azygos venous system during the mediastinal operations.

### CASE REPORT

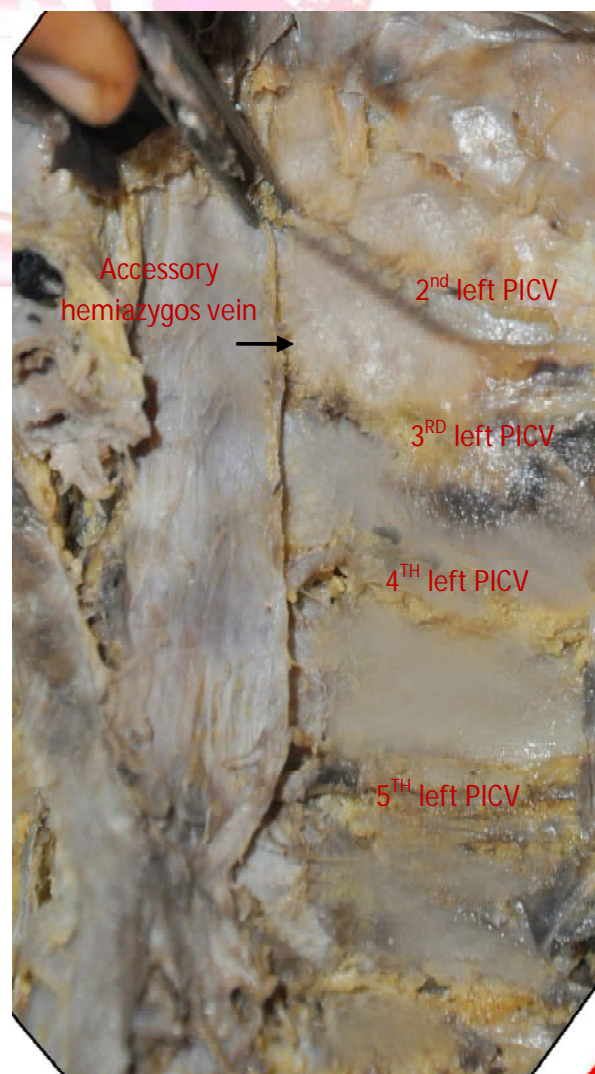
During the routine undergraduate dissection of the posterior mediastinum of 55 year old male cadaver, we encountered an unusual variation in the drainage pattern of posterior intercostal veins (PICVs), left being more variable in their mode of drainage. In the present case, the right second and third PICVs formed the superior ICV and drained into the arch of the azygos vein whereas the fourth PICV drained directly into the azygos vein. Then five to eleven right PICVs followed the normal pattern of drainage into the

azygos vein. Left PICVs showed much variation in their mode of drainage. Left superior ICV was found to be absent. The second and third PICVs which normally joins to form left superior ICV drained independently into the accessory hemiazygos vein. Fourth and fifth left PICVs drained normally into the accessory hemiazygos vein. Then the sixth and seventh left PICVs formed a common trunk which joined the accessory hemiazygos vein and this common channel drained into the azygos vein at T6 level. Eighth left PICV instead of draining into accessory hemiazygos vein united with the hemiazygos vein and formed a common trunk which then drained into azygos vein at T8 level. Ninth, tenth and eleventh left PICVs followed normal pattern of drainage into the hemiazygos vein. The first PICVs of both sides drained normally into the brachiocephalic veins of either side.

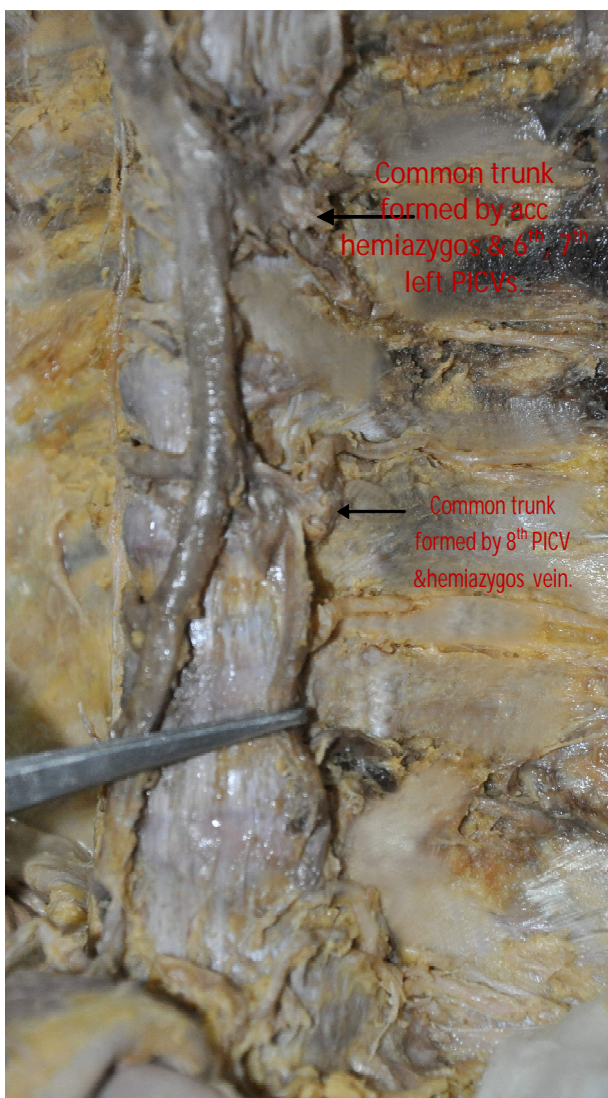
**Fig. 1:** Right azygos venous system in present case.



**Fig 2:** Accessory hemiazygos vein in the present case.



**Fig. 3:** Drainage pattern of 6<sup>th</sup> to 11<sup>th</sup> left posterior intercostals veins (PICVS).



## DISCUSSION

The azygos venous system develops from a pair of longitudinal venous lines, called the right and left azygos venous line (medial sympathetic vein line), dorsolateral to the aorta. On each side, the azygos venous line lies parallel to another two parallel primitive venous lines called the right and left subcardinal and post cardinal veins. The right azygos venous line develops into the vertical part of the azygos vein. The arch of the azygos is contributed partially by the persistent cephalic part of the right posterior cardinal vein. The caudal end of each azygos venous line joins with the corresponding sub-cardinal vein close to the level of the inter-subcardinal anastomosis. Thus the azygos vein begins as the ascending lumbar vein on both sides. The fate of the left azygos venous line is different. Due to the development of an oblique

communication between the right and the left anterior cardiac veins, the distal part of the left anterior cardinal vein, the cranial part of the left posterior cardinal vein and the left common cardinal vein regress greatly. The first of the two structures mentioned above persist in the adult life as left superior intercostal vein. The left azygos venous line gives rise to a set of longitudinally arranged veins. The upper set, named the superior or accessory hemiazygos veins, drain the fourth to the sixth intercostals spaces posteriorly. The lower part of the azygos venous line gives rise to the inferior hemiazygos vein that arises as the left ascending lumbar vein, similar to the azygos vein on the right, draining the seventh and lower intercostals spaces. The accessory hemiazygos and the hemiazygos veins usually are independent systems and connect to the azygos vein with two transversely oriented veins at the levels of the seventh and eighth thoracic vertebrae. These transverse channels embryologically are derived from such connections between the right and the left posterior cardinal veins [10].

In the present case, the distal part of the left anterior cardinal vein, the cranial part of the left posterior cardinal vein which normally persist as left superior intercostal vein did not persist leading to the non-formation of left superior intercostal vein. Hence, the second and third left PICVs drained into accessory hemiazygos vein.

## CONCLUSION

Though the anatomical variations in the azygos system are physiologically normal, it is important to be aware of the unique yet normal variations of the azygos venous system during mediastinal surgeries to prevent inadvertent hemorrhagic complications [11]. Confusion can be avoided in diagnosing these structures after detection in scans and MRI [12,13].

**Conflicts of Interests:** None

## REFERENCES

- [1]. Mezzoqiorno A, Passiatore C. An atypic pattern of azygos venous system in man. *Anat Anz.* 1988; 165: 277–281.
- [2]. Arslan G, Cubuk M, Ozkaynak C, Sindel T, Luleci E. Absence of the azygos vein. *Clin Imaging.* 2000; 24: 157–158.

- [3]. Ozbek A, Dalcik C, Colak T, Dalcik H. Multiple variations of the azygos venous system. *Surg Radiol Anat.* 1999; 21: 83–85.
- [4]. Mahato NK. Anomalous accessory hemi-azygos system with persistent cranial segment of posterior cardinal vein - A case report. *Braz J Morphol Sci.* 2009; 26: 177–179.
- [5]. Kocabiyik N, Kutoglu T, Albay S, Yalcin B, Ozan H. Azygos vein system abnormality: case report. *Gulhane Med J.* 2006; 48: 180–182.
- [6]. Pyrzowski J, Spodnik JH, Lewicka A, Poplawska A, Wojcik S. A case of Multiple abnormalities of the azygos venous system: a pre-aortic interazygos vein. *Folia Morphol(Warsz)* 2007; 66(4):353-5.
- [7]. Pillet, J., Mercier, P., Chronier, P. et al. Isolated azygos continuation of the inferior vena cava. Absence of the retrohepatic segment of the inferior vena cava. *Bulletin de l' Association des Anatomistes.* 1986, vol. 70, no. 210, p. 69-74.
- [8]. Coscina, WF., Arger, PH., Mintz, MC. et al. Concurrent duplication and azygos continuation of the inferior vena cava. *Journal of Computer Assisted Tomography.* 1986, vol. 10, no. 5, p.287-290.
- [9]. Bergman, RA., Afifi, AK. and Miyauchi, R. *Illustrated Encyclopedia of Human Anatomic Variation: Opus II: Cardiovascular System: Veins: Thorax.* 12 ed. New York: McGraw Hill, 1966.
- [10]. Standring S. *Gray's anatomy: the anatomical basis of clinical practice.* 39 ed. Philadelphia: Churchill Livingstone, 2005. p. 1025-1050.
- [11]. Brenner BJ., Clement DR., Frederick PL. et al. Major venous anomalies complicating abdominal aortic surgery. *Archives of Surgery.* 1974, vol. 108, p. 159-165.
- [12]. Smathers RL., Lee JKT. and Heiken JP. Anomalous preaortic interazygos vein. *Journal of Computer Assisted Tomography.* 1983, vol. 7, p. 732-733.
- [13]. Takasugi JE, Godwin JD. CT appearance of the retroaortic anastomoses of the azygos system. *AJR Am J Roentgenol.* 1990; 154: 41–44.

**How to cite this article:**

Rimpi Gupta, Deepak Goyal, APS Batra, Shveta Swami. ATYPIC DRAINAGE PATTERN OF POSTERIOR INTERCOSTAL VEINS INTO THE AZYGOS VENOUS SYSTEM. *Int J Anat Res* 2014;2(4):740-743. **DOI:** 10.16965/ijar.2014.537