

## EVALUATION OF HISTOLOGICAL CHANGES IN CHRONIC CHOLECYSTITIS AND CHOLELITHIASIS OF HUMAN GALLBLADDER

Hemlata Sharma <sup>\*1</sup>, Manoj Kumar Sharma <sup>2</sup>, Ghanshyam Gupta <sup>3</sup>.

<sup>\*1</sup>Lecturer, Department of Anatomy, Jhalawar Medical College, Jhalawar (Rajasthan), India.

<sup>2</sup> Associate Professor, Department of Anatomy, Jhalawar Medical College, Jhalawar (Rajasthan), India.

<sup>3</sup> Professor & Head, Department Of Anatomy, R.N.T Medical College, Udaipur (Rajasthan), India.

### ABSTRACT

**Introduction:** It is appear to be increasing in incidence over part couple of decades in India and western world due to increased intake of fatty and high calorie diet and increased consumption of alcohol. Cholecystitis and cholelithiasis are very common particularly in fatty, fertile and female of forty to fifty. Various sign and symptoms like severe pain in Murphy's point in right upper quadrant of abdomen , bilious vomiting , mild to moderate increase in temperature , obstructive jaundice , loss of appetite are present in these disease .

**Aim of study:** The purpose of the present study is to compare the histological changes in the wall of human gall bladder in Cholecystitis and cholelithiasis.

**Material and methods:** Gallbladder of 100 patients of both sexes, aged between 12 years to 80 years was taken for present research work who underwent cholecystectomy for cholelithiasis with cholecystitis. The gall bladder biopsy was processed for histopathological examination. Hemotoxyllin and eosin staining was done for microscopic observations.

**Results:** The observations showed focal and diffused ulceration of mucosa and inflammatory cells infiltrate in sub epithelial layers. Fibrosis and thickening of the perimuscular layer with muscle hypertrophy were observed in maximum cases. The congestion of blood vessels and hemorrhage were also noted.

**Discussion:** The conclusion of study is to demonstrate predominate alteration in specific layer of diseased gallbladder and to compare it with each other and normal one.

Once histopathological changes occur they alter the normal tissue pattern and can induce the carcinogenic progression and metastasis. The advantage of this work is early differential diagnosis between the two and two give effective treatment as early as possible.

**KEY WORDS:** Gallbladder, Gallstone disease, cholecystitis, cholelithiasis, Inflammation, Epithelial heperplasia, Metaplasia, Rokitansky aschoff sinus.

**Address for Correspondence:** Mrs. Hemlata Sharma, W/O Dr. Manoj Kumar Sharma, III/5, Staff Quarters, Doctors Colony, Behind Ima Hall, Medical College Campus, Jhalawar Medical College, Jhalawar-326001(Rajasthan), India. **E-Mail:** mannusneha06@yahoo.co.in

### Access this Article online

#### Quick Response code



DOI: 10.16965/ijar.2014.540

**Web site:** International Journal of Anatomy and Research  
ISSN 2321-4287  
[www.ijmhr.org/ijar.htm](http://www.ijmhr.org/ijar.htm)

Received: 19 Nov 2014

Peer Review: 19 Nov 2014 Published (O):31 Dec 2014

Accepted: 02 Dec 2014 Published (P):31 Dec 2014

### INTRODUCTION

Gall stone disease is a common health problem worldwide including India. It is commonly believed that bile stasis is the prime factor for

formation of gall stone. The function of gall stone not only to store bile but also to concentrate it during the inter digestive phase by means of salt dependent water reabsorption.

Epithelium of gallbladder and biliary tract is exposed to high concentration of potentially harmful exogenous and endogenous compound excreted into primary bile [1].

Gallbladder disease like cholecystitis and cholelithiasis are very common in fatty, fertile and female of forty to fifty but equally effects male and children's [2]. Cholecystitis and cholelithiasis appear to be increasing in incidence over past couple of decades in India and western world due to increased intake of fatty and high calorie diet and increased consumption of alcohols [3]. The disease specifically represents with various sign and symptoms like pain in Murphy's point , bilious vomiting, mild to moderate increase in temperature .These disease produce mild to moderate yellow discoloration of cornea, nail beds in latent stage because of obstructive jaundice. There is also severe loss of appetite and weight [4]. All columnar epithelium cells are lined by a blanket of mucosa, a negative physiological gel like secretion which separates the host mucosal cells from the external milieu [5]. The gallbladder mucus play a regulatory role in cholelithiasis as it promotes the nucleation of stones [6]. Mucus, calcium and lipids act in concert to form the gallstones. Gallbladder mucin is one of the key factors in gallstone formation. However, there is little information about the diversity of mucin secretion according to the stone composition [7].

A major causative agent for stasis of bile is gallbladder dyskinesia which in turn may be a consequence of gallbladder wall pathology [8]. However it was observed that gallbladder tension increased, rather than decreased during the early stage of gallstones formation [9].

Cholelithiasis produces diverse histopathological changes in gallbladder mucosa namely acute inflammation, glandular hyperplasia, granulomatous inflammation, cholesterosis, dysplasia and carcinoma [10].

**AIM OF STUDY:** The purpose of the present study is to compare the histological changes in the wall of human gall bladder in Cholecystitis and cholelithiasis.

## MATERIALS AND METHODS

Gallbladder of 100 patients aged between 12years to 80 years were obtained from Department of General Surgery, R.N.T Medical College and M.B. Govt. hospital , Udaipur , Rajasthan who underwent cholecystectomy for gallstone disease with chronic cholecystitis. To continue present research work, the permission was taken from Institutional Ethical Committee and principal, R.N.T Medical College, Udaipur. Each gallbladder was sectioned serially from the neck to the fundus. The section was obtained and carefully washed with 0.15 N saline, then fix it into 10% formalin then processed for light microscopy. The sections cut into 4mm thickness and stained in H & E stain for studying the general histology. Different histological finding were noted in various layers of cholelithiasis and cholecystitis gallbladder which are compared with each other. The observations were noted in predesigned Performa and analyzed.

## OBSERVATIONS AND RESULTS

### HISTOPATHOLOGICAL CHANGES:

The epithelium showed focal and diffused ulceration (figure -4 & Figure -2), hyperplasia (Figure -5), pyloric & intestinal metaplasia (Figure -10) and atrophy also.

The honey comb shaped epithelial distortion noted (Figure -3).

The sub epithelium hemorrhages and congestion noted (Figure -9).

Severe to Mild lymphocytic infiltration were observed in successive layers (Figure -7).

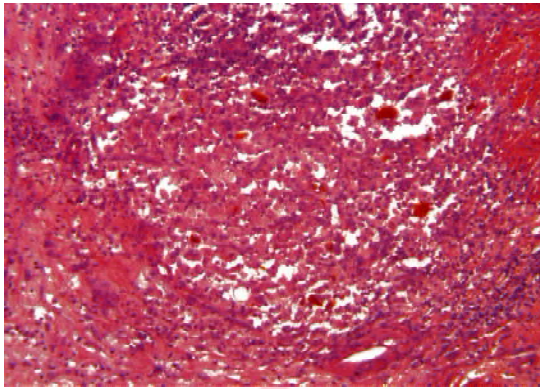
The muscle hypertrophy and fibrosis in perimuscular layer were seen (Figure -6).

Rokitansky aschoff sinus was found which were seen to be invaginated from mucosal to perimuscular layer (Figure -8).

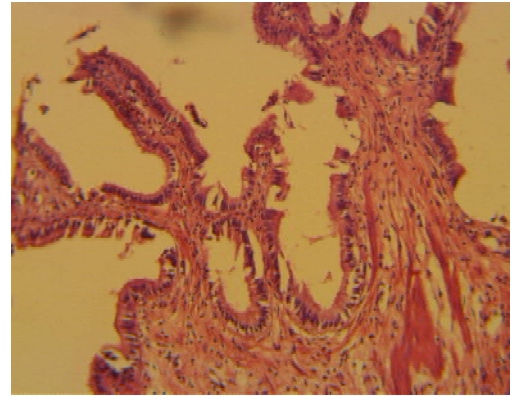
The serosa showed minimum infiltration of lymphocytes and macrophages with sub serosal hemorrhages (Figure -1).

Few slides showed presence of some neutrophils along with chronic cells infiltrate in sub epithelial layer of the gallbladder wall which represents chronic active cholecystitis (Figure -1).

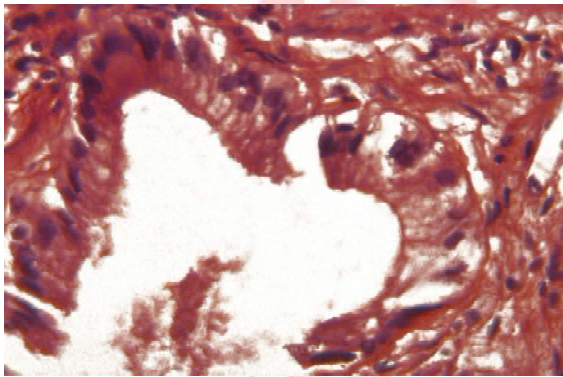
**Fig 1:** Microphotograph of Gallbladder Showing Chronic Active Cholecystitis. (10 X)



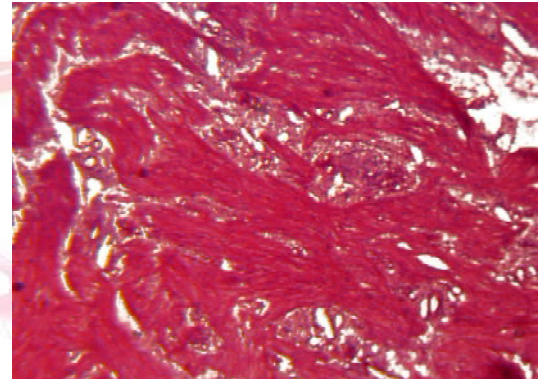
**Fig.5:** Microphotograph Of Gallbladder Showing Mucosal Ulceration. (10X)



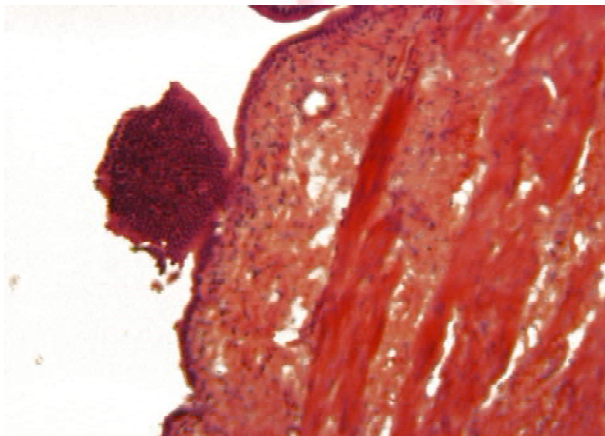
**Fig. 2:** Microphotograph Of Gallbladder Showing Disrupted Epithelium And Vacuolated Cytoplasm.(40x)



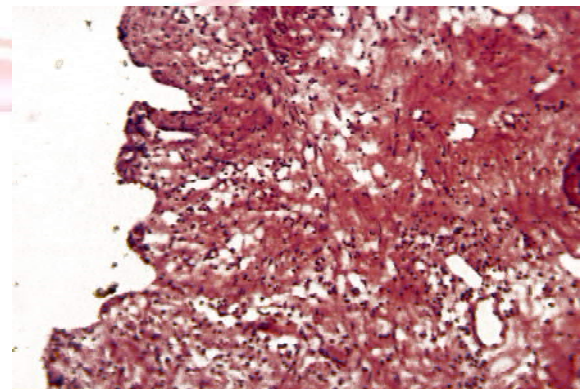
**Fig. 6:** Microphotograph Of Gallbladder Showing Muscle Hypertrophy. (10X)



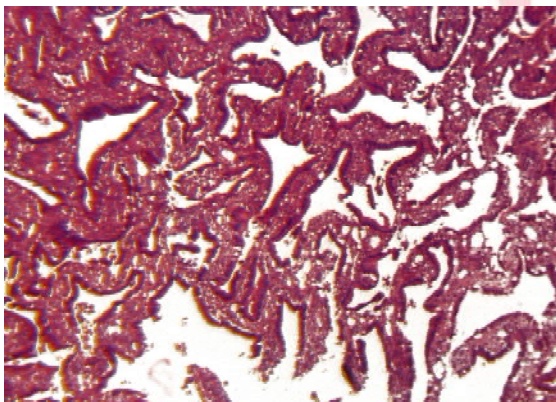
**Fig. 3:** Microphotograph Of Gallbladder Showing Honeycomb Shaped Distortion Of Epithelium. (10x)



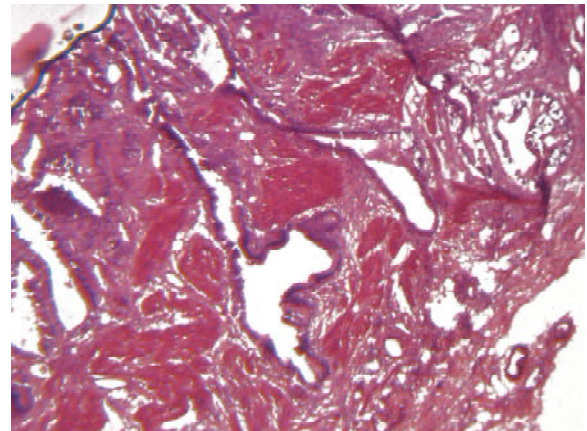
**Fig. 7:** Microphotograph Of Gallbladder Showing Atrophic Mucosa And Chronic Inflammatory Infiltrate In Successive Layers Of Wall. (10X)



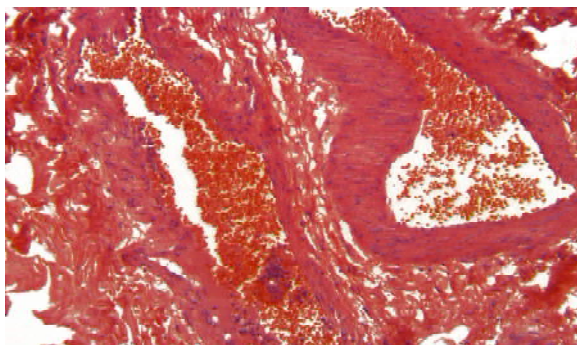
**Fig. 4:** Microphotograph Of Gallbladder Showing Chronic Cholecystitis With Mucosal Hyperplasia.(10x)



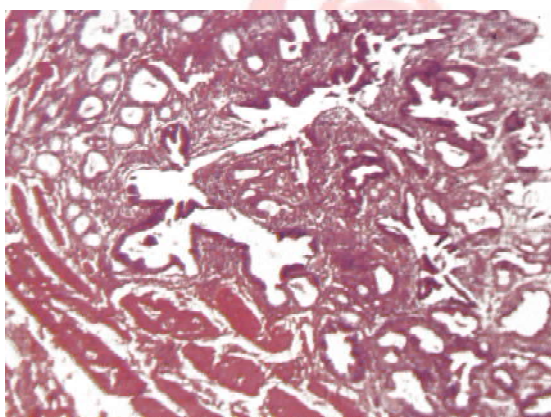
**Fig. 8:** Microphotograph Of Gallbladder Showing Rokitansky Aschoff Sinus. (10X)



**Fig. 9:** Microphotograph Of Gallbladder Showing Marked Haemorrhage And Congestion Of Blood Vessel. (10x).



**Fig. 10:** Microphotograph Of Gallbladder Showing Pyloric Metaplasia. (10x)



## DISCUSSION

In the present study, light microscopy examination of sections of the cholecystitic gallbladder showed disrupted epithelium with discontinues and irregular surface and vacuolated cytoplasm (figure-2). The gallbladder epithelium and smooth muscle layer were exposed to concentrated biliary solutes, including cholesterol and potentially toxic hydrophobic bile salts which are able to influence muscle contraction. The surface irregularity was due to the interruption of the brush border which showed a strong PAS positive reaction with abundance of mucus cells in its epithelium

These findings are in accordance with Schwartz SI et al (1958) [11] who studied primary sclerosing cholangitis and found coexistence of inflammatory lesions in the gall bladder, abundance of lymphocytes and plasma cells in the sub mucosa. This is usually associated with cholecystitis in which abundance of lymphoid follicles & moderate to severe chronic inflammatory cells were found. Tami yama H et al (1987) [12] studied cholelithiasis & found

dysplasia carcinoma sequence when observed histologically. They also observed that chronic trauma and inflammation can induce epithelial dysplasia, carcinoma in situ and invasive cancer. Jaffery KB et al (1991) [13] did histological and immune histochemical study of the gall bladder lesion and found abundance of lymphoid follicles & plasma cells within sub mucosa and moderate to severe chronic inflammations.

Badke A et al (1993) [14] observed histological changes in cholelithiasis gall bladder & found inflammatory changes in some and fibrotic changes in others.

Csendes A et al (1998) [15] studied histological findings of gall bladder mucosa in 95 control subject and with asymptomatic gallstone. Their findings suggested that chronic inflammatory changes can occur in the gall bladder mucosa prior to appearance of macroscopic stones.

## CONCLUSION

The present study is an attempt to demonstrate the histological alterations in cholecystitis and cholelithiasis gall bladder by histological slides analysis and to compare it with normal one. Once histopathological changes occur they alter the normal tissue pattern and can induce the carcinogenic progression and metastasis. The advantage of this work is early differential diagnosis between the two and two give effective treatment as early as possible. The observations from the study indicate a relationship between pathologic changes of gall bladder epithelium and gallstone formation. Overall the pathologic changes of the gall bladder epithelium may play an important role in the process of gallstone formation.

## ACKNOWLEDGEMENT

Thankful to the supervisor Dr. Ghanshyam Gupta, professor & Head, Department of Anatomy, R.N.T Medical College, Udaipur, India.

**Conflicts of Interests: None**

## REFERENCES

- [1]. Mohamed Zaki, Abdullah Al-Rafeidi. Histological changes in the human gallbladder epithelium associated with gallstones. *Omen Medical Journal* 2009;24(4):8-13.

- [2]. H.Mohan. Extra biliary apparatus-gall bladder (text book of pathology. chapter 19, 5th edition, 658-664 , 2005 .
- [3]. M C Carey. Pathogenesis of gallstones. Am J. Surg, 1993;165:410.
- [4]. Pani J.P, Pandey M S, Pani D S, Maderakar M N and Katti H K. Estimation of predominate histologic alterations in cholecystitis and cholithiasis of human gallbladder an analytical and statistical study through the approach of routine histochemistry. IOSR Journal of Dental and Medical Sciences, 2013;6(6):35-43.
- [5]. Kuver R, Klinkspoor JH, Osborne WR, Lee SP. Mucous granule exocytosis and CFTR expression in gallbladder epithelium. Glycobiology, 2000;10:149-157.
- [6]. Afdhal NH. Cholesterol crystal nucleation: a decade long search for the missing link in gallbladder pathogenesis. Hepatology, 1990;11:669-702.
- [7]. Kim HJ, Kim JS, Kim KO, park KH, Kim JY et al. expression of MUC3 ,MUC5A, MUC6 and epidermal growth factor receptor in gallbladder epithelium according to gallstone composition. Korean Journal Gastroenterol, 2003;42: 330-336.
- [8]. Velanovich VF. Biliary dyskinesia and biliary crystals: a prospective study. Am JSurg. 1997;63:69-73.
- [9]. Lange K, Gottschalk M, Gallbladder contractility in early stages of lithogenesis in the lithogenic fed guinea pig. Z. Gastroenterol, 1995;139:179-191.
- [10]. Baig S J, Biswas S, Das S, Basu K and Chattopadhyay. Histopathological changes in gallbladder mucosa in cholelithiasis: correlation with chemical composition of gallstones. Trop. Gastroenterol, 2001;23:25-27.
- [11]. Schwartz S.I, W.A. Dale. primary sclerosing cholangitis: A review and report of six cases. Arch Surg, 1958;77:350-439.
- [12]. Tami Yama . H, H. Yamigiwa. Intestinal metaplasia-Dysplasia carcinoma sequence of the gall bladder. Acta Pathol, 1987;36:989-997.
- [13]. Jaffery. G P , K.B Shilkin , S. Carrello et al. histological and immunohistochemical study of gall bladder lesion in primary sclerosing cholangitis. Gut, 1991;32:424-429.
- [14]. A. Badke , B. Bohm , W. Schwenk et al. histological changes of gall bladder and liver parenchyma in symptomatic cholelithiasis. Dtsch Med Wschr 1993;112(22):809-813.
- [15]. A. Csendes , F. Maluenda , G. Smoke et al. Histological findings of gall bladder mucosa in 95 control subjects and 80 patients with asymptomatic gall stones. Journal of Digestive diseases and sciences, 1998;43:931-934.

#### How to cite this article:

Hemlata Sharma, Manoj Kumar Sharma, Ghanshyam Gupta. EVALUATION OF HISTOLOGICAL CHANGES IN CHRONIC CHOLECYSTITIS AND CHOLELITHIASIS OF HUMAN GALLBLADDER. Int J Anat Res 2014;2(4):752-756. DOI: 10.16965/ijar.2014.540