

DESCRIPTIVE AND TOPOGRAPHIC ANATOMY OF INFRAORBITAL FORAMEN AND ITS CLINICAL IMPLICATION IN NERVE BLOCK

Kopal Saini

Assistant Professor, Department of Anatomy, S. B. H. Medical College, Dhule, Maharashtra, India.

ABSTRACT

Introduction: The aim of this study is to document the morphological and topographical anatomy of the infraorbital foramen (IOF) in relation to the infraorbital rim (IOR) and piriform opening of the nose which is necessary in clinical situations that requires regional nerve blocks.

Methods: A total of 100 Indian dry adult human skulls of unknown age and gender were studied. In each skull the IOF's location was measured with IOR and piriform opening of the nose as reference points. The transverse and vertical diameters of the foramen were also measured. The orientation of accompanying groove and any accessory foramen was noted.

Results: Majority of infra-orbital foramina were directed inferomedially on both the right (53.53 percent) and left (53.12 percent) sides. The overall combined distance between the IOR and IOF was 2 to 12 (6.7 ± 1.67) mm, the combined distance between piriform aperture and IOF was 11 to 23 (17.4 ± 2.43) mm. The overall combined vertical diameter was 2 to 7 (4.3 ± 0.95) mm. The overall combined transverse diameter was 1 to 5 (3.6 ± 0.84) mm. Eleven (5.64 percent) accessory infraorbital foramina were found.

Conclusion: Knowledge of the anatomical characteristics of IOF locations, diameters, directions and its accessory foramina may have important implications in blocking the infraorbital nerve for surgical and local anaesthetic planning.

KEY WORDS: Infraorbital foramen, Infraorbital rim, Infraorbital nerve block.

Address for Correspondence: Dr. Kopal Saini, Assistant Professor, Department of Anatomy, S. B. H. Medical College, Dhule, Maharashtra, India. **E-Mail:** drkopalsaini@gmail.com

Access this Article online

Quick Response code



DOI: 10.16965/ijar.2014.535

Web site: International Journal of Anatomy and Research
ISSN 2321-4287
www.ijmhr.org/ijar.htm

Received: 10 Nov 2014

Peer Review: 10 Nov 2014 Published (O):31 Dec 2014

Accepted: 25 Nov 2014 Published (P):31 Dec 2014

INTRODUCTION

The infraorbital foramen (IOF) is situated bilaterally on the maxillary bone. This foramen is directed inferomedially and through it passes the nerve and vessels of the same name. The infraorbital nerve is the continuation of the maxillary nerve. It then breaks into branches that supply the skin of the upper cheek, the mucosa of the maxillary sinus, the maxillary incisor, canine, and premolar teeth and adjacent upper gingivae, the skin and conjunctiva of the inferior eyelid, part of the nose, and the skin and mucosa of the upper lip [1].

Infraorbital nerve block is a well-recognized regional anaesthetic technique which can provide intraoperative and postoperative pain relief in nasal endoscopic surgeries and also in oral and dental surgeries. The block may also be used to help diagnose neuralgia arising from the second division of the trigeminal nerve. The technique for infraorbital nerve blockade is most commonly performed as it exits the infraorbital foramen just below the inferior orbital rim. The techniques may be associated with the nerve trauma or with hematoma resulting from damage to the infraorbital vessels [2]. There is a need

to develop a technique based upon easily identifiable landmarks palpated through the skin that can be effectively used to target the infraorbital foramen during nerve block.

There may be an accessory branch of the infraorbital nerve that passes through the accessory infra-orbital foramen [3]. Knowledge regarding this accessory foramen is scarce. The foramen should be taken care of during various interventions in this region.

MATERIALS AND METHODS

One hundred dry adult human skulls of indetermined gender were collected from the bone library of medical teaching institutes of Mumbai. The adult status of the skull was determined by the synostosis between the basi-occiput and basi-sphenoid at the cranial base. Data were collected using a pair of dividers, ruler and digital camera. The pair of dividers was spanned across the distances to be measured. Distances were transferred to a ruler to record the readings. Following parameters were considered:

- 1 The orientation of infraorbital foramen was noted and classified as medial, vertical and inferomedial based on its direction (figure-1).
- 2 The vertical distance between superior border of infraorbital foramen and the infraorbital rim (figure- 2).
- 3 The transverse distance between medial border of infraorbital foramen and piriform aperture of the nose (figure-2).
- 4 The transverse diameter of infraorbital foramen.
- 5 The vertical diameter of infraorbital foramen.
- 6 Accessory infraorbital foramen were noted (figure-3).

Fig. 1: Showing directions of infraorbital foramen.

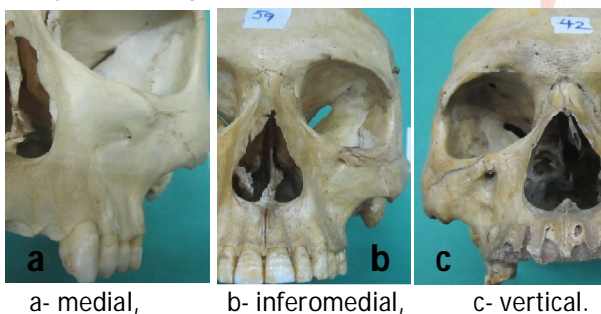
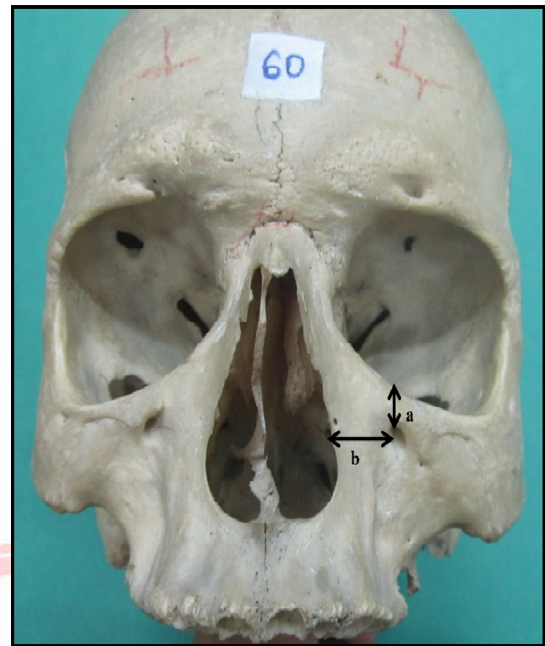
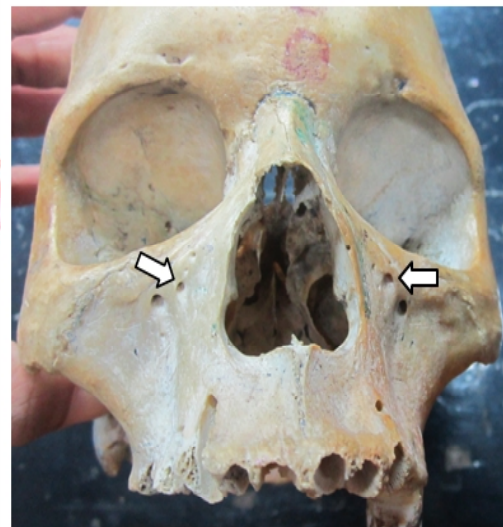


Fig. 2: Showing anterior view of skull and measurements.



a- vertical distance between infraorbital foramen and infraorbital rim, b- transverse distance between infraorbital foramen and piriform opening of the nose.

Fig. 3: Showing accessory infraorbital foramen on both sides.



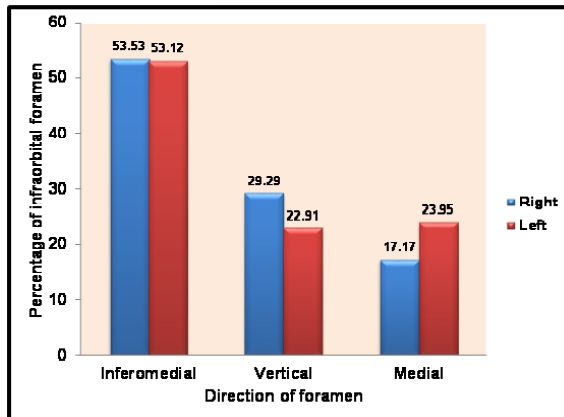
Data were statistically analysed for descriptive statistics and paired T- test using standard software.

RESULTS

Infraorbital foramina in the 100 skulls studied five were damaged. A total of 195 foramina were considered in the study. Infraorbital foramen was directed inferomedially on the right side in 53 (53.53%) foramina and on the left side in 51 (53.12%) foramina; directed vertically on the right side in 29 (29.29%) foramina and on the left side in 22 (22.91%) foramina, directed

medially on the right side in 17(17.17%) foramina and on the left side in 23 (23.95%) foramina as shown in graph 1.

Graph 1: Showing percentage of direction of infraorbital foramen.



The average vertical distances between superior border of infraorbital foramen and the infraorbital rim was found to be 6.7 ± 1.62 (2 - 11) mm on the right side and 6.7 ± 1.73 (3 - 12) mm on the left side (table-1).

Among the 195 foramina studied average transverse distance between medial border of infraorbital foramen and piriform aperture of the nose was 17.4 ± 2.37 (11 - 23) mm on the right side and 17.4 ± 2.58 (12 - 23) mm on the left side (table-1).

Table 1: Showing various dimensions measured for infraorbital foramen.

Parameter	Right			Left		
	Min	Max	Mean±SD	Min	Max	Mean±SD
IOF-IOR	11	23	17.4 ± 2.37	12	23	17.4 ± 2.58
IOF-PA	2	11	6.7 ± 1.62	3	12	6.7 ± 1.73
TD	1	5	3.7 ± 0.82	1	5	3.6 ± 0.86
VD	2	7	4.2 ± 0.97	2	7	4.3 ± 0.93

IOF-IOR is vertical distance between the infraorbital foramen and infraorbital rim, IOF-PA is transverse distance between the infraorbital foramen and piriform opening of the nose, TA is transverse diameter, VA is vertical diameter. Measurements in millimetre

The transverse diameter of the foramen was in the range of 1 - 5 (3.7 ± 0.82) mm on the right side and 1 - 5 (3.6 ± 0.86) mm on the left side whereas the vertical diameter was in the range of 2 - 7 (4.2 ± 0.97) mm and 2 - 7 (4.3 ± 0.93) mm on right and left sides respectively (table-1). Application of student paired t test to all the above parameters showed no significant difference on both sides ($p > 0.05$).

In the 100 skulls studied, 11 accessory infraorbital foramina were observed 5 on right and 6 on left side. In four skulls the foramen was present bilaterally. Most of the accessory foramina were found to be superomedial in position (figure-3).

DISCUSSION

The knowledge of infraorbital foramen's size and location is very essential to surgeons and anaesthetists for various surgical procedures. Data on this foramen are very scanty for Indian population.

The infraorbital foramen was directed with a prominent groove in a few skulls. The infraorbital nerve and its vessels run along the direction of the foramen. While passing the needle to block the nerve, the groove may play an important role in succeeding the anaesthesia. Without accurate knowledge of the morphology of the infraorbital canal, performing an infraorbital nerve block would be more time consuming and less satisfactory. The operator may find the location of the infraorbital foramen with ease, but will not be able to establish a good angle of needle entry. Many studies have dealt with the location of the infraorbital foramen, but only a few discuss the exact morphology of the infraorbital canal. In real clinical situations, most anaesthetists applying an infraorbital nerve block are 'guessing' their way through the infraorbital foramen with the needle. Thus, more research is needed to guide the needle in a more precise direction [4].

Proportion of inferomedially directed infraorbital foramen is largest and comparable with studies done by Boopathi S [5], KK Gour [10] and Kharb JP [11] which also reported inferomedially directed infraorbital foramen as most common. A number of review articles describe the infraorbital foramen to be situated 3-13 mm below the infraorbital rim. In the present study the distance between the IOF and infraorbital rim is 6.7 ± 1.67 mm which is close to values reported by Boopathi S [5], Pavel Michalek [2], Rajni Singh [8], Kharb JP [11], M. G. Elias [13] and Oliveira J [14]. This distance is a major factor that inhibits dentists from using the infraorbital-nerve block is the fear of injury to the patient's eye.

Table 2: Showing comparison of parameters measured with other studies.

Studies	Sample size (no. of skulls)	IOF-IOR, Mean± SD (Range) mm	IOF-PA, Mean± SD (Range) mm	Transverse diameter Mean ± SD (Range) mm	Vertical diameter (Range) mm	Accessory foramina (%)
Boopathi S [5] (India 2010)	80	6.57 ± 1.28 (4.1–11.5)	-	2.87 ± 0.78 (1–5.1)	2.87 ± 0.78 (1–5.1)	16.25
Hussain Saheb Shaik [6] (India 2012)	125	7.13 ± 1.78	18.13 ± 1.85	2.98 ± 0.69	2.89 ± 0.71	-
Pavel Michalek [2] (UK, 2013)	20	0.67 ± 0.09 (cm)	-	-	-	-
P. Karakas [7] (Turkey 2002)	31	6.7 ± 1.9	-	-	-	-
Rajni Singh [8] (India 2011)	55	6.16 ± 1.8 (4 - 12)	15.56 ± 2.6	3.35±1.3	3.57±1.0	-
Kazkayasi M [9] (Turkey 2001)	35	7.19 ± 1.39	17.23 ± 2.64	-	-	5.7
KK Gour [10] (India 2012)	100	7.39 ± 1.63 (4.92 -13.63)	-	-	-	4
Kharb JP [11] (India 2012)	60	6.69 ± 2.86 (3 - 11)	-	-	-	19.1
Lokanayaki V [12] (India 2013)	100	6.33 ± 1.48 (3 - 12)	16.58 ± 2.57 (12 - 22)	-	-	8
M. G. Elias [13] (Brazil 2004)	210	Right: 6.71 ± 1.7 Left: 6.83 ± 1.83	Right: 13.28 ± 2.17 Left: 13.31 ± 2.19	-	-	-
Oliveira J [14] (Brazil 2012)	60	Right: 6.49 ± 1.68 Left: 6.52 ± 1.82	Right: 13.67 ± 2.17 Left: 14.26 ± 1.83	-	-	21.6
Tezer [3] (Turkey 2011)	112	-	-	-	-	7
Bressan C [15] (Italy 2004)	1064	-	-	-	-	4.7
Present study - 2013	100 (195 foramina)	6.7 ± 1.67 (2 - 12)	17.4 ± 2.43 (11 - 26)	3.6 ± 0.84 (1 - 5)	4.3 ± 0.95 (2 - 7)	5.64

IOF-IOR is vertical distance between the infraorbital foramen and infraorbital rim,

IOF-PA is transverse distance between the infraorbital foramen and piriform opening of the nose.

Thus, knowledge of the distance between the infraorbital foramen and infraorbital rim may be useful in identifying the location of the danger zone during dissection of the fracture of the anterior maxillary wall or infraorbital wall, as well as during other surgical procedures [5].

The piriform opening of the nose is an easily palpable border on the face which can be conveniently used to locate the infraorbital foramen. In the present study this average distance between infraorbital foramen and piriform aperture is 17.4 ± 2.43 (11 - 23) mm, which is comparable with findings by Kazkayasi M [9], Lokanayaki V [12], Rajni Singh [8] and Hussain Saheb Shaik [6].

As per the measurements in this study it is hypothesized that the best site for local anaesthetic block for the infraorbital nerve would be about 6.7 mm inferior to the inferior orbital rim and 17.4 mm lateral to the piriform aperture with direction of the needle supero-lateral. These findings need to be correlated to living human subjects and requires further clinical trails.

The transverse and vertical diameters in the present study are 3.6 ± 0.84mm and 4.3 ± 0.95 mm respectively. The dimensions of the foramen

are dependent on the thickness of the neurovascular structures passing through it which may also determine the dosage of drug needed in anaesthetic procedure. There may be an accessory branch of the infra-orbital nerve passing through the accessory infraorbital foramen. The surgeon and anaesthetist should remember about this accessory infraorbital nerve during nerve block since injury to any branch may result in sensory loss or incomplete nerve block.

The frequency of accessory infraorbital foramen may change in terms of sides (right-left). In the study of Bresnan et al. [15] (2004), the frequency of accessory infraorbital foramen was identified to be 4.7%, more often on the left side (2.16%) than on the right side (1.22%). The frequency of accessory infraorbital foramen shows change with respect to race. Berry and Berry (1967) reported the frequency of accessory infraorbital foramen as 4.7% in Egyptians, 6.4% in Nigerian, 6.4% in Palestinian, 6.7% in Indians, 6% in North Americans, 13.2% in South Americans [3].

According to Hanihara and ishida [17] accessory foramen are commonly found in northeast Asian skulls. M. G. Elias et al. [13] found 21 single accessory foramina present bilaterally and

8 double accessory foramina in the 210 Brazilian skulls studied.

Williams PL et al. [16] mentioned that inferior orbital foramen is sometimes double, even multiple, the accessory foramina being usually smaller and recorded at incidences of 2 - 8% in various populations.

In the present study, out of the 100 skulls studied, 11 (5.64%) accessory infraorbital foramina were observed. In 4 skulls these were found bilaterally.

CONCLUSION

All these findings are important for performing local nerve block and surgery in the face in order to avoid injury to the neurovascular structures passing through the foramen. As per the measurements in this study, the best site for local anaesthetic block for the infraorbital nerve would be about 6.7 mm inferior to the inferior orbital rim and 17.4 mm lateral to the piriform aperture with direction of the needle superolateral. Possibility of accessory infraorbital nerve should be kept in mind during clinical procedures.

Conflicts of Interests: None

REFERENCES

- [1] Moore KL, Dalley AF. Nerves of the face. In: Moore KL, Dalley AF, eds. Clinically Oriented Anatomy. 4th ed. Philadelphia: Lippincott Williams & Wilkins, 1999:832-993.
- [2] Michalek P, Donaldson W, McAleavey F, Johnston P, Kiska R. Ultrasound imaging of the infraorbital foramen and simulation of the ultrasound-guided infraorbital nerve block using a skull model. *Surg Radiol Anat* 2013;35:319-22.
- [3] Tezer M, Öztürk A, Akgül M, Gayretli Ö, Kale A. Anatomic and morphometric features of the accessory infraorbital foramen. *J Morphol Sci* 2011; 28(2): 95-7.
- [4] Lee YU, Nam SH, Han SH, Choi KN, Kim TJ. Morphological characteristics of the infraorbital foramen and infraorbital canal using three-dimensional models. *Surg Radiol Anat* 2006;28: 115-20.
- [5] Boopathi S, Chakravarthy MS, Dhalapathy S, Anupa S. Anthropometric analysis of the infraorbital foramen in a South Indian population. *Singapore Med J* 2010;51(9):730-5.
- [6] Shaik HS, Shepur MP, Desai SD, Thomas ST, Maavishettar GF, Haseena S. Morphometric analysis of Infra orbital foramen position in south Indian skulls. *Indian J. Innovations* 2012 July.
- [7] Karakas P, Bozkir MG, Oguz O. Morphometric measurements from various reference points in the orbit of male Caucasians. *Surg Radiol Anat* 2002;24: 358-62.
- [8] Singh R. Morphometric analysis of infraorbital foramen in Indian dry skulls. *Anat Cell Biol* 2011;44:79-83.
- [9] Kazkayasi M, Ergin A, Ersoy M, Bengi O, Tekdemir I, Elhan A. Certain anatomical relations and the precise morphometry of the infraorbital foramen-canal and groove: an anatomical and cephalometric study. *Laryngoscope* 2001 Apr;111(4 Pt 1):609-14.
- [10] Gour KK, Nair S, Trivedi GN, Gupta SD, Anthropometric measurements of infraorbital foramen in dried human skulls. *Int J Biol Med Res.* 2012;3(3):2003-6.
- [11] Kharb JP, Samanta PP, Gupta N. Morphometric analysis of infraorbital foramen in dry adult skulls and its surgical relevance. *Journal of advance Research in Biological Sciences* 2012;4(2):83-7.
- [12] Lokanayaki V. Anatomic variations of infra orbital foramen. *CIBTech Journal of Surgery* ISSN 2319-3875 2013 May-August; 2(2):30-6. Available at URL- <http://www.cibtech.org/cjs.htm>
- [13] Elias MG, Silva RB, Pimentel ML, Cardoso VTS, Rivello T, Babinski MA. Morphometric analysis of the infraorbital foramen and Accessories foraminas in brazilian skulls. *Int. J. Morphol* 2004;22(4):273-8.
- [14] Oliveira J, de EM, Moreira RT, Neto BL, Silva CMF da, Lima FJC. A Morphological and Biometric Study of the Infraorbital Foramen (E2 - Sibai Point) in Adult Skulls. *Int. J. Morphol* 2012;30(3):986-92.
- [15] Bressan C, Guena S, Malerba G, Giacobini G, Giordano M, Robecchi MG et al. Descriptive and topographic anatomy of the accessory infraorbital foramen. *Clinical implication in maxillary surgery.* *Minerva Stomatol* 2004 sep;53(9):495-505.
- [16] Williams PL, Bannister LH, Berry MM, Collin P, Dyson M, Dussek JE, Ferguson MWJ. *Gray's anatomy.* 38th ed. New York: Churchill Livingstone;2000.
- [17] Hanihara T, Ishida H. Frequency variations of discrete cranial traits in major human populations. IV. Vessel and nerve related variations. *J Anat* 2001;199:273-87.

How to cite this article:

Kopal Saini. DESCRIPTIVE AND TOPOGRAPHIC ANATOMY OF INFRAORBITAL FORAMEN AND ITS CLINICAL IMPLICATION IN NERVE BLOCK. *Int J Anat Res* 2014;2(4):730-734.

DOI: 10.16965/ijar.2014.535