

STUDY ON VARIATIONS OF INFERIOR SEGMENTAL BRANCH OF RENAL ARTERY

Chandragirish S ¹, Nanjaiah C.M ², Suhas Y Shirur ³, Shaik Hussain Saheb ^{*4}.

¹ Assistant Professor of Anatomy, Travancore Medical College, Kollam, Kerala, India.

² Professor of Anatomy, JSS Medical College, Mysore, Karnataka, India.

³ Assistant Professor of Physiology, Travancore Medical College, Kollam, Kerala, India.

^{*4} Assistant Professor of Anatomy, JJM Medical College, Davangere, Karnataka, India.

ABSTRACT

Background: The segmental arteries of the kidney supply the organ in such a way that, each renal pole receives its own artery while, the anterior portion between the poles is supplied by an upper and lower segmental vessel. These two arteries also include in their territory the lateral edge of the kidney and adjacent to the strip of parenchyma on the dorsal or posterior aspect of the organ. The knowledge of inferior segmental branch of renal artery is very important for surgeries in its distribution area in kidney.

Materials and Methods: 100 kidneys (Fifty pairs) intact with abdominal aorta were collected from department of Forensic medicine, JSS Medical College and Mysore Medical College. For study of segmental variation Corrosion cast technique method was used. The variations of inferior segmental branch of renal artery were observed and recorded.

Results: In present study type I inferior segmental branch of renal artery were found in - 59% cases, type II in - 6% cases, type III in - 28% cases, type IV in - 2% cases.

Conclusion: The inferior segmental artery from the anterior division of the renal artery is the commonest event - arising in 59%. This is Type I, the normal type. It arises from the renal artery (28%) or from the posterior division (6%) or from the aorta (2%). The knowledge of inferior segmental branch of renal artery helpful in kidney transplantation and renal surgery because these type of surgeries success mainly depends on arterial ligations.

KEYWORDS: Renal artery, Inferior segment, renal surgery, Renal sciences.

Address for Correspondence: Shaik Hussain Saheb, Assistant Professor of Anatomy, JJM Medical College, Davangere, Karnataka, India. Mobile +91-9242056660. **E-Mail:** anatomyshs@gmail.com

Access this Article online

Quick Response code



DOI: 10.16965/ijar.2014.534

Web site: International Journal of Anatomy and Research
ISSN 2321-4287
www.ijmhr.org/ijar.htm

Received: 20 Oct 2014

Peer Review: 20 Oct 2014 Published (O):30 Nov 2014

Accepted: 10 Nov 2014 Published (P):31 Dec 2014

INTRODUCTION

As Stewart stated that the surgical treatment of hydronephrosis, when it is due to compression of the ureter by the lower polar aberrant artery, is by "lifting up the lower polar artery". In the infant the lower polar accessory artery, if present, would be noted to be in close relation to the main renal artery and not to the ureter. With the growth of the child the upper and lower

poles are separated from the main artery getting into a position where it could cause obstruction to the ureter [1]. In 1963, Chatterjee and Dutta studied the segmental pattern in 59 kidneys by arteriography and by corrosion after injecting neoprene latex under a pressure of 150 to 160 mm of mercury into the renal artery. They termed the upper segment of Graves the upper middle and the middle the lower middle segment [2].

According to Weld K J et al, the total accessibility rate for the inferior segmental artery was 88.5% from an anterior and 66.7% from a posterior surgical approach. The apical artery total accessibility rate was 72.3% and 40.5% from an anterior and posterior approach, respectively. The corresponding middle and superior segmental artery total accessibility rates were 50.8% and 32.8% [3].

Kher et al modified the grouping of Graves and they grouped the other arteries also formerly omitted by Graves. They classified 6 types of the superior segmental artery instead of 4 types described by Graves and 4 types of the inferior segmental artery not typed by Graves [4,5].

Four types of the inferior segmental artery variations regarding the mode of the times at its origin described in this work as mentioned in Kher et al study [4].

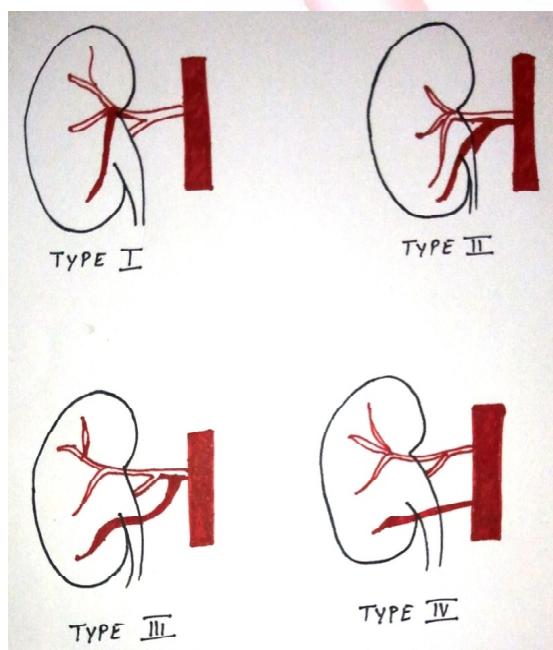
Type I: arises from the anterior division of the renal artery.

Type II: arises from the posterior division of the renal artery.

Type III: arises from the renal artery directly.

Type IV: arises either above or below the renal artery from the aorta [Figure 1].

Fig 1: Inferior segmental artery.



The present study observed three types of variations in inferior segmental branch of renal artery.

MATERIALS AND METHODS

Materials used for this study included Ice Box, 10cc Syringe, Silicon Tube, Silicon Gun, Dissection Instruments, Tag, Formalin, Hydrochloric Acid, Digital Camera, Surgical Gloves, Plastic Bucket, Plastic Jar.

Method: 100 Kidneys were collected from Forensic department, JSS Medical College, Mysore. Once the visceral organs are removed during postmortem the right and left kidneys along with the abdominal aorta were identified. The abdominal aorta was dissected carefully approximately at the level of upper pole and lower pole of the kidney. Care was taken to note the presence of any accessory renal arteries. Corrosion cast method is used for study of variations in inferior segmental branch of renal artery.

RESULTS

In present study out of 100 specimens, type I inferior segmental branch of renal artery were found in - 59% cases, type II in - 6% cases, type III in - 28% cases, type IV in - 2% cases.

In the 100 specimens studied, the inferior segmental artery arises from

Anterior divisional of the renal artery in 59 specimens (59%, Type I the normal).

Aorta in 2 specimens (2%, Type IV);

Renal artery in 28 specimens (28%, type III);

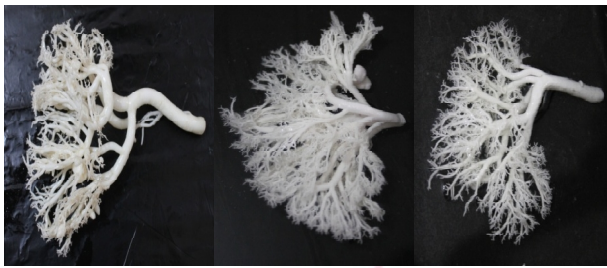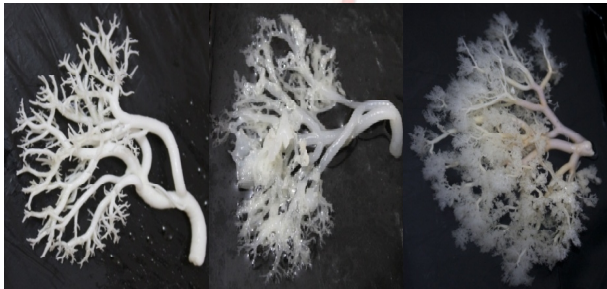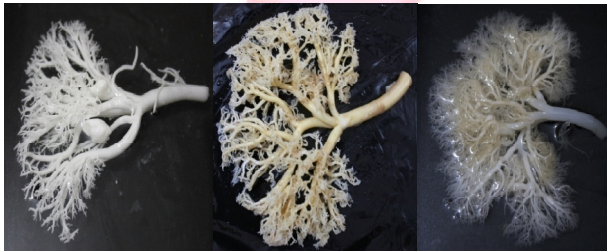Posterior division of the renal artery in 6 specimens (6%, Type II).

Type I is the most common in both males and females.

Type I is seen more often in left male kidneys (38%) than in the left (24%) and in right female kidneys 34% as compared to 22% in the left [Table 1].

Table 1: Inferior Segmental Artery.

Sex	kidneys studied	Type I, from the anterior division of the renal artery	Type II, from the posterior division of the renal artery	Type III, from the renal artery	Type IV, arises either above or below the renal artery from the aorta
	Right	12(24%)	2(4%)	9(18%)	1(2%)
MALE	50	-62%	-4%	-26%	-4%
	Left	19(38%)	0(0%)	4(8%)	1(2%)
	Right	17(34%)	1(2%)	5(10%)	0(0%)
FEMALE	50	-56%	-8%	-30%	0%
	Left	11(22%)	3(6%)	10(20%)	0(0%)
TOTAL	100	59(59%)	6(6%)	28(28%)	2(2%)

Type I: Inferior segmental artery.**Type II:** Inferior segmental artery.**Type III:** Inferior segmental artery.**Type IV:** Inferior segmental artery.

DISCUSSION

The inferior segmental artery most commonly arises from the anterior division (type I) the incidence being 59% of cases in present study. Kher et al[4] study reported same artery in 74%of cases, Verma et al[6] reported in 88%, Servo[7] reported in 47% of cases and Fine H et al [8] study not observed the type I inferior segmental artery, none of the previous study not in agreement with our results.

The inferior segmental artery arises from the the posterior division directly (type II) in 6% of cases. In the present study. Kher et al [4] study reported same artery in 20%of cases, Verma et al [6] reported in 1.02%, Servo[7] reported in 8%

of cases and Fine H et al [8] study not observed the type II inferior segmental artery, servo study results are in agreement with our results and none of the other previous study not in agreement with our results. The inferior segmental artery arises from the renal artery (type III) the incidence being 28% of the specimens in present study. Kher et al [4] study reported same artery in 1.85%of cases, Verma et al[6] reported in 3.06%, Servo[7] not reported any case and Fine H et al[8] study reported 38%. Our results are near to results of Fine H et al study.

The inferior segmental artery is replaced by the inferior accessory renal artery (type-IV) to the extent of 2% of the specimens in present study. Kher et al[4] study reported same in 1.85%of cases, and Fine H et al[8] study reported in 8.4% cases. Our results are in agreement with Kher et al study [Table 2].

Table 2: The Inferior Segmental Artery.

Workers	Servo	Kher et al	Verma et al	H. Fine	Present study
Years	1959	1960	1961	1966	2012
Kidneys studied	100	54	98	107	100
Type I	47%	74%	88%	-	59%
Type II	8%	20%	1.02%	-	6%
Type III	-	1.85%	3.06%	38%	28%
Type IV	-	1.85%	-	8.40%	2%

CONCLUSION

The present study observed the inferior segmental artery from the anterior division of the renal artery is the commonest event –arising in 59%. This is Type I, the normal type. It arises from the renal artery (28%) or from the posterior division (6%) or from the aorta (2%). The knowledge of inferior segmental artery helpful for urology and radiological practice.

Conflicts of Interests: None

REFERENCES

- [1]. Stewart H.H. A new operation for the treatment of hydronephrosis in association with a lower pole (or aberrant artery). B.J.S. 1947; 35: 51-57.
- [2]. Chatterjee, S.K & Dutta A.K. Anatomy international distribution of renal arteries of the human kidney. J. of Ind. Med Assoc. 1963; 40: 155-162.

- [3]. Weld K J, Bhayani S B, Belani J, Ames C D, Hruby G and Landman J. Extrarenal vascular anatomy of kidney: Assessment of variations and their relevance to partial nephrectomy. Urology. 2005; 66: 985-989.
- [4]. Kher G.A. Indra Bhargava & Makhni F.S. Internal branching of the renal artery. Ind. J. of surg. 1960; 22: 563-579.
- [5]. Graves F.T. The anatomy of intrarenal arteries and its application to segmental resection of the kidneys. B.J.S. 1954; XLII: 605-616.
- [6]. Verma M, Chaturvedin RP, Pathak RK. Anatomy of the renal vascular segments. J Anat Soc. 1961;10:12-14.
- [7]. Servo V.V. Segmental arterial distribution in the human kidney. J of Urol 1959 March; 24-26.
- [8]. Fine H and Keen. The arteries of human kidney. J. of Anat 1966; 90: 553-558.

How to cite this article:

Chandragirish S, Nanjaiah C.M, Suhas Y Shirur, Shaik Hussain Saheb. STUDY ON VARIATIONS OF INFERIOR SEGMENTAL BRANCH OF RENAL ARTERY. Int J Anat Res 2014;2(4):716-719.

DOI: 10.16965/ijar.2014.534

