

STUDY ON VARIATIONS OF POSTERIOR DIVISION OF RENAL ARTERY

Chandragirish S ¹, Nanjaiah C.M ², Suhas Y Shirur ³, Shaik Hussain Saheb ^{*4}.

¹ Assistant Professor of Anatomy, Travancore Medical College, Kollam, Kerala, India.

² Professor of Anatomy, JSS Medical College, Mysore, Karnataka, India.

³ Assistant Professor of Physiology, Travancore Medical College, Kollam, Kerala, India.

^{*4} Assistant Professor of Anatomy, JJM Medical College, Davangere, Karnataka, India.

ABSTRACT

Background: Kidney transplantation is the treatment of choice for the vast majority of patients with end stage renal disease. Many of the current challenges with the donor grafts are the results of anatomic variants, such as multiple renal arteries, multiple. The previous studies have shown that use of vessel grafts is associated with a higher incidence of vascular and urologic complications. With this back ground the knowledge of variations in vascular pattern is very helpful for renal transplantation and renal surgeries.

Materials and Methods: 100 kidneys (Fifty pairs) intact with abdominal aorta were collected from department of Forensic department, JSS Medical College and Mysore Medical College. For study of segmental variation Corrosion cast technique method was used. The variations of posterior division were observed and recorded.

Results: In present study type I posterior division of renal artery were found in - 27% cases, type II in - 42% cases, type III in - 25% cases.

Conclusion: In present study we found three types of posterior division of renal artery this knowledge helpful in treatment of renal trauma, renal transplantation, renovascular hypertension, renal artery embolization, vascular reconstruction.

KEYWORDS: Renal artery embolization, Renal trauma, Posterior division of renal artery, Renovascular hypertension.

Address for Correspondence: Shaik Hussain Saheb, Assistant Professor of Anatomy, JJM Medical College, Davangere, Karnataka, India. Mobile +91-9242056660. **E-Mail:** anatomyshs@gmail.com

Access this Article online

Quick Response code



DOI: 10.16965/ijar.2014.532

Web site: International Journal of Anatomy and Research
ISSN 2321-4287
www.ijmhr.org/ijar.htm

Received: 20 Oct 2014

Peer Review: 20 Oct 2014 Published (O):30 Nov 2014

Accepted: 10 Nov 2014 Published (P):31 Dec 2014

INTRODUCTION

The renal arteries arise off the side of the abdominal aorta, immediately below the superior mesenteric artery. The renal arteries carry a large portion of total blood flow to the kidneys. Up to a third of total cardiac output can pass through the renal arteries to be filtered by the kidneys. The arterial supply of the kidneys is variable and there may be one or more renal arteries supplying each kidney. It is located above the renal vein. The branching pattenen of

renal artery is very vulnerable and interest. Clinically the renal artery branching pattern having good attention for renal surgeons [1]. In 1983 A study of the intrarenal arterial pattern of kidney by corrosion cast method has been carried out by Ajmani.M.L on 100 kidneys obtained from post mortem bodies. The abnormal origin of renal artery is rare and observed only in 2% cases. The renal artery divides extrarenally in about 68%, intrarenally in about 18% and at the hilum in 14% cases into anterior

and posterior divisions. In very rare cases (2%) both the divisions arise separately at one point from abdominal aorta. Alternatively renal artery may not divide into anterior and posterior divisions but continues as anterior division and divide into upper, middle and lower segmental arteries in 1% cases. The branching pattern of anterior division shows 5 different variations grouped in 5 groups. The branching pattern of posterior division shows 3 different patterns. Vary rarely (1%) the posterior division is absent [2].

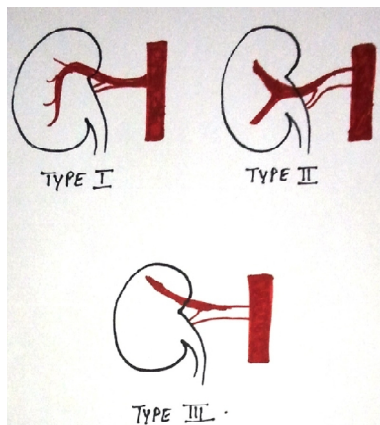
Kyle.J.Weld in the year 2005 stated the vascular anatomy consisted of zero, one, or two presegmental arteries in 49.3%, 31.5%, and 19.2% of the kidneys, respectively. From a posterior approach, the posterior segmental artery was accessible to isolated clamping in 81.8% of the kidneys (segmental accessibility rate) and was accessible to clamping at the presegmental level in 12.7% (presegmental accessibility rate) for a total accessibility rate of 90.9%[3].

The types of posterior division as follows - type I runs downward behind the ureteric pelvis with a lateral convexity from which 3 or more branches, not named, arise to supply the posterior segment of the kidney.

The posterior division of types II terminates by bifurcation or trifurcation before supplying the posterior renal arterial segment.

The posterior division of type III gives off the superior, anterior inferior or the inferior segmental artery or any two of them (all branches of the anterior division usually). It supplies the posterior segment of the kidney either before giving off above branches or after.

Fig. 1: Posterior division of renal artery.



MATERIALS AND METHODS

100 kidneys (Fifty pairs) intact with abdominal aorta were collected from department of Forensic department, JSS Medical College and Mysore Medical College. For study of segmental variation Corrosion cast technique method was used. The variations of posterior division were observed and recorded.

RESULTS

In present study type I posterior division of renal artery were found in 27% cases, type II in - 42% cases, type III in 25% cases.

The posterior division of the renal artery: The posterior division supplies only the posterior segment in 42 specimens (42 % type II).

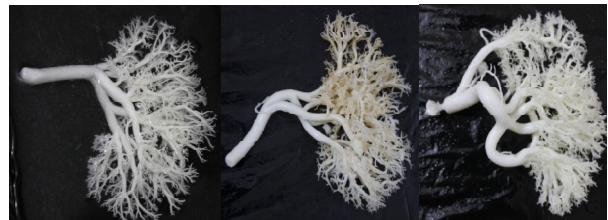Type II is most common both in males (44%) and females (40%)

It is absent in two specimens (Table 1).

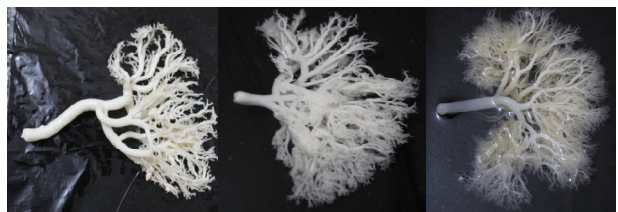Table 1: The posterior division of the renal artery.

Sex	Kidneys studied	Type I	Type II	Type III	
MALE	50	Right	6(12%)	12(24%)	6(12%)
		Left	9(18%)	10(20%)	5(10%)
	50	Right	6(12%)	10(20%)	6(12%)
		Left	6(12%)	10(20%)	8(16%)
TOTAL	100	27(27%)	42(42%)	25(25%)	

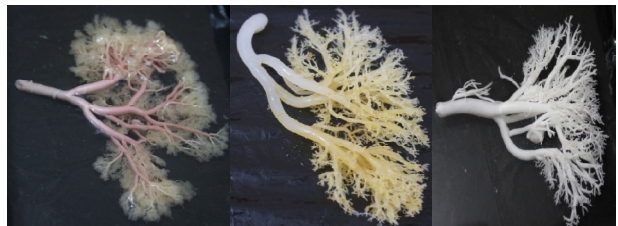Type I: Posterior division of renal artery.



Type II: Posterior division of renal artery.



Type II: Posterior division of renal artery.



DISCUSSION

The posterior division of the renal artery Supplies only the posterior segment (type I) in about 27% in the present study. Kher et al[4] study reported 53%, Verma et al[5] study reported 63.2%, Fine H et al[6] study reported Type I as 50% none of the previous studies are in agreement with present study results regarding type I.

Type II Posterior division of the renal artery found in 42% in the specimens of the present study. Verma et al[5] study reported the type II as 38.77% and Fine H et al[6] study reported that 40% cases as type II. The two mentioned previous studies are in agreement with our present study results regarding type II.

Type III Posterior division of the renal artery found in 25.9% in the specimens of the present study. Verma et al[5] study observed the type III posterior division of renal artery but not mentioned the exact percentage. Kher et al[4] reported that as 25.9% and Fine H et al study not observed the type III. The kher et al study are in agreement with our present study results regarding type III [Table 2].

Table 2: The Posterior Division Of The Renal Artery.

Workers	Kher et al	Verma et al	H.Fine	Present study
Years	1960	1961	1966	2012
No of Kidneys studied	54	98	107	100
Type I	50%	63.20%	50%	27%
Type II	-	38.77%	40%	42%
Type III	25.90%	Observed	-	25%

CONCLUSION

In present study observed the three types of posterior division of renal arteries. The present study was undertaken to observe the origin, branching pattern, variations of posterior division of renal artery the knowledge of this division is helpful in segmental renal vascular construction during the surgeries kidney specially in kidney transplant and partial nephrectomy.

Conflicts of Interests: None

REFERENCES

- [1]. Hollinshead W. H. Renovascular anatomy. Post graduate medicine.1966; 44: 241-244.
- [2]. Ajmani ML, Ajmani K. To study the intrarenal vascular segments of human kidney by corrosion cast technique. Anat Anz. 1983; 154(4):293-303.
- [3]. Kyle j. Weld, Sam b. Bhayani, Jay belani, Caroline d. Ames, Greg hruby, jaime landman. Extrarenal vascular anatomy of kidney: Assessment of variations and their relevance To partial nephrectomy. Urology 2005; 66 (5):985-989.
- [4]. Kher GA, Indra B, Makhaniz JS. Intrarenal branching of renal arteries. Int J Surg.1960;12:263-69.
- [5]. Verma M, Chaturvedin RP, Pathak RK. Anatomy of the renal vascular segments. J Anat Soc. 1961;10:12-14.
- [6]. Fine H and Keen. The arteries of human kidney. J. of Anat 1966; 90: 553-558.

How to cite this article:

Chandragirish S, Nanjaiah C.M, Suhas Y Shirur, Shaik Hussain Saheb. STUDY ON VARIATIONS OF POSTERIOR DIVISION OF RENAL ARTERY. Int J Anat Res 2014;2(4):709-711.

DOI: 10.16965/ijar.2014.532