

# MORPHOLOGY OF ULNAR NERVE IN AXILLA & ARM & ITS VARIATIONS

Vijay Kumar S <sup>\*1</sup>, Priya Ranganath <sup>2</sup>.

<sup>\*1</sup> Assistant Professor, Department of Anatomy, Basaveshwara Medical College Hospital and Research Centre, Chitradurga, Karnataka, India.

<sup>2</sup> Professor & Head, Department of Anatomy, Bangalore Medical College & Research Institute, Bangalore, Karnataka, India.

## ABSTRACT

The ulnar nerve arises from the medial cord (C8, T1); medial cord also receives fibres from the ventral ramus of C7. Lesions of the ulnar nerve occur behind the medial epicondyle & in the cubital tunnel. When muscles are affected due to ulnar nerve dysfunction, there is ulnar neuropathy at the shoulder, arm & elbow.

The study was done on 50 embalmed human cadavers (25 right & 25 left) of both sexes of South Indian adult population obtained from the Department of Anatomy, Bangalore Medical College and Research Institute, Bangalore.

Variations in the ulnar nerve in its presence, origin, relations, distribution & communications were observed. Ulnar nerve was present in all 50 upper limb specimens (100%). Ulnar nerve originated from the medial cord of the brachial plexus in 49 cases (98%). In 1 case (2%), the ulnar nerve received C7 fibers from lateral cord i.e. the lateral root of the median nerve and then later fused with the median root of the median nerve. In 49 specimens (98%) ulnar nerve took origin from the tip of the acromion processes. In 1 case (2%) it took origin from distal to the tip of the acromion process. 49 specimens (98%) showed the normal course, i.e. medial to axillary & brachial artery. 1 case (2%) showed ulnar nerve present anterior to the third part of the axillary artery and brachial artery. In the midarm it passed medially as a normal course, then runs distally through the cubital tunnel.

The awareness of these variations along the normal pattern are helpful for the interventional radiologists, orthopaedicians and neurologists in preventing untoward iatrogenic injury to the ulnar nerve during radiological procedures or operating on fractured patients or diagnostic therapy.

**KEY WORDS:** Ulnar Nerve, Axilla, Arm, Morphology, Cadaver, Variations, Median Nerve.

**Address for Correspondence:** Dr. Vijay Kumar S, Assistant Professor, Department of Anatomy, Basaveshwara Medical College Hospital And Research Centre, Chitradurga, Karnataka, India.

**E-Mail:** drvijaysh2009@gmail.com

## Access this Article online

### Quick Response code



DOI: 10.16965/ijar.2014.523

**Web site:** International Journal of Anatomy and Research  
ISSN 2321-4287  
[www.ijmhr.org/ijar.htm](http://www.ijmhr.org/ijar.htm)

Received: 28 Oct 2014

Peer Review: 28 Oct 2014 Published (O):30 Nov 2014

Accepted: 10 Nov 2014 Published (P):31 Dec 2014

## INTRODUCTION

The ulnar nerve arises from the medial cord (C8, T1); medial cord also receives fibres from the ventral ramus of C7. The ulnar nerve runs distally through the axilla medial to the axillary artery, between it and the vein. Continuing

distally medial to the brachial artery till midarm, it pierces the medial intermuscular septum, inclining medially & descends anterior to the medial head of the triceps to the interval between the medial epicondyle and olecranon, along with the superior ulnar collateral artery. Its relation to the brachial artery and medial

epicondyle makes it easy to trace its proximal course. At the elbow, it lies in a groove on the dorsum of the medial epicondyle. It gives articular branch to the elbow joint, which arises while passing between the medial epicondyle and olecranon, & muscular branches [1].

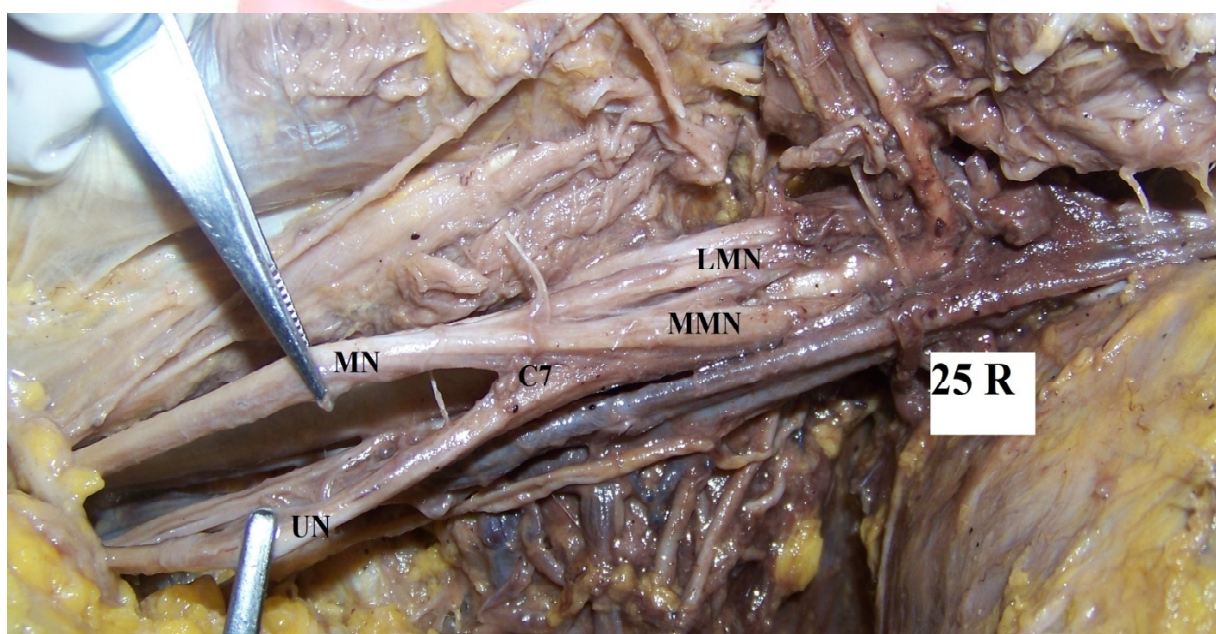
Lesions of the ulnar nerve occur behind the medial epicondyle & in the cubital tunnel. When muscles are affected due to ulnar nerve dysfunction, there is ulnar neuropathy at the shoulder, arm & elbow.

## MATERIALS AND METHODS

The study was done on 50 embalmed human cadavers (25 right & 25 left) of both sexes of

South Indian adult population obtained from the Department of Anatomy, Bangalore Medical College and Research Institute, Bangalore. The upper limbs were dissected according to guidelines given in the Cunningham practical manual. The axilla was dissected accordingly, its contents were traced & identified. The presence or absence of ulnar nerve was noted, source of origin of ulnar nerve, its level of origin recorded with tip of acromion as bony point of reference, relation with neighbouring structures & its course & distribution till cubital fossa were observed. All its branches were identified. Intercommunication between the ulnar nerve and median nerve were looked for.

**Fig. 1:** From lateral root of median nerve.



UN – Ulnar Nerve, MN – Median Nerve, LMN – Lateral Root Of Median Nerve, MMN – Medial Root Of Median Nerve, C7 – ventral rami of C7 fibres.

## RESULTS

The observations that were made are:

1. Presence of ulnar nerve: Ulnar nerve was present in all 50 upper limb specimens (100%).
2. Source of origin: Ulnar nerve originated from the medial cord of the brachial plexus in 49 cases (98%). In 1 case (2%), the ulnar nerve received C7 fibers from lateral cord i.e. the lateral root of the median nerve and then later fused with the median root of the median nerve (fig. 1).
3. Level of origin: In 49 specimens (98%) ulnar nerve took origin from the tip of the acromion

processes. In 1 case (2%) it took origin from distal to the tip of the acromion process.

4. Course of ulnar nerve: 49 specimens (98%) showed the normal course, i.e. medial to axillary & brachial artery. 1 case (2%) showed ulnar nerve present anterior to the third part of the axillary artery and brachial artery. In the midarm it passed medially as a normal course, then runs distally through the cubital tunnel.

## DISCUSSION

Few authors have described absence of ulnar nerve. In the present study, all cases (100%) had ulnar nerve.



Sachdeva & Singla reported that anterior division of C8, T1 formed medial cord, which gives rise to the medial root of the median nerve and the ulnar nerve normally. Medial cord gave rise to medial root of the median and the medial cutaneous nerve of the forearm. Later both the roots of the median nerve united with each other. Then ulnar nerve arose 4cm distally from the medial root of median, and continued as ulnar nerve proper and median nerve proper. Rest of the course of the ulnar nerve was normal [2].

Gonclaves et al reported about the origin of the ulnar nerve from the posterior cord of the brachial plexus [3].

Chaware et al reported that the anterior division of the middle trunk and lower trunk joined to form ulnar nerve proper. Thus root value of ulnar nerve was C7, C8, T1 [4].

Sontakke et al reported that the anterior division of the upper and middle trunk joined to give one of the branches, that is, lateral root of the median nerve. It gave fibres to both median root of the median nerve and ulnar nerve in the ratio 20:80. Rest of the course of the ulnar nerve was normal. Thus root value of ulnar nerve was C5, 6, 7, 8, T1 [5].

Ramchandran et al reported that ulnar nerve also received contribution from lateral root of median nerve [6].

In the present study, the ulnar nerve originated from the medial cord of brachial plexus in 49 cases (98%). In one case (2%), the ulnar nerve arose from the lateral root of median nerve i.e. from C7 root. Cases of ulnar nerve originating from sources other than medial cord or lateral root of median nerve was not found in the present study.

The normal point of origin of ulnar nerve was not discussed in the earlier studies.

In the present study, the level of origin of ulnar nerve when it arose from the lateral root of median nerve was definitely lower than the cases which had normal origin.

Jamuna described that the ulnar nerve after arising from the medial cord was found to be lateral to the axillary artery and then it crossed the axillary artery from lateral to medial and further it coursed down medial to the brachial

artery [7].

Arora & Dhingra reported a case, where right biceps brachii was supplied by both median and ulnar nerve. They also reported absence of the musculocutaneous nerve and third head of the biceps brachii [8].

Gupta et al in their case reported that anomalous communicating branches were observed between a) medial root of median nerve and ulnar nerve and b) ulnar nerve to radial nerve [9].

In the present study, 49 cases (98%) showed the normal course i.e. ulnar nerve medial to axillary artery and between axillary vein in shoulder, then in the arm it was medial to the brachial artery. In 1 case (2%) ulnar nerve was anterior to the axillary artery and passed medial to the brachial artery in arm. Rest of the course in all specimens was normal.

The results of the study discussed, clearly show that the ulnar nerve variations are not uncommon. It shows variations from the origin and course in relation to the artery in arm, however course of the ulnar nerve in forearm and hand was much normal. The dorsal cutaneous branch of the ulnar nerve showed high origin in few specimens. Trifurcation was also seen, communicating branch between ulnar nerve and median nerve was the most common variation and this can be considered as the normal branching of ulnar nerve with median nerve in hand.

Variations in the ulnar nerve are not uncommon. The ulnar nerve is the second commonest to involve in entrapment neuropathy. These variations gain importance during surgical procedures of shoulder & elbow, when the presence of an unexpected variation can lead to iatrogenic damage. The variations can also pose difficulty in diagnosis of neurological syndromes. Good knowledge of the distribution and variations of the ulnar nerve and its possible communications with the median nerve are valuable in trauma to the upper limb. All these variations can be diagnosed by electrodiagnostic tests. Electromyography is a useful tool in diagnosing uncommon variations in the arm, forearm and hand. There is a need to enhance the awareness of the possible varia-

-tions and the frequency with which they occur. Thus the awareness of these variations along the normal pattern are helpful for the interventional radiologists, orthopaedicians and neurologists in preventing untoward iatrogenic injury to the ulnar nerve during radiological procedures or operating on fractured patients or diagnostic therapy.

**Conflicts of Interests: None**

## REFERENCES

- [1]. Standring S. Gray'S Anatomy. 40<sup>th</sup>edn. Churchill Livingstone: Elsevier. London. 2008; 780-781.
- [2]. Sachdeva K, Singla RK. An unusual origin of an ulnar nerve from a median nerve – a case report; Journal of Clinical and Diagnostic Research, 2011; 5(6): 1270-1271.
- [3]. Goncalves J, Duparc F, Auquit- Auckbur I, Milliez PY. Constitutional anomalies of the terminal branches of the brachial plexus in the axial and the brachial regions. Results of 42 cases and review of literature. Ann Chir Plast Esthet, 2002; 47(1): 30-35.
- [4]. Chaware PN, Ughade JM, Pandit SV, Maske GL. Variant branches of brachial plexus – a case report. International Journal of Anatomical Variations, 2012; 5: 5–7.
- [5]. Sontakke BR, Tarnekar AM, Waghmare JE, Ingole IV. An unusual case of asymmetrical formation and distribution of median nerve – A Case Report. International Journal of Anatomical Variations, 2011; 4: 57–60.
- [6]. Ramchandran K, Kanakasabapathy I, Holla SJ. Multiple variations involving all the terminal branches of the brachial plexus and the axillary artery – a case report. Eur J Anat, 2006; 10 (3): 61-66.
- [7]. Jamuna M. Clinically significant variations of the cords of the brachial plexus in relation to axillary artery – a case report. International Journal of Anatomical Variations, 2011; 4: 9-11.
- [8]. Arora L, and Dhingra R. Unusual nerve supply of biceps from ulnar and median nerve and third head of biceps. a case report. Indian Journal of Plastic Surgery, July- December 2006; 39(2): 172-174.
- [9]. Gupta M, Goyal N, and Harjeet. Anomalous communications in the branches of brachial plexus – a case report. The Journal of Anatomical Society of India, 2005; 54(1): 01-03.

### How to cite this article:

Vijay Kumar S, Priya Ranganath. MORPHOLOGY OF ULNAR NERVE IN AXILLA & ARM & ITS VARIATIONS. Int J Anat Res 2014;2(4):677-680. DOI: 10.16965/ijar.2014.523