

## Case Report

# CONGENITAL DISLOCATION OF RIGHT HIP JOINT: THE IMPORTANCE OF DYNAMIC ASSESSMENT

Pranita Viveki \*<sup>1</sup>, R G Viveki <sup>2</sup>.

\*<sup>1</sup> Tutor, Department of Anatomy, Belgaum Institute of medical sciences, Belgaum, karnataka, India.

<sup>2</sup> Associate Professor, Department of Community Medicine, Belgaum Institute of medical sciences, Belgaum, Karnataka, India.

## ABSTRACT

Congenital Dislocation of Hip (CDH), is one of the most common congenital diseases in the orthopedic field. It is also known as Developmental Dysplasia of Hip. The condition can be diagnosed by clinical, ultrasonographic and radiological examination. Here we are reporting two days old male baby with congenital dislocation of right hip joint. The goal of treatment is to obtain a reduction to provide an optimal environment for femoral head and acetabular development. Early diagnosis is the most crucial aspect of the treatment of children with congenital dislocation of hip. If dislocation remains undiagnosed or neglected, the secondary pathological changes take place. Education of primary care colleagues, in making the diagnosis and prompt referral for management is recommended.

**KEY WORDS:** Dislocation, Hip, Congenital, Treatment.

**Address for Correspondence:** Dr. (Mrs) Pranita R Viveki, Tutor, Dept of anatomy, Belgaum Institute of Medical Sciences, Belgaum 59001, Karnataka, India.

**E-Mail:** rgviveki@gmail.com, prviveki@gmail.com

## Access this Article online

### Quick Response code



DOI: 10.16965/ijar.2014.516

**Web site:** International Journal of Anatomy and Research  
ISSN 2321-4287  
[www.ijmhr.org/ijar.htm](http://www.ijmhr.org/ijar.htm)

Received: 15 Oct 2014

Peer Review: 15 Oct 2014 Published (O):30 Nov 2014

Accepted: 03 Nov 2014 Published (P):31 Dec 2014

## INTRODUCTION

"There are persons, who, from birth or from disease have dislocations outward of both the thighs; in them, then, the bones are affected in like manner, but the fleshy parts in their case lose their strength less; . . . They have the equal use of both their legs, for in walking they totter equally to this side and that"[1]. Thus Hippocrates, in About Articulations described hip dislocations in the second century B.C.

Congenital dislocation of the hip is a genetically influenced condition in which there is a disturbance of the normal anatomy of the hip, either a complete dislocation of the head of the

femur from the acetabulum or a partial displacement (subluxation) from the socket. Inadequate development of the roof of the socket (dysplasia) and laxity or elongation of the ligaments and capsule of the joint may be primary pathogenic features; both will be discussed in greater detail later. True congenital dislocation of the hip must be distinguished from teratologic dislocations such as may occur in arthrogyrosis multiplex congenita, diastrophic dwarfism, Larsen's syndrome and other rare generalized mesenchymal disorders. It should also be distinguished from the paralytic dislocations which may occur in cerebral palsy, myelomeningocele, and following paralytic

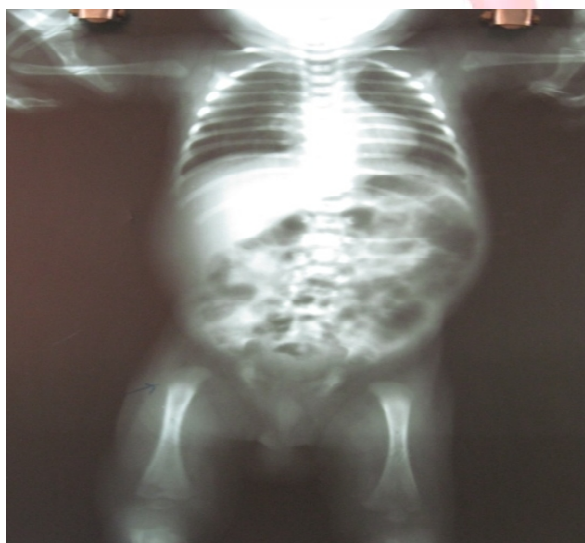
anterior poliomyelitis [2].

It has been estimated [3] that 5,300 new cases occur annually in the United States. Paletta, in 1775, was the first to use the term subluxation. As early as 1784 Camper is said to have commented on the preponderance of affected females. Dupuytren [4], in 1826, described the autopsy findings in the case of a 74-year-old man who also suffered from "retention of urine, terminating fatally. Most notably, Ortolani, an Italian pediatrician in the early 1900s, evaluated, diagnosed and began treating congenital dislocation of hip. Galeazzi later reviewed more than 12,000 cases of this condition and reported the association between apparent shortening of the flexed femur and hip dislocation. Since the significant progress has been made in the evaluation and treatment of CDH [ 5 ,6].

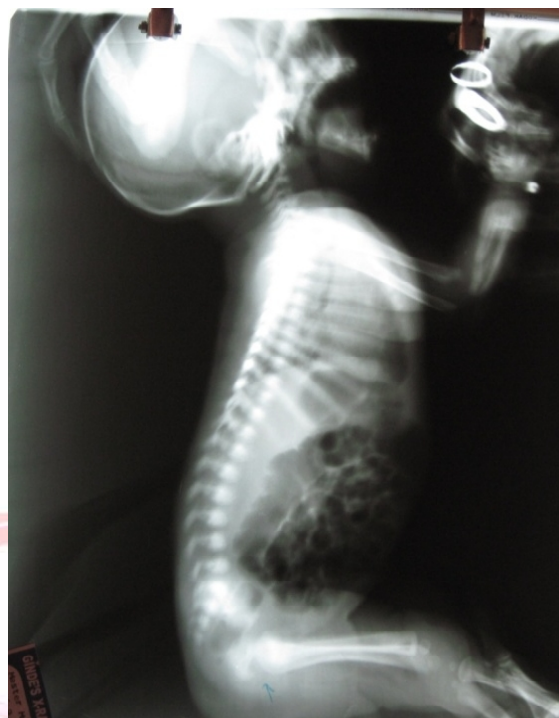
### CASE REPORT

A two days old male baby delivered by caesarian section with birth weight of 2100 grams was admitted in a neonatal care hospital for anuria and septicaemia. His whole body X-ray and sonography revealed the condition. In x-ray ,there was congenital dislocation of right hip joint [fig no. -1] In addition, the sonography showed the changes of hyperechoic renal pyramids in both kidneys suggestive of medullary nephrocalcinosis.[fig no.-2] His perinatal records showed intrauterine growth retardation with moderate oligohydramnios, delivered by caesarian section at 38 weeks of gestation and was treated in NICU care after birth.

**Fig. 1:** Showing congenital dislocation of right hip joint.



**Fig. 2:** Hyperechoic renal pyramids in both kidneys suggestive of medullary nephrocalcinosis.



### DISCUSSION

The rate of congenital dislocation of the hip in general population in North America and Europe is approximately 1.5 per 1000 live birth. A positive family history increases the incidence of congenital dislocation of hip approximately 35 times[7] Girls are more frequently affected than boys. An estimated 80% of the persons with CDH are female. The left hip is more frequently involved. Breech presentation increases the incidence of congenital dislocation of hip to approximately 20% (compared with 2-4% in the general population). Other risk factors are first born baby, oligohydramnios. The high rate of a ssociation of congenital dislocation of hip with other intrauterine molding abnormalities such as torticollis, calcaneovalgus and metatarsus adductus support the theory of "crowding phenomenon". The three modalities, clinical examination, x-ray and ultrasound are available for the diagnosis of congenital dislocation of the hip in the neonates[8]. During physical examination, Initially, the two testes, Ortoloni and Barlow are then performed [8 ,9]. In 1957, Pavlik reported a harness for the treatment of congenital dislocation of the hip. This was introduced into Japan in the same year. It has been proved by many Japanese orthopaedic surgeons that

the incidence of aseptic necrosis of the femoral head can be reduced in frequency by this method [10]. According to Pavlik, the age of application ranged from 2 to 12 months. Takahashi (1985) reported age at the start of initial treatment ranging from 3 to 12 months[11].

### Genetic Counseling

The empiric recurrence risks have been calculated" [12] as follows: (1) with normal parents, the risk to subsequent brothers of an index patient is 1 percent, to subsequent sisters, 11 percent. (2) If one parent has a congenital hip dislocation the risk to a son is 6 percent, to a daughter 17 percent. (3) If there are one parent and one child in an affected family, the risk to a second child rises dramatically to 36 percent. The implications of these data are obvious; at the very least careful and repeated examinations of all infants in such families must be started at birth.

### CONCLUSION

Early diagnosis is the most crucial aspect of the treatment of children with congenital dislocation of hip. This result in 95% success rate of treatment with a low risk of complications. If dislocation remains undiagnosed or neglected the secondary pathological changes takes place. The treatment becomes more complex and hence increases the morbidity and decreases the chances of normal development of hip. We must educate our primary care colleagues in making the diagnosis early and initiating prompt referral.

**Conflicts of Interests: None**

### REFERENCES

- [1]. Adams F. The Genuine Works Of Hippocrates, Vol 2. New York, 1886, Pp 131-132.
- [2]. Specht Ee. Congenital Dislocation Of The Hip (Medical Progress). West J Med 124:18-28, Jan 1976.
- [3]. Ramsey Pl. Early Detection And Treatment Of Congenital Hip Dislocation. Paper Read At The Annual Meeting Of The American Academy Of Orthopaedic Surgeons, 1973.
- [4]. Rang M. Anthology Of Orthopaedics. Edinburgh And London, E. And S. Livingstone, Ltd., 1966, Pp 128-130.
- [5]. Aium Practice Guideline For The Performance Of An Ultrasound Examination For Detection And Assessment Of Developmental Dysplasia Of The Hip. J Ultrasound Med. Jan 2009; 28(1):114-9 .
- [6]. Janssen D, Kalchschmidt K, Katthagen Bd. Triple Pelvic Osteotomy As Treatment For Osteoarthritis Secondary To Developmental Dysplasia Of The Hip. Int Orthop. Feb 12 2009. 5. Arts Td, Levine Db, Lim Wm, Et Al: Neonatal Diagnosis, Treatment And Related Factors Of Congenital Dislocation Of Hip, Clin Or Thop 1975; 110:112.
- [7]. Broughton Ns, Brougham Di, Cole Wg, And Menelaus Mb: Reliability Of Radiological Measurements In The Assessment Of The Child's Hip, J Bone Joint Surg 1989; 71-B: 6.
- [8]. Ortolani M. Congenital Hip Dysplasia In The Light Of Early And Very Early Diagnosis, Clin Orthop 1976; 119:6.
- [9]. Barlow Tg. Early Diagnosis And Treatment Of Congenital Dislocation Of Hip, J Bone Joint Surg 1962; 44-B: 292.
- [10]. Pavlik. The Functional Method Of Treatment Using A Harness With Stirrups As The Primary Method Of Conservative Therapy For Infants With Congenital Displacement Of The Hip. Z Orthop 1957;89:3 4 1
- [11]. Takahashi. Functional Treatment Of Congenital (Riemenbügel). J Jap Orthop Assoc 1985;59:973-984. Reprinted In Clin Orthop 1992, 2 8 1 , 4 - 1 0 ).
- [12]. Wynne- Davies R. Heritable Disorders In Orthopaedic Practice. London, Blackwell Scientific Publications, 1973, P 196.

#### How to cite this article:

Pranita Viveki, R G Viveki. CONGENITAL DISLOCATION OF RIGHT HIP JOINT: THE IMPORTANCE OF DYNAMIC ASSESSMENT. Int J Anat Res 2014;2(4):657-659. DOI: 10.16965/ijar.2014.516