

## GROSS MORPHOLOGY OF THE HIP ARTICULATION OF BUFFALO CALVES (BUBALUS BUBALIS)

Supriya. B <sup>\*1</sup>, T.S. Chandrasekhara Rao <sup>2</sup>, P. Jagapathi Ramayya <sup>3</sup>, R. V. Suresh Kumar <sup>4</sup>.

<sup>\*1</sup> Assistant Professor, College of Veterinary Science, Tirupati, India.

<sup>2</sup> Dean, Faculty of Veterinary Science, Sri Venkateswara Veterinary University, Tirupati, India.

<sup>3</sup> Professor and Head, Department of Veterinary Anatomy, C.V.Sc, Proddatur, India.

<sup>4</sup> Professor and Head, Department of Veterinary Surgery and Radiology, C.V.Sc, Proddatur, India.

### ABSTRACT

**Back ground:** The vulnerability of the buffalo to the luxation of the hip articulation previous to and during parturition encouraged the investigation in this species. The literature reviewed did not reveal complete anatomical descriptions of the coxofemoral articulation of buffalo. Hence the study was undertaken.

**Purpose:** to study the different anatomical aspects of the hip joint which are specific to buffaloes.

**Methods and Results:** A total number of fifteen hip joints of buffalo calves procured from the local slaughter house and department of Veterinary Anatomy were studied in the Department of Veterinary Anatomy, College of Veterinary Science, Tirupati irrespective of breed, sex and nutritional status. The gross morphology of joints and relations were studied. The round ligament of buffalo was stronger compared to cattle. A thick fibrous stratum of articular capsule was present. A few arched and semi-circular fibers were seen in the articular capsule but zona orbicularis was absent. The best developed periarticular ligament in the buffalo hip was the iliofemoral ligament. It was a thick cord of connective tissue extending from a nodule below and behind the ischiatic spine and spreaded over the capsula articularis and finally attached to the trochanter major and trochanteric ridge. The pubocapsular ligament was located on the ventral surface of the joint capsule and blended with it. Compared to the most of other quadrupeds the periarticular ligaments were well developed in buffalo. The iliofemoral ligament was mostly helpful in preventing the hip from excessive extension and adduction. The relative development of the periarticular ligaments in the biped and quadrupeds were probably in accordance with comparative weight that this articulation must support.

**Potential implications:** An understanding of the basic anatomy of the hip helps in understanding pathology and can greatly assist the surgeon in appropriately diagnosing and treating the problems.

**KEY WORDS:** Hip joint, Ilio-femoral ligament, Buffalo calf, Capsula articularis, Coxofemoral joint.

**Address for Correspondence:** Dr. Supriya. B, Assiastant Professor, Department of Veterinary Anatomy, College of Veterinary Science, Tirupati, A.P, India-517502.

**E-Mail:** supriyabotlagunta@gmail.com

### Access this Article online

#### Quick Response code



DOI: 10.16965/ijar.2014.502

**Web site:** International Journal of Anatomy and Research  
ISSN 2321-4287  
www.ijmhr.org/ijar.htm

Received: 10 Sep 2014

Peer Review: 10 Sep 2014 Published (O):31 Nov 2014

Accepted: 03 Nov 2014 Published (P):31 Dec 2014

### INTRODUCTION

The coxofemoral articulation was a ball and socket joint formed by the acetabulum of the os coxae and the proximal end of the femur. The acetabulum was a cotyloid cavity located at the

junction of the ilium(40%), ischium(30%) and pubis(30%). The acetabulum was hemispherical in shape and was directed ventrolateral. In the fresh state it received the head of the femur. This joint was responsible for transferring the

weight of the body from the axial skeleton into the lower extremities of hind limbs. It also provided remarkable stability to the body during locomotion. Roberts [1] associated frequent luxation of the coxofemoral articulation of the bovines with advanced pregnancy. Understanding of hip joint anatomy constitutes an important background for the diagnosis and treatment of hip disorders. Extensive information was available on the anatomy of the joints of horse [2], dogs [3] [4], pig [2], ox [4], [5] and in human [6] in standard text books dealing with anatomy and clinical anatomy. Deficiency of the detailed anatomical description of the coxofemoral articulation was met in this specific study.

## METHOD

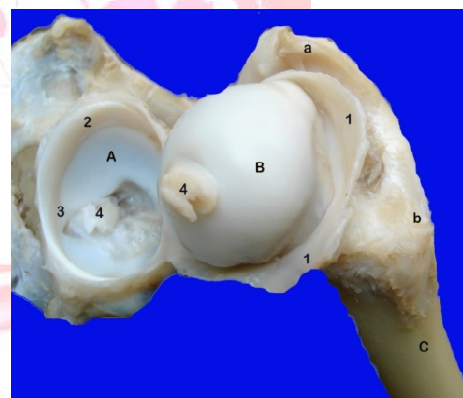
A total number of fifteen hip joints of buffalo calves were investigated irrespective of breed, sex and nutritional status. Out of those seven were procured from the local slaughter house and eight were from the hind limbs of the embalmed calves intended for routine dissection of veterinary undergraduate studies in the Department of Veterinary Anatomy. The investigations were done at Department of Veterinary Anatomy, College of Veterinary Science, Tirupati. The skin was removed and the biceps femoris, gluteus medius and gluteus profundus muscles were cut at their insertions and reflected proximad. The gross morphology of joints, various ligaments, articular surfaces, surrounding muscles were studied. The nomenclature used here was that recommended by the *Nomina Anatomica Veterinaria* [7].

## RESULTS AND DISCUSSION

The articulatio coxae was a spheroidal joint formed by the caput ossis femoris and the fascies lunata of acetabulum. The acetabulum consisted of an articular part, the facies lunata and a nonarticular part, the acetabular fossa. Roberts [1] described the shallow acetabulum as a factor in the luxation of the coxofemoral articulation in bovines. The articular surface was semilunar in shape. The acetabular margin was notched. A deep notch, the acetabular notch, was located caudomedially at the junction of acetabular angle of pubis with ischium. The acetabular notch was continuous cranially with the acetabular fossa and caudally with subpelvic

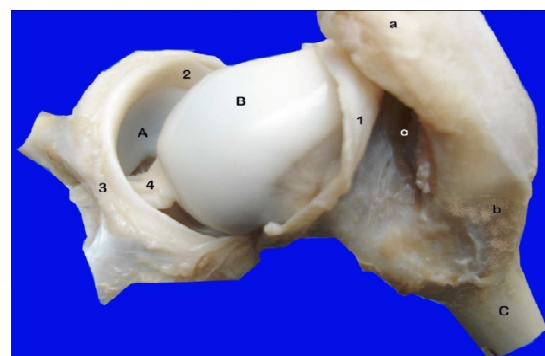
groove. The acetabulum was deepened by cotyloid ligament formed by a fibrocartilage. cotyloid ligament was loosely attached to the margin of the acetabulum and varied in width and thickness surrounding the rim. The greatest width occurred dorsolaterally. Part of cotyloid ligament formed transverse acetabular ligament over the acetabular notch (figs.1, 2). The head of the femur was nearly hemispherical in shape. It consisted mainly of a smooth convex articular surface and a nonarticular fossa, the fovea capitis, to which the round ligament was attached. The articular surface extended on the dorsal part of the neck. This arrangement gave the dorsal part of the head and neck a slightly saddle shaped articular surface. The large neck - shaft angle of the femur (130°) and ventrolateral location of the hips gave the space for flexion of the joint during forward motility.

**Fig. 1:** Photograph showing articular surfaces and ligaments of articulatio coxae.



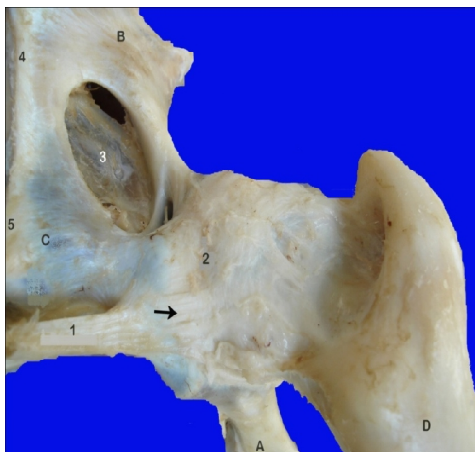
A. Acetabulum, B. Caput ossis femoris, C. Os femoris, a. Trochanter major, b. Trochanter minor, c. Fossa acetabuli, 1. Capsula articularis, 2. Labrum acetabulare, 3. transverse acetabular ligament, 4. Round ligament of hip.

**Fig. 2:** Photograph showing articular surfaces and ligaments of articulatio coxae.



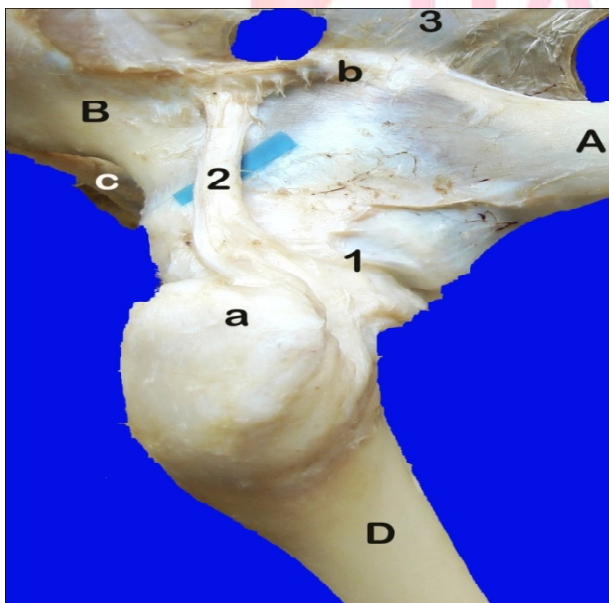
A. Acetabulum, B. Caput ossis femoris, C. Os femoris, a. Trochanter major, b. Trochanter minor, c. trochanteric fossa, 1. Capsula articularis, 2. Labrum acetabulare, 3. Lig. transversum acetabuli, 4. Lig. capitis ossis femoris.

**Fig. 3:** Photograph showing reinforcing fibers from Ligamentum pubicum craniale to capsula articularis of articulatio coxae (arrow).



A. Os ilium, B. Os ischii, C. Os pubis, D. Os femoris, 1. Lig. pubicum craniale, 2. Capsula articularis, 3. Membrana obturatoria, 4. Symphysis ischiadica, 5. Symphysis pubica.

**Fig. 4:** Photograph showing Iliofemoral ligament.



A. Os ilium, B. Os ischii, C. Os pubis, D. Os femoris, a. Trochanter major, b. Spina ischiadica, 1. Capsula articularis 2. Iliofemoral ligament, 3. Lig. sacrotuberale latum.

The capsula articularis was extensive and attached to the acetabular margin and the neck of the femur (fig.2). In the acetabular region the synovial membrane reflected over most of the outer surface of the cotyloid ligament and ended at the margin of the articular cartilage as reported by Jonadhan[4] in ox.

Gray [6] described a well developed zona orbicularis in man. This was not described in bovine, dog and horse by McLeod [8], Miller [3] and Sisson [2] respectively. In the present study few arched and semi-circular fibres were seen in the articular capsule but zona orbicularis was not present in buffalo hip. Surrounding the capsula articularis three periarticular ligaments were present in humans [6]. Apparently they were less developed in buffalo which was a quadruped as compared to the human who were bipeds. The greater development of the periarticular ligaments in the biped was probably due to the greater comparative weight that this articulation must support as compared to the quadruped [9]. In buffalo hip only two periarticular ligaments were observed, the iliofemoral ligament and the pubofemoral ligament or the pubocapsular ligament. The pubocapsular ligament appeared as reinforcing fibers from the lig. pubicum craniale to the capsula articularis (fig.3). The best developed periarticular ligament in the buffalo was iliofemoral ligament. The iliofemoral ligament was a thick cord of connective tissue extended from a nodule, two centimeters below and behind the spina ischiadica and spreaded on the capsula articularis partly blended with it and finally attaching to the trochanter major and to the tendon of the deep gluteal muscle (fig.4). It was taught in extension and relaxed in flexion keeping the hip from extreme extension and limiting adduction of the extended lower limb. The ischiofemoral ligament was absent in buffalo. The ischiofemoral ligament of the horse was poorly developed or absent. The ischiofemoral and pubofemoral ligaments were poorly developed and were absent in some dog specimens [4].

The ligamentum teres femoris was a flattened band of collagenous tissue extended from the lips of acetabular notch, fossa acetabuli, and to some extent from the subpelvic groove to the fovea capitis of the femur. It was covered by the synovial membrane of capsula articularis as reported by Nickel et al. [10] and Konig et al. [11] (figs.1, 2). The origin from the subpelvic groove

caudal to the acetabular notch was extraarticular and the remaining two were intraarticular. This ligament was strong compared to cattle. The round ligament of hip was reported to be small or absent in ruminants [12]. McLeod [8] stated that the round ligament of hip has a variable diameter to a maximum of three-eighths of an inch and it may be absent in bovines. The stabilizing role of the round ligament was questionable and it acted as a secondary contributor to hip stability.

The muscles over hip joint can be divided as superficial layer and deep layer. The muscles which comprised the superficial layer in the buffalo were dorsocranially the gluteus medius muscle, dorsally the vertebral head of the biceps femoris muscle, caudolaterally the biceps femoris and the semitendinosus muscles, caudomedially the semimembranosus and adductor muscles, craniomedially the sartorius muscle and craniolaterally the tensor fascia lata muscle. The muscles which comprised the deep layer in the buffalo were dorsolaterally the deep gluteal muscle, caudolaterally the gemellus, quadratus femoris muscles and the common tendon of insertion of the obturator internus and externus muscles, caudomedially the obturator externus and the adductor muscles, craniomedially the pectineus and the iliopsoas muscles and cranially the tendon of origin of the rectus femoris muscle. The origin of the vastus muscles of the quadriceps femoris muscle in ox came in contact with the cranial half of the femoral attachment of the joint capsule [4]. Roberts stated that the weak muscles in the gluteal region in the ox were a factor in luxation of the coxofemoral articulation [1].

The arterial supply for the coxofemoral articulation was from the deep femoral, the caudal gluteal and the cranial gluteal arteries as was reported by Howlett [13] and Jonadhan [4] in ox. The nerve supply was from articular branches from the cranial gluteal, sciatic, femoral and obturator nerves in buffalo.

The movements permitted by art. coxae were flexion and extension. Further, the presence of the strong intraarticular round ligament and due to the muscles of the thigh abduction was limited. Excessive adduction was prevented by iliofemoral ligament. circumduction and rotation

were observed to a limited extent due to saddle like articular surface of the femoral head. The presence of side way movement in ruminants better than solipeds was due to absence of the lig. accessorius ossis femoris [14].

## CONCLUSION

The art. coxae was a spheroidal joint formed by the caput ossis femoris and the fascies lunata of acetabulum. The acetabulum was hemispherical in shape and that of the femoral head was saddle shaped. The loose attachment of the cotyloid ligament and the shallow osseous acetabulum in the buffalo were anatomical factors which made the coxofemoral articulation more vulnerable to luxation. zona orbicularis was absent. The best developed periarticular ligament in the buffalo hip was the iliofemoral ligament which was helpful preventing over extension and adduction. The pubocapsular ligament was blended with capsule. Compared to the most of other quadrupeds the periarticular ligaments were well developed in buffalo. The capsula articularis was surrounded by rectus femoris in front, the gemellus and obturator internus behind and obturator externus, common tendon of iliopsoas and psoas major muscles medially. The movements permitted by art. coxae were flexion and extension primarily and to a limited extent adduction, abduction, rotation and circumduction.

**Conflicts of Interests: None**

## REFERENCES

- [1]. Roberts S J. Veterinary obstetrics and genital diseases: ann Arbor: Edward Brothers, Ithaca, Newyork; 1956.
- [2]. Sisson S. The Anatomy of the Domestic Animals: Volume1. Edited by Getty R. W. B. Saunders Company, Philadelphia, London; 1975: 349 and 787.
- [3]. Howard E. Evans, Alexander de Lahunta: Miller's Anatomy of the Dog: 4<sup>th</sup> edition. Saunders publication, Philadelphia, London; 2013:176-177.
- [4]. Kansas state university of agriculture and applied science, Department of Anatomy, Jonathan David Friend. Thesis on the Comparative Anatomy of the coxofemoral articulation of the Dog, Ox and Horse; 1959.
- [5]. Raghavan D. Anatomy of the Ox. Indian Council of Agricultural Research, New Delhi; 1964: 179-181.
- [6]. Grey, H. (1918). Anatomy of the Human Body. III. Syndesmology. Available at [http://www.bartleby.com/107/92.html].

- [7]. Nomina Anatomica Veterinaria. International Committee on Veterinary Gross Anatomical Nomenclature. 5<sup>th</sup> edition. Published by Editorial Committee Hannover, Columbia, Gent, Sapporo: 2005.
- [8]. McLeod WM. Bovine Anatomy. 2nd Edition, Burgess publishing company, Minneapolis, Minnesota; 1958: 164.
- [9]. Damien P. Byrne, Kevin J. Mulhall and Joseph F. Baker. Anatomy and Biomechanics of the Hip. The Open Sports Medicine Journal. 2010; 4:51-57.
- [10]. Nickel R, Schummer A, Seiferle E, Wilkens H, Wille KH and Frewin J. The locomotor system of Domestic Mammals. In The Anatomy of the Domestic Animals: Volume 1. Verlag Paul Parey, Berlin; 1986: 181-213.
- [11]. König H E, Liebich, H G and Maierl J. Text book and Color Atlas of Veterinary Anatomy of Domestic Mammals: Edited by H E König and H G Leibich. Schattauer Publisher, Stuttgart, New York; 2004: 148 and 218.
- [12]. Shivley M J. Text book of basic, comparative and Clinical Veterinary Anatomy: Texas and A M University press; 1987: 67-86 and 167-198.
- [13]. Howlett C R and Bryden M M. Anatomy of the arterial supply to the hip joint of the ox. J. Anat; 1971: 110, 3: 343-348.
- [14]. Chauveau, A. The Comparative Anatomy of the Domestic Animals. 2<sup>nd</sup> edition. Appleton Company, New York; 1891: 194-225.

### How to cite this article:

Supriya. B, T.S. Chandrasekhara Rao, P. Jagapathi Ramayya, R. V. Suresh Kumar. GROSS MORPHOLOGY OF THE HIP ARTICULATION OF BUFFALO CALVES (BUBALUS BUBALIS). *Int J Anat Res* 2014;2(4):645-649. DOI: 10.16965/ijar.2014.502