

## MORPHOLOGICAL VARIATIONS OF MUSCLE PLANTARIS: ANATOMICAL AND CLINICAL INSIGHT

Mohini M Joshi\*<sup>1</sup>, Subhash D Joshi <sup>2</sup>, Sharda S Joshi <sup>3</sup>.

\*<sup>1</sup> Associate Professor, Department of Anatomy, Rural Medical College, Pravara Institute of Medical Sciences, Loni, Dist.Ahmadnagar Maharashtra, India.

<sup>2</sup> Dean, Arbindo Institute of Medical Sciences, Indore, India.

<sup>3</sup> Professor and Head, Department of Anatomy, Arbindo Institute of Medical Sciences, Indore, India.

### ABSTRACT

**Background:** Plantaris is the largest muscle in mammals other than primates. Plantaris muscle has been a subject of much confusion and Evolutionists have speculated on its phylogenetic significance, as a vestigial organ, while surgeons have removed it 'useless vestige' to employ its tendon as a spare part for the surgical repair. In humans it is reduced greatly in size, power, and function and may even be absent.

**Aim:** With this background the aim of the present work is to study morphology, describe the observed variations of the Plantaris muscle, and to discuss the functional significance of Plantaris muscle.

**Methodology:** For the present work 84 limbs available in the department of Anatomy were dissected. The posterior aspect of the knee was dissected using standard surgical equipment and dissection techniques. The Plantaris muscle was isolated and length of fleshy belly and tendon were measured. Any variations in origin, insertion and size were recorded.

**Result:** Variation in insertion of the Plantaris has observed like insertion along medial margin of tendocalcaneus on to calcaneus, in front of tendocalcaneus on to calcaneus, fused to tendocalcaneus and insertion of the Plantaris on deep fascia of leg at the level of ankle. Other variations noted were two bellies of the Plantaris one from lateral supracondylar ridge and other from deep surface of Gastrocnemius, two heads of Plantaris: Both bellies were fused in the lower part producing bipennate arrangement, thin & thick belly of the Plantaris muscle. Variations also observed in relation to origin that the muscle is originating from deep surface of lateral head of Gastrocnemius & in other case origin from capsule. Bicipital Plantaris was seen where one head was originating from capsule of knee joint and other from lateral condyle.

**Conclusion:** In order to avoid any inadvertent injury during surgical operations, variation of the Plantaris must be borne in mind. Awareness of the insertion pattern of the Plantaris tendon is also important for clinicians in the diagnosis of muscle tears and for surgeons performing reconstructive procedures. Considering the above facts, the existence and importance of the Plantaris muscle cannot be undermined.

**KEYWORDS:** Plantaris muscle, Variations, Morphology.

**Address for Correspondence:** Dr. Mohini M. Joshi, Associate Professor, Department of Anatomy, Rural Medical College, Pravara Institute of Medical Sciences Loni, Dist. Ahmadnagar Maharashtra, India. Mobile No: +919762601050. **E-Mail:** atharvamohini@gmail.com

### Access this Article online

#### Quick Response code



DOI: 10.16965/ijar.2014.508

**Web site:** International Journal of Anatomy and Research  
ISSN 2321-4287  
www.ijmhr.org/ijar.htm

Received: 25 Sep 2014

Peer Review: 25 Sep 2014 Published (O):31 Oct 2014

Accepted: 15 Oct 2014 Published (P):31 Dec 2014

### INTRODUCTION

Plantaris muscle has long been a subject of much confusion and speculation, Evolutionists have speculated on its phylogenetic significance, as a vestigial organ, while surgeons have removed it 'useless vestige' to employ its tendon as a spare

part for the surgical repair, example tendon transfer operations and reconstruction and as a graft in reconstruction of ligaments etc [1]. The Plantaris muscle is considered to be a flexor group of muscle of the lower leg. The muscle originates from the lower part of the lateral

supracondylar line and the oblique popliteal ligament [2].

Plantaris is considered a rudimentary muscle. It is large muscle in mammals other than primates. In humans it is reduced greatly in size, power, and function and may even be absent. With this background the aim of the present work is to study morphology, describe the observed variations of the Plantaris muscle, and to discuss the functional significance of Plantaris muscle.

### MATERIALS AND METHODS

Present work has carried out on 84 limbs (Right 45; Left 39) available in the department of Anatomy, Rural Medical College, Pravara Institute of Medical Sciences, Loni.

**Material:** Dissecting instruments, thread, scale, divider, Digital camera (7.1M.P.) and Vernier caliper.

**Methods:** The posterior aspect of the knee was dissected using standard surgical equipment and dissection techniques. The Plantaris muscle was isolated and carefully traced to the proximal attachment, preserving any connections with surrounding tissue. Any variations in the muscle, its attachment, or relationship to surrounding tissues were noted and photographed using a digital camera. Whole length of muscle was dissected and displayed. Length of fleshy belly and tendon were measured. Any variations in origin, insertion and size were recorded. The variations observed on the dissected specimens were described in detail and then discussed in relation to their theorized functional and clinical importance.

### RESULTS AND TABLES

In this study, the Plantaris muscle is shown to have a highly variable anatomy.

**Table 1:** Length of fleshy belly.

Side	Length (cm)	Range (cm)
Right	8.39	3.5-13
Left	8.16	6-11.4

It is evident from table 1 that mean length of fleshy belly of the Plantaris muscle was 8.39 cm on right side and 8.16 cm on left side.

**Table 2:** Length of Tendon.

Side	Length (cm)	Range(cm)
Right	32.8	25-37.7
Left	33.7	24-40

It is evident from table 2 that mean length of tendon of the Plantaris muscle was 32.8 cm on right side and 33.7 cm on left side.

**Table 3:** Total length of Plantaris.

Side	Fleshy belly(cm)	Tendon(cm)	Total length (cm)
Right	8.39	32.8	41.2
Left	8.16	33.7	41.87

It is evident from table III that mean total length of the Plantaris muscle was 41.2 cm on right side and 41.87 cm on left side.

**Table 4:** Absence of Plantaris.

Side	No.	%
Right	3	6.66
Left	5	12.82

It is evident from table IV that Plantaris muscle was absent 6.66% on right side of the leg; while 12.82 % on left side.

**Table 5:** Insertion of Plantaris.

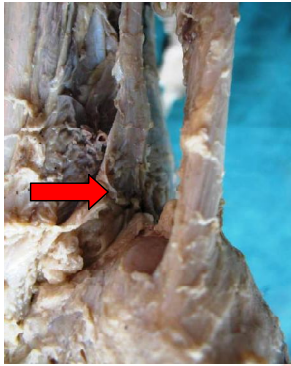
Sr. No.	Insertion of Plantaris	Right (%) limbs	Left (%) limbs
1	Along medial margin of tendocalcaneus on to calcaneus	21 (50)	13 (38.23)
2	In front of tendocalcaneus on to calcaneus	15 (35.71)	13 (38.23)
3	Fused to tendocalcaneus	4 (9.52)	4 (11.77)
4	Deep fascia of leg at the level of ankle	2 (4.77)	4 (11.77)

In present study variation in insertion of the Plantaris were observed like insertion along medial margin of tendocalcaneus on to calcaneus, in front of tendocalcaneus on to calcaneus, fused to tendocalcaneus and insertion of the Plantaris on deep fascia of leg at the level of ankle.

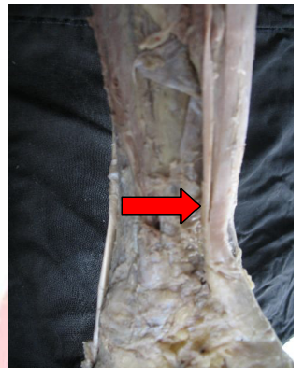
Other variations noted were two bellies of the Plantaris one from lateral supracondylar ridge and other from deep surface of Gastrocnemius, two heads of Plantaris: Both bellies were fused in the lower part producing bipennate arrangement, thin and thick belly of the Plantaris muscle. Variations were also observed in relation to origin that Plantaris muscle originating from deep surface of lateral head of Gastrocnemius

**Fig. 1:** Variations of Plantaris muscle.

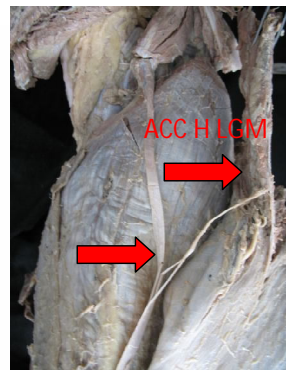
**a.** Insertion: Triangular expansion in front of tendocalcaneus on to the calcaneus.



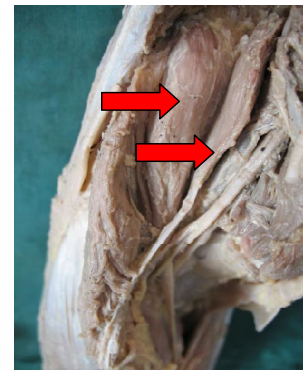
**b.** Insertion: Medial margin of tendo calcaneus on the calcaneus.



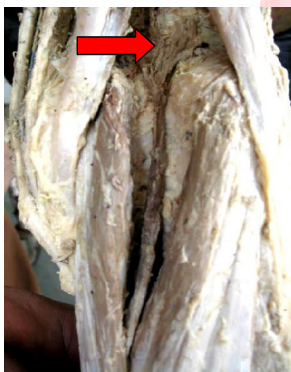**c.** Accessory lateral head of Gastrocnemius (ACC HEAD LGM) giving a slip to the tendon of Plantaris.



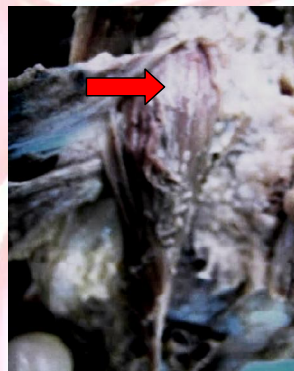
**d.** Two heads of Plantaris.



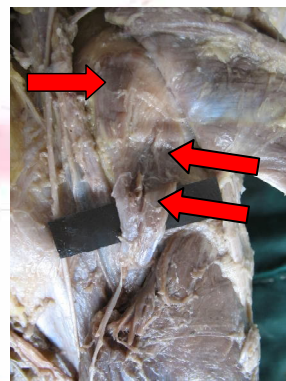
**e.** Plantaris: Origin from capsule of knee joint.



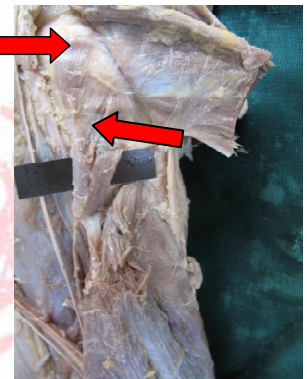
**f.** Plantaris: Originating from deep surface of lateral head of gastrocnemius.



**g.** Bicipital Plantaris: Origin: One head from capsule of knee joint & other from lateral condyle.



**h.** Bicipital Plantaris: Flattened aponeurosis merging with the soleus.



and in other case origin from capsule. Bicipital Plantaris was seen where one head was originating from capsule of knee joint & other from lateral condyle. (Fig. 1)

## DISCUSSION

In present study mean length of fleshy belly of the Plantaris muscle was 8.39 cm on right side and 8.16 cm on left side. Standing, (2005)[2] described the length of fleshy belly 7 to 10 cm. Das et al (2006)[3] found the average of the maximum length of fleshy belly of the Plantaris muscle 8.5 cm. In present study Plantaris muscle was absent 6.66% on right side of the leg; while 12.82 % on left side. Sinnatamby, 1999; Standing, 2005 reported an absence of the Plantaris muscle in approximately 10% of the population [2,4]. In lower extremities examined by Daseler (1943)[1], the Plantaris muscle was absent in 6.67 per cent. Simpson (1991)[5] found the absence of tendon in 9% of the population upon ultrasound study. Ward and Powers, (2004)[6] stated that the absence of the Planta-

-ris may cause weakness in initial flexion of the knee and an increased laxity of the knee during medial and lateral rotation, subsequently increasing the risk of injury to the primary stabilizing ligaments of the knee. In present study variation in insertion of the Plantaris were observed like insertion along medial margin of tendocalcaneus on to calcaneus, in front of tendocalcaneus on to calcaneus, fused to tendocalcaneus & insertion of the Plantaris on deep fascia of leg at the level of ankle. Similarly Das et al (2006) [3] observed that 60% the Plantaris muscle was inserted into the calcaneum, its normal site. In 40%, the insertion was into the superficial fascia of the leg. Cummins and Anson (1946) described that in 47% inserted on calcaneus, 35% in front of tendocalcaneus & 6% medial margin of tendocalcaneus. The absence of the Plantaris muscle may increase the risk of injury to ligaments of the knee. The surgical utilization of the Plantaris tendon is particularly indicated as

a desirable substitute for the fascia lata in hernial repair, tendon transplants, and repair of ligaments [1]. Shuhaiber (2003)[7] put forward a hypothesis, extrapolated from hand surgery, for use of the Plantaris tendon in heart valve repair. This proposal, if implemented, would increase the supply of autogenous donor tissue for valve repair. Pagenstert (2005) [8] described Anatomic procedure for reconstruction of the anterior talofibular and calcaneofibular ligaments with a free Plantaris tendon. Gelberman RH (1985) [9] reported that because of extremely tensile structure; tendon is used for flexor tendon replacement in hand surgery. In order to avoid any injury during surgical operations, the possibility of anomalous insertion of the Plantaris tendon into the superficial fascia of the leg must be borne in mind. The clinical importance of the Plantaris lays in the fact that the slender tendon may often be ruptured at the mid-calf level [10]. Torn Plantaris produces a condition of 'Tennis leg'. Moore (2006) reported Plantaris muscle as organ of proprioception as it contains a high density of muscle spindles. Menton (2000) [11] also observed that Plantaris acts as highly specialized sensory organs (kinesiological monitor) rather than motor organs. Voss H. (1971) [12] observed that combined weight of triceps surae was 824 grams and Plantaris 10.5 grams. (Ratio 78 to 1). Peck et al (1984) [13] observed that Plantaris have 3.7 muscle spindles per gram compared to 0.67 spindles per gram for triceps surae. (Ratio 5.5 to 1). Fuller understanding will not come from declaring it to be functionless, but rather from investigating its function. The evidence now suggests that it serves as organ of proprioception.

### CONCLUSION

In order to avoid any inadvertent injury during surgical operations, variation of the Plantaris must be borne in mind. Awareness of the insertion pattern of the Plantaris tendon is also important for clinicians in the diagnosis of muscle tears and for surgeons performing reconstructive procedures. Considering the above facts, the existence and importance of the Plantaris muscle cannot be undermined.

**Conflicts of Interests: None**

### REFERENCES

- [1]. Daseler EH, Anson BJ. The Plantaris muscle. J Bone Joint Surg. 1943;25:822-827.1
- [2]. Standring S Gray's Anatomy. The Anatomical Basis of Clinical Practice. 39th edition. Elsevier Churchill Livingstone, Philadelphia, 2005: 1499- 1500.
- [3]. Das S, Suri R, Kapur V. Anomalous Plantaris Tendon and its Clinical Implications (Anatomy).The N Iraqi J Med 2006;2(2):8-11.
- [4]. Sinnatamby C. Last's Anatomy. Regional and Applied. 10thEd. London: Churchill Livingstone. 1999: 141.
- [5]. Simpson, SL, Hertzog MS, Barja RH. The Plantaris tendon graft: an ultrasound study. J. Hand Surg. 1991;16:708-11.
- [6]. Ward SR, Powers CM. The influence of patella alta on patellofemoral joint stress during normal and fast walking. Clin Biomech (Bristol, Avon) 2004;19:1040-1047.
- [7]. Shuhaiber JH, Shuhaiber HH Plantaris tendon graft for atrioventricular valve repair. A novel hypothetical technique. Tex Heart Inst J 2003;30:42-44.
- [8]. Pagenstert GI, Valderrabano V and Hintermann B Lateral ankle ligament reconstruction with free plantaris tendon graft. Techniques in Foot & Ankle Surgery 2005;4:104-112.
- [9]. Gelberman RH, Vandeberg JS, Manske PR, Akeson WH. The early stages of flexor tendon healing: a morphologic study of the first fourteen days. J Hand Surg 1985; 10 (6 Pt 1):776-84.
- [10]. Leekam RN, Agur AM and Mckee NH Using sonography to diagnose injury of Plantaris muscles and tendons. AJR Am J Roentgenol 1999;172:185-189.
- [11]. Menton D The plantaris and the question of vestigial muscles in man CEN Technical Journal 2000;14(2) :50-53.
- [12]. Voss, H., Tabelle der absoluten und relativen Muskelspindelzahlen der menschlichen Skelettmuskulatur, Anat. Anz 1971;129:562-572.
- [13]. Peck, D., Buxton D.F. and Nitz, A., A comparison of spindle concentrations in large and small muscles acting in parallel combinations, J.Morphology 1984;180:243-252.

### How to cite this article:

Mohini M Joshi, Subhash D Joshi, Sharda S Joshi. MORPHOLOGICAL VARIATIONS OF MUSCLE PLANTARIS: ANATOMICAL AND CLINICAL INSIGHT. Int J Anat Res 2014;2(4):621-624.

**DOI:** 10.16965/ijar.2014.508