

ISSN XXXX-XXXX(Print)
e-ISSN XXXX-XXXX(Online)**Indian Journal of Clinical
and Experimental
Ophthalmology****IJCEO****PREDICTORS OF VISUAL RESPONSE TO INTRAVITREAL BEVACIZUMAB
FOR TREATMENT OF DIABETIC MACULAR EDEMA****Sunny Kumar Gupta^{1,*}, Ishan Yadav², Sujit Deshmukh³, Rajendra P Maurya⁴, V P Singh⁵**¹Resident, ²Senior Resident, ³Resident, ⁴Assistant Professor, ⁵Professor and Head, Department of ophthalmology, Institute Of Medical Sciences, BHU, Varanasi***Corresponding Author:**

E-mail: sunnymbbs2007@gmail.com

Abstract:**Objective:** To evaluate which factors influence maximum gain in best-corrected visual acuity after intravitreal injection of Bevacizumab as treatment for diffuse diabetic macular edema.**Methods:** This was a prospective, interventional trial including 112 eyes of 100 participants. Visual outcomes measured by change in visual acuity (VA) score, proportion gaining ≥ 15 letters, and change in central retinal thickness (CRT), presence of macular ischaemia, IS/OS integrity.**Results:** Mean change in the VA score was 9.2 ± 2.3 SD letters with a total of 79 eyes gaining ≥ 15 letters. Change in median CRT was $81.5 \mu\text{m}$. Younger age, higher baseline VA score, shorter duration of Diabetic Macular Edema (DME), absence of macular ischemia and an intact IS/OS junction were significantly associated with greater VA score improvement.**Conclusion:** Pronounced macular edema and intact IS/OS junction may have a positive impact, and marked macular ischemia and a high preoperative best-corrected visual acuity may have a negative impact, on an increase in best-corrected visual acuity after intravitreal Bevacizumab injection in patients with diabetic macular edema.**Key Words:** Bevacizumab, Diabetic macular edema, IS/OS junction, Macular ischaemia.**Introduction**

Intravitreal Bevacizumab has increasingly been used as a treatment for intraocular proliferative, edematous, and neovascular diseases, such as central retinal vein occlusion, neovascular glaucoma without or with cataract surgery, proliferative vitreoretinopathy, persistent pseudophakic cystoid macular edema, exudative age-related macular degeneration, proliferative diabetic retinopathy, retinal telangiectasia and in other clinical situations, such as sympathetic ophthalmia^{1,2,3}. Recently, intravitreal Bevacizumab also has been applied in eyes with diffuse diabetic macular edema, leading to an increase in visual acuity in some eyes⁴. It was, therefore, the purpose of the present study to evaluate which predictive factors are associated with an increase in visual acuity after an intravitreal injection of

Bevacizumab in patients with diabetic macular edema. The Pan-American Collaborative Retina Study Group (PACORES) trial also have shown the monthly injection of intravitreal bevacizumab in diabetic macular edema is safe and efficacious⁵. Most of the past studies have directly correlated decrease in CMT with improvement in VA^{1,6}. But there are other factors as well which directly or indirectly affect the ultimate improvement in VA post intravitreal bevacizumab injection. These factors includes presence or absence of macular ischemia, base line visual acuity, amount and duration of macular edema and morphologic type of macular edema as defined by OCT.

Materials & Methods

Study was conducted in the Department of Ophthalmology, IMS BHU,

Varanasi. This was a prospective clinical therapeutic trial including 112 eyes of 100 participants. Visual outcomes measured by change in visual acuity (VA) score, change in central macular thickness (CMT), presence of macular ischaemia on FFA and IS/OS integrity. Based on OCT and FFA findings Diabetic macular edema was classified into different morphological forms. Based on FFA, degree and extent of macular ischemia was also noted.

The degree of macular ischemia was graded as follows:

- 0**, indicates no ischemia;
- 1**, nonperfused area(s) outside of the temporal vessel arcade;
- 2**, one nonperfused area within the temporal vessel arcade but without contact to the foveal avascular zone;
- 3**, more than 1 nonperfused area within the temporal vessel arcade but without contact to the foveal avascular zone;
- 4**, nonperfused area with contact to the foveal avascular zone, with parts of the fovea perfused;
- 5**, whole fovea nonperfused, with the diameter of the nonperfused area smaller than or equal to 1 disc diameter;
- 6**, whole fovea nonperfused, with the diameter of the nonperfused area larger than 1 disc diameter.

Inclusion criteria were all patients with diabetic macular edema diagnosed by 78D slit lamp biomicroscopy, indirect ophthalmoscopy, OCT & FFA. Patients with clear ocular media so that OCT and FFA could be done. Exclusion criteria were patients who have previously undergone any intraocular procedure for treatment of diabetic macular edema like laser photocoagulation, vitrectomy etc. Patients previously treated with intravitreal injection other than Bevacizumab, like Triamcinolone and Ranibizumab. Patients with any other ocular disorders like uveitis, diagnosed glaucoma, retinal detachment, any diseases

leading to media opacities etc. Unwilling patients were also excluded from the study.

Procedure

All patients were prepped using povidone-iodine, sterile drape, and lid speculum as a part of pre-injection preparation. Conjunctival displacement with a cotton tip, dipped in povidone-iodine, was done prior to the injection. 0.05ml containing 1.25mg of bevacizumab was given as Intravitreal injection under aseptic precautions under topical anesthesia. All intravitreal injections were given with 30G sterile needles. After the intravitreal injection, the patients were usually re-examined the first day after injection, followed by re-examinations at about 1-month intervals. The mean \pm SD follow-up was 10.2 ± 7.6 months (median: 7.7 months; range: 1.0 - 32.6 months). The visual acuity was measured using Snellen charts. The BCVA was recorded on all occasions. Macular thickness and IS/OS junction integrity was also recorded on every occasion using spectral domain OCT. Two different outcome measures were analyzed: maximum gain in BCVA and change in BCVA after approximately 6 months. Predictive factors were tested using simple and multiple linear regression analysis.

Results

In a multiple linear regression analysis, maximum gain in BCVA after the intravitreal injection of Bevacizumab was significantly ($P < 0.001$) and negatively correlated with an increased degree of macular ischemia and a higher preoperative visual acuity. Improvement in BCVA was significantly and positively correlated with increased degree of macular edema at presentation ($P = 0.001$). Change in BCVA after the intravitreal Bevacizumab injection was statistically independent ($P = 0.15$) of age, sex and presence pseudophakia.[Figure 1]

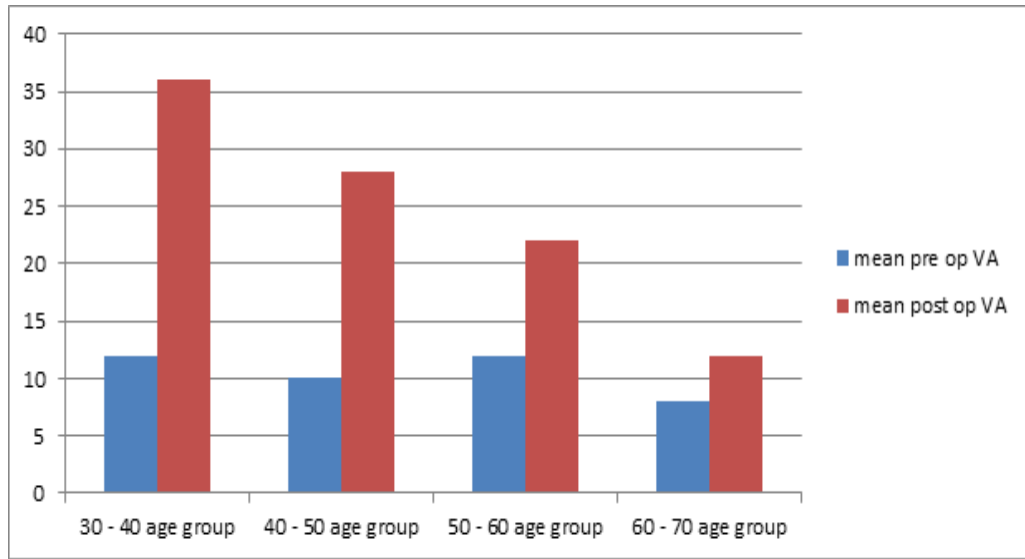


Figure 1: Changes in VA in various age groups

Mean visual acuity improved from 18 ± 3.86 to 28 ± 3.82 over 6 months of follow up period which was found to be statistically significant (p value < 0.001). In the same period the mean CMT (Central macular

thickness) decreased from 429 ± 31.1 to 347 ± 26.27 this difference was also found to be significant statistically. [Table 1]

Table 1

	Base line	6 months	P value
Visual acuity (Snellen letters)	18 ± 3.86	28 ± 3.82	< 0.0001
Mean central retinal thickness	429 ± 31.10	347 ± 26.27	< 0.0001

Figure 2 shows that macular ischaemia at baseline was significantly and

negatively associated with post injection BCVA.

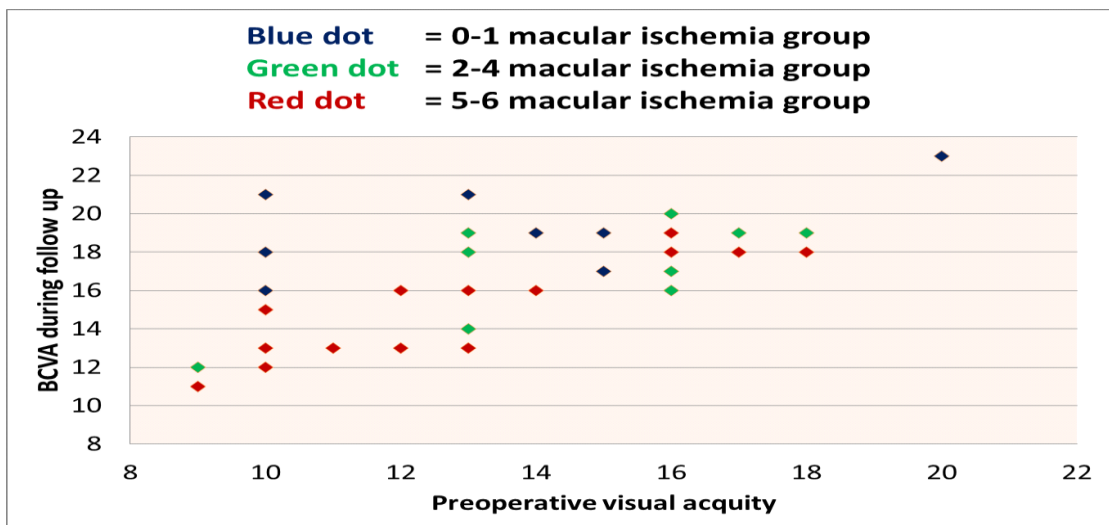


Figure 2

Figure 3 and 4 represents the changes in visual acuity and CMT over follow up period of 6 months respectively.

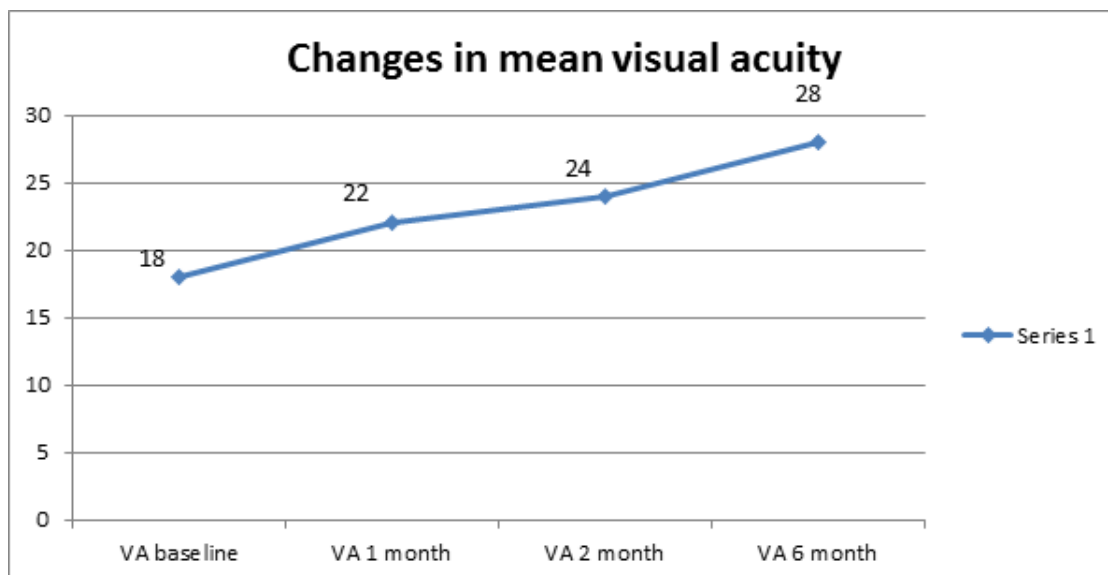


Figure 3

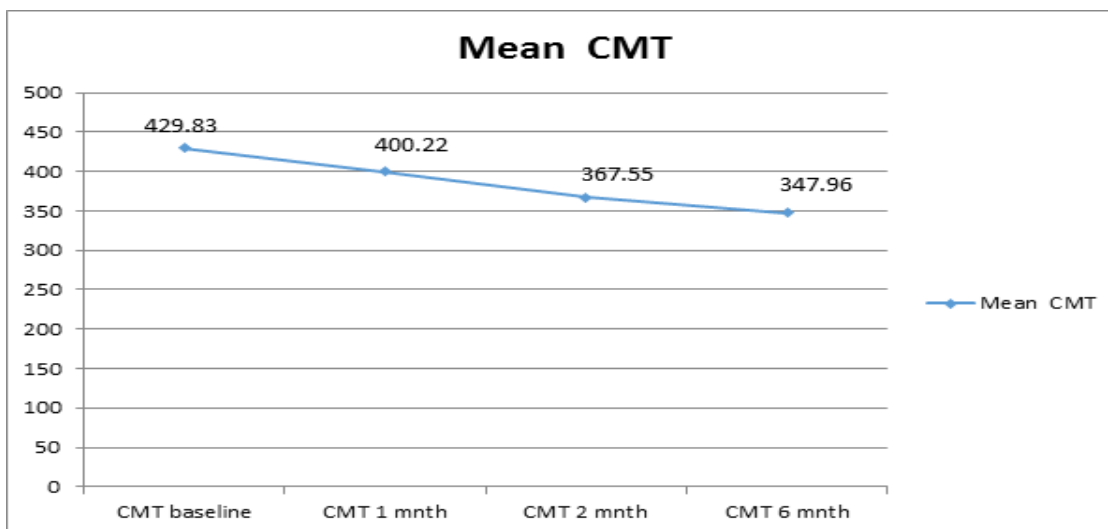


Figure 4

Discussion

Mean change in the VA score was 9.2 ± 2.3 SD letters with a total of 79 eyes gaining ≥ 15 letters. Change in mean CMT was $81.5 \mu\text{m}$. The results of the present study suggest that there are some factors that are associated with the change in BCVA after the intravitreal Bevacizumab injection. Eyes with a large ischemic area in the macula showed a less marked increase in BCVA after the intravitreal Bevacizumab injection than eyes with less marked macular ischemia. This corresponds to the clinical experience that intravitreal Bevacizumab might increase BCVA as much as macular ischemia will allow it⁷. Another predictive factor for the change in visual

acuity after the intravitreal injection of Bevacizumab may be the amount of macular edema⁸⁻¹⁰. The more pronounced macular edema was, the higher the increase in visual acuity after the injection, in univariate and multivariate statistical analyses. This reflects clinical observations that intravitreal Bevacizumab can lead to an almost complete restitutio ad integrum of the macula in an anatomical sense, with optical coherent tomographs showing a marked decrease in macula thickening with restoration of the foveal contour line after the intravitreal injection. Again, this agrees with clinical experiences that intravitreal Bevacizumab can increase visual acuity as much as macular ischemia, and not macular edema, allows it. An additional predictive factor for

change in BCVA after the intravitreal Bevacizumab injection was visual acuity at baseline^{10,11}. The lower the baseline visual acuity was, the more marked its increase was. Because eyes with a relatively high preoperative visual acuity also showed an increase in BCVA, the data of the present study do not allow the conclusion that the intravitreal injection of Bevacizumab should only be performed in eyes with a low visual acuity. Based on the results of the present investigation, and in agreement with previous reports and studies, one might infer that patients with persisting diffuse diabetic macular edema may undergo intravitreal injection of Bevacizumab¹²⁻¹⁴. Before the advent of anti VEGF agents past studies reported laser photocoagulation as the mainstay of treatment for diabetic macular edema¹⁵⁻¹⁸. But many studies have reported laser can induce significant collateral damage and may significantly affect the final visual outcome¹⁹⁻²¹. There are, however, limitations of the present study that have to be considered if generalized statements are drawn from the investigation. The most important limitation may be the design as a case series study. Because it was the purpose of the study, however, to search for factors that may influence the change in BCVA after the intravitreal injection of Bevacizumab, a comparative randomized study design with a study group and a control group might not have been absolutely necessary. Furthermore, the

primary outcome, best visual acuity during follow-up, is susceptible to statistical bias toward overoptimistic results. However, the preservation of the maximum level of visual acuity might be feasible if therapy is continued. Moreover, it was the aim of this study to establish predictive factors and not to prove efficacy of treatment with intravitreal Bevacizumab. Considering these arguments, we decided to analyze the best visual acuity during the whole follow-up and the visual acuity at 6 months after the injection. By using the second approach, 13 (25%) instead of 1 (2%) of 53 eyes showed a loss in visual acuity compared with the baseline value. Interestingly, predictive factors did not differ substantially between both approaches. Finally, the present study using 53 eyes had only moderate power. The analysis was explorative, and no formal correction for multiple testing was applied in simple or multiple regression analyses.

Conclusion

Younger age, Lower baseline VA score, Higher grade and shorter duration of Diabetic macular edema, absence of macular ischemia and an intact IS/OS junction were significantly associated with greater VA score improvement. Baseline VA, macular ischemia and IS/OS integrity were important predictors for visual response to bevacizumab at 6 months.

References:

1. Arevalo JF, Fromow-Guerra J, Quiroz-Mercado H, Sanchez JG, Wu L, Maia M, Berrocal MH, Solis-Vivanco A, Farah ME. Primary intravitreal bevacizumab (Avastin) for diabetic macular edema: results from the Pan-American Collaborative Retina Study Group at 6-month follow-up. *Ophthalmology* 2007; 114: 743-750 [PMID: 17398322 DOI: 10.1016/j.ophtha.2006.12.028]
2. Ahmadi H, Ramezani A, Shoeibi N, Bijanzadeh B, Tabatabaei A, Azarmina M, Soheilian M, Keshavarzi G, Mohebbi MR. Intravitreal bevacizumab with or without triamcinolone for refractory diabetic macular edema; a placebocontrolled, randomized clinical trial. *Graefes Arch Clin Exp Ophthalmol* 2008; 246: 483-489 [PMID: 17917738 DOI: 10.1007/s00417-007-0688-0]
3. Nagasawa T, Naito T, Matsushita S, Sato H, Katome T, Shiota H. Efficacy of intravitreal bevacizumab (Avastin) for short-term treatment of diabetic macular edema. *J Med Invest* 2009; 56: 111-115 [PMID: 19763022]
4. Scott IU, Edwards AR, Beck RW, Bressler NM, Chan CK, Elman MJ, Friedman SM, Greven CM, Maturi RK, Pieramici DJ, Shami M, Singerman LJ, Stockdale CR. A phase II randomized clinical trial of intravitreal bevacizumab for diabetic macular edema. *Ophthalmology* 2007; 114: 1860-1867 [PMID: 17698196 DOI: 10.1016/j.ophtha.2007.05.062]
5. Lihteh Wu, Maria A., Martinez-Castellanos, Hugo Quiroz-Mercado, J. Fernando Arevalo. Twelve-month safety of intravitreal injections of bevacizumab (Avastin®): results of the Pan-American Collaborative Retina Study Group (PACORES). *Graefes Arch Clin Exp Ophthalmol* (2008) 246:81-87 DOI 10.1007/s00417-007-0660-z
6. Yilmaz T, Cordero-Coma M, Gallagher MJ, Teasley LA. Systematic review of intravitreal bevacizumab injection for treatment of primary diabetic macular oedema. *Acta Ophthalmol* 2011; 89: 709-717 [PMID: 20645926 DOI: 10.1111/j.1755-3768.2010.01918.x]

7. Bonini-Filho M, Costa RA, Calucci D, Jorge R, Melo LA, Scott IU. Intravitreal bevacizumab for diabetic macular edema associated with severe capillary loss: one-year results of a pilot study. *Am J Ophthalmol* 2009; 147: 1022-1030, 1030. e1-5 [PMID: 19327746]
8. Wu PC, Lai CH, Chen CL, Kuo CN. Optical coherence tomographic patterns in diabetic macula edema can predict the effects of intravitreal bevacizumab injection as primary treatment. *J Ocul Pharmacol Ther* 2012; 28: 59-64 [PMID: 21992557 DOI: 10.1089/jop.2011.0070]
9. Roh MI, Kim JH, Kwon OW. Features of optical coherence tomography are predictive of visual outcomes after intra-vitreous bevacizumab injection for diabetic macular edema. *Ophthalmologica* 2010; 224: 374-380 [PMID: 20453545 DOI: 10.1159/000313820]
10. Bushra Mushtaq1, Niall J Crosby1, Antonios T Dimopoulos et al. Effect of initial retinal thickness on outcome of intravitreal bevacizumab therapy for diabetic macular edema. *Clinical Ophthalmology* 2014;8: 807-812.
11. Daien V1, Navarre S, Fesler P, Vergely L, Villain M, Schneider C. Eur J Ophthalmol. Visual acuity outcome and predictive factors after bevacizumab for central retinal vein occlusion. 2012 May 6;22(6):1013-1018. doi: 10.5301/ejo.5000162.
12. Soheilian M, Ramezani A, Yaseri M, Mirdehghan SA, Obudi A, Bijanzadeh B. Initial macular thickness and response to treatment in diabetic macular edema. *Retina*. 2011;31(8):1564-1573.
13. Haritoglou C, Kook D, Neubauer A, Wolf A, Priglinger S, Strauss R, Gandorfer A, Ulbig M, Kampik A. Intravitreal bevacizumab (Avastin) therapy for persistent diffuse diabetic macular edema. *Retina* 2006; 26: 999-1005 [PMID: 17151486 DOI: 10.1097/01.iae.0000247165.38655.bf]
14. Stefanini FR, Arevalo JF, Maia M. Bevacizumab for the management of diabetic macular edema. *World J Diabetes*. 2013;4(2):19-26
15. Early Treatment Diabetic Retinopathy Study Research Group. Photocoagulation for diabetic macular edema: Early Treatment Diabetic Retinopathy Study report number 1. *Arch Ophthalmol*. 1985;103:1796-1806.
16. Early Treatment Diabetic Retinopathy Study Research Group. Early photocoagulation for diabetic retinopathy: ETDRS report number 9. *Ophthalmology*. 1991; 98:766-785.
17. McDonald HR, Schatz H. Grid photocoagulation for diffuse macular edema. *Retina*. 1985;5:65-72.
18. Olk RJ. Modified grid argon (blue-green) laser photocoagulation for diffuse diabetic macular edema. *Ophthalmology*. 1986;93:938-950.
19. Lee CM, Olk RJ. Modified grid laser photocoagulation for diffuse diabetic macular edema: long-term visual results. *Ophthalmology*. 1991;98:1594-1602.
20. Bressler SB, Bressler NM. Randomized clinical trials in ophthalmology in 2001: twenty-fifth anniversary of the first publication from the Diabetic Retinopathy Study. *Am J Ophthalmol*. 2001;131:503-504.
21. Ladas ID, Theodosiadis GP. Long-term effectiveness of modified grid laser photocoagulation for diffuse diabetic macular edema. *Acta Ophthalmol (Copenh)*. 1993;71:393-397.