

ISSN XXXX-XXXX(Print)  
e-ISSN XXXX-XXXX(Online)**Indian Journal of Clinical  
and Experimental  
Ophthalmology****IJCEO****UNRECOGNIZED LARGE WOODEN INTRAORBITAL FOREIGN BODY****Ishan Yadav<sup>1,\*</sup>, Rajendra P. Maurya<sup>2</sup>, Prashant Bhushan<sup>3</sup>, Mahendra K. Singh<sup>4</sup>,  
Virendra P. Singh<sup>5</sup>, Prithvi R. Sen<sup>6</sup>**

<sup>1</sup>Senior Resident, <sup>2,3</sup>Assistant Professor, <sup>4,5</sup>Professor, Department of Ophthalmology,  
<sup>6</sup>Senior Medical Officer, Emergency Out Patient Department, Institute of Medical  
Sciences, Banaras Hindu University, Varanasi-221005 UP, India

**\*Corresponding Author:**  
E-mail: ishanu13@gmail.com

**Abstract:** *Intraorbital foreign bodies are relatively rare and are often associated with vision threatening complications. Their clinical presentation and treatment outcome is variable depending on the size and composition of the foreign body. Metallic and inert substances like glass and plastic are relatively well tolerated but organic foreign bodies like wood is poorly tolerated and may lead to severe inflammatory reaction and secondary infection needing prompt surgical intervention. Although identification and removal of wooden foreign bodies is very difficult, we report this case for its unusual presentation, where a large intraorbital wooden foreign body presented with a disfigured scar of right upper eye lid, two years after road traffic accident. The foreign body was removed successfully without any complications.*

**Keywords:** *Intraorbital foreign body, wooden foreign body.*

**Introduction**

Intraorbital foreign bodies are usually caused by high velocity injuries such as gunshot, blast injury or projectile objects<sup>1</sup>. They may result in severe structural and functional damage to ocular globe and adnexae<sup>2</sup>. Clinical manifestations, management and prognosis of intraocular foreign body depends on its size, location and composition of the traumatic agent<sup>3</sup>. Depending on composition of the agent, foreign bodies can be divided into metallic, such as steel and iron and non-metallic like plastic and glass and organic substances like wood<sup>4</sup>. It is very difficult to identify and localize small, impacted wooden intraorbital foreign body, even with gold standard imaging modalities like CT scan and MRI<sup>5</sup>.

Management and prognosis of wooden intraorbital foreign body is usually poor because it acts as nidus for orbital infection<sup>6</sup>. Wooden foreign bodies often break during removal<sup>7</sup>. We report an interesting case of unrecognised, retained

intraorbital foreign body without any complication.

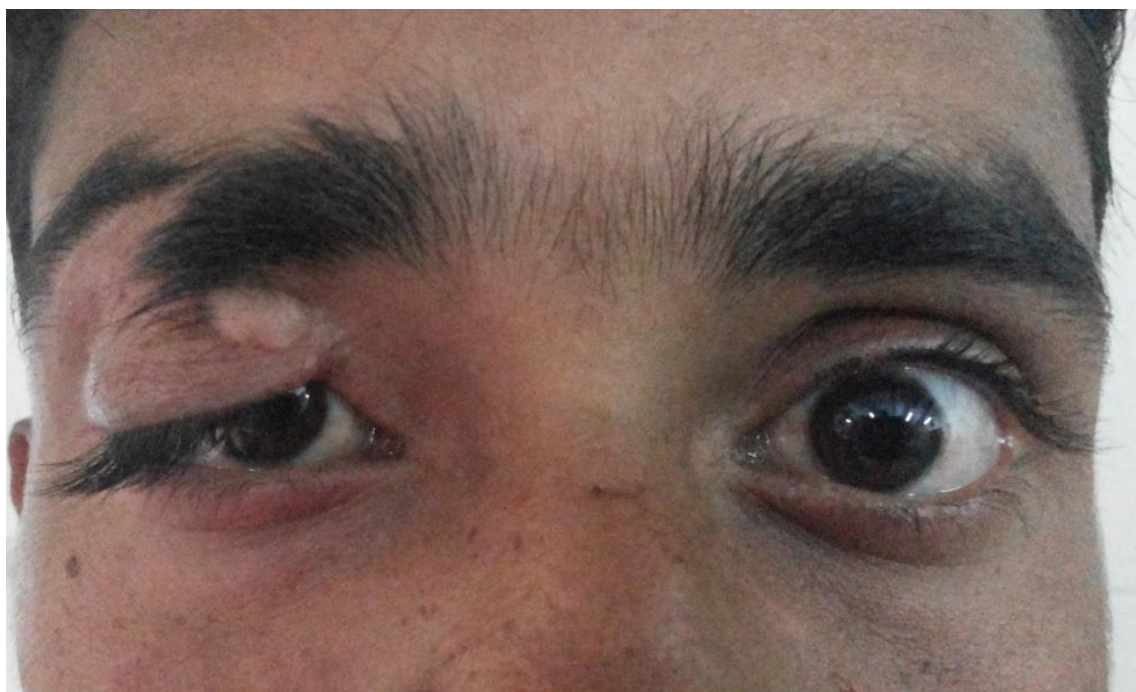**Case Report**

A 17 year old male who had history of road traffic accident, with fall towards right side of the face two years back, presented to our OPD with disfigured scar of right upper eye lid. After road traffic accident he was referred to a local practitioner who did only primary suturing without any imaging investigation. After few months of primary wound closure, patient complained of developing a cosmetically disfiguring scar and distorted right upper eye lid and brow. Thereafter, he remained asymptomatic and did not have any ocular complaint, but necessitated a visit to an ophthalmologist due to cosmetic factor.

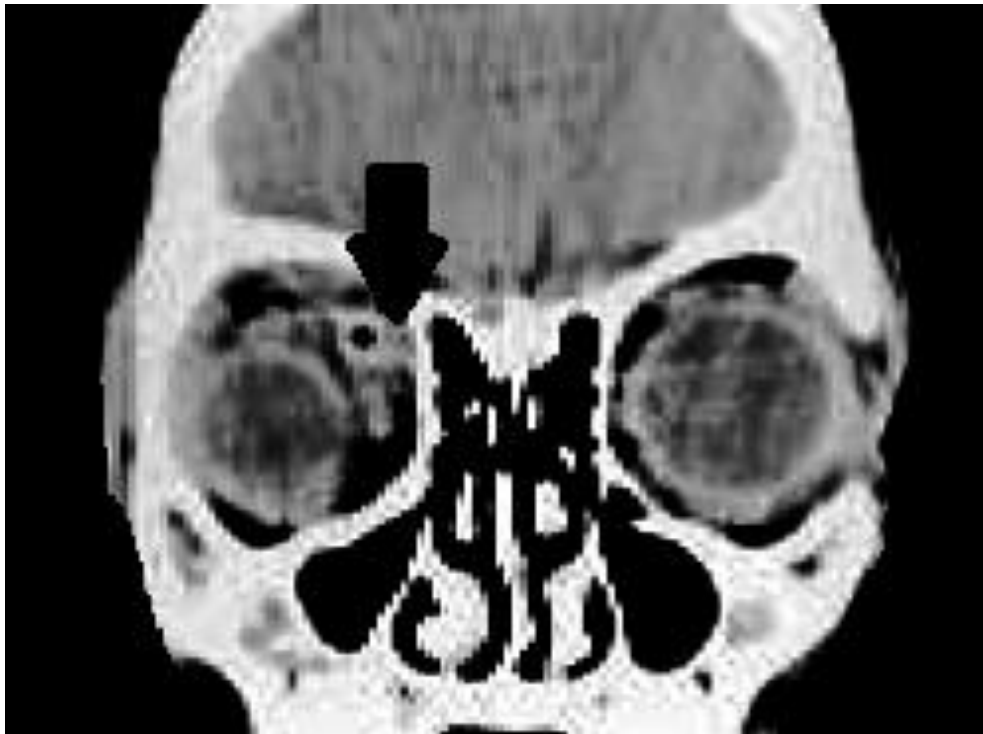
The patient had full ocular examination at our hospital for his cosmetic complaint of right eye. There was notching of lid margin, entropion of the medial one third of lid and hypertrophied keloid scar of 5 mm x 5 mm, just above the notched margin.

Right brow was disfigured and there was moderate traumatic ptosis [figure 1]. On palpation, a hard mass was felt just beneath the hypertrophied scar in the supranasal quadrant of right orbit. Digital X- ray and CT scan was advised to rule out any possibility of intra-orbital foreign body. X- Ray orbit did not reveal any radio-opaque foreign body but CT scan [coronal view] demonstrated a hypodense circular area [figure2] whose axial section corresponded with a hypodense subcutaneous tract of around 5 cms in length. There was no evidence of any intracranial extension of foreign body or any damage to the medial wall of right orbit. Extra -ocular movements were slightly restricted, superior-medially. Vision in right eye was 6/9, rest ocular examination was within normal limit. After clinical and radiological examination, a decision was

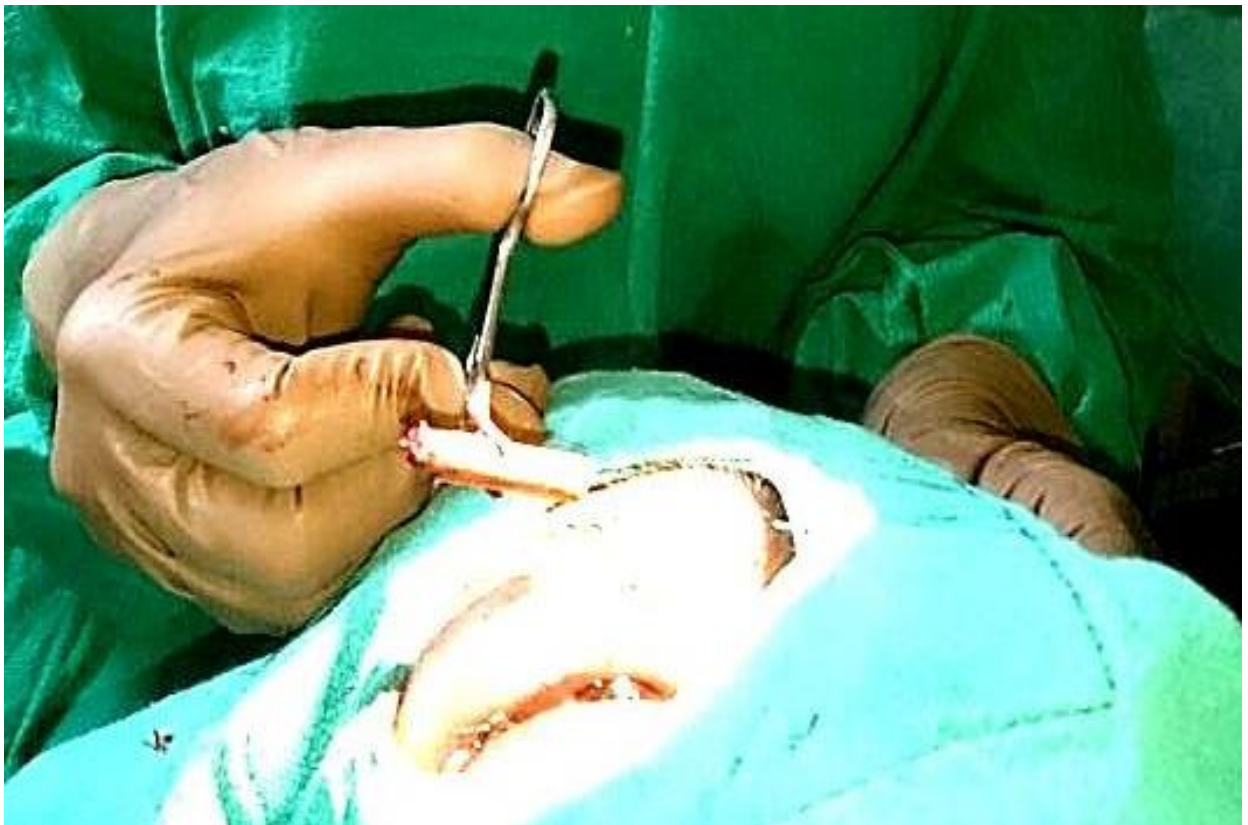taken to surgically explore the foreign body and to cosmetically improve the appearance. Intraoperatively, a full thickness vertical lid splitting incision was given, originating from the notched margin and incorporating the hypertrophied scar. After carrying out fine dissection in the superior - medial aspect of right orbit we were able to locate an impacted foreign body, which was carefully grasped by forceps and with gentle traction it was successfully removed. On examination, it was revealed to be a wooden foreign body measuring 5 cm in length. After removing the scar tissue, the wound was closed with 6-0 silk sutures. Postoperatively the patient received antibiotics for 7 days. There was no ocular restriction and post-operative visual acuity after one month was 6/9 in right eye. Ptosis correction was planned.



**Figure 1: Preoperative photograph showing right eye mechanical ptosis, hypertrophied scar with notching of upper lid with disfigured right eye brow.**



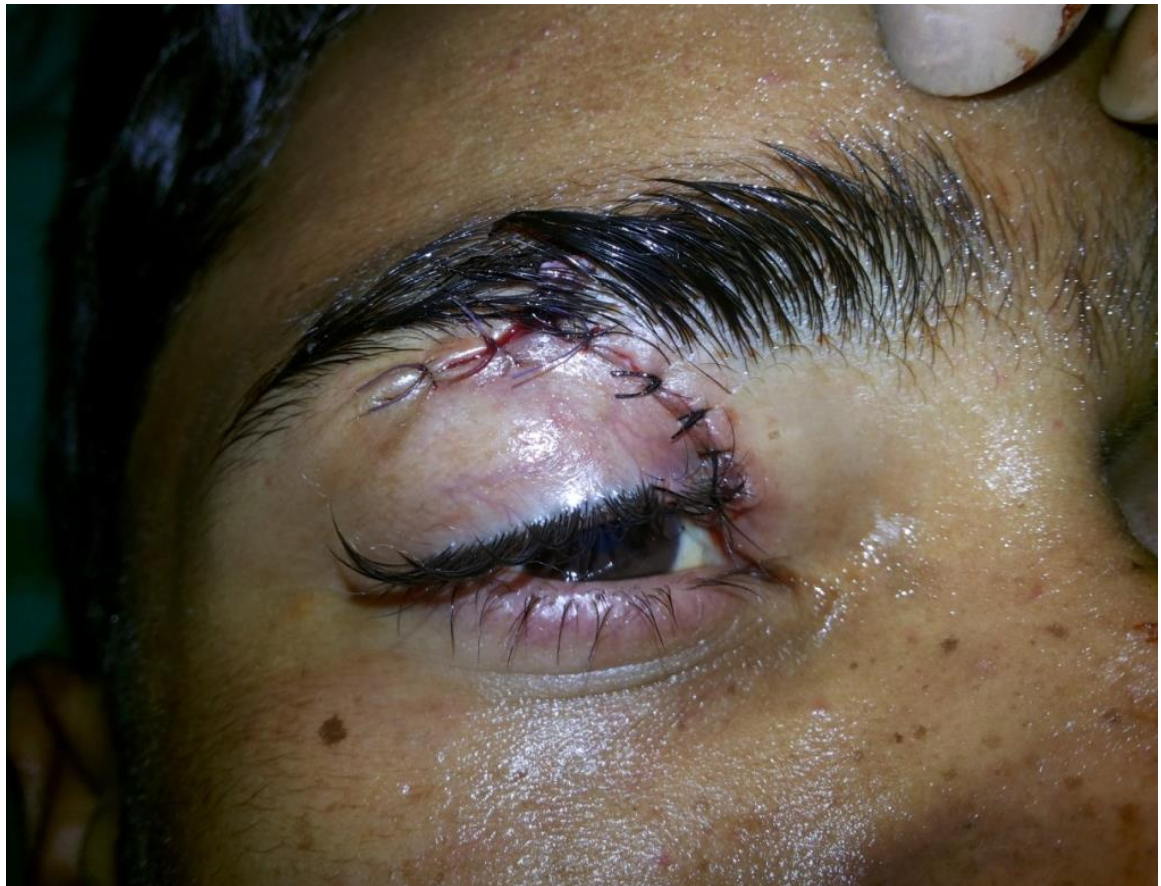**Figure 2: CT scan(coronal view) of Orbit showing hypodense shadow of foreign body in superonasal orbit.**



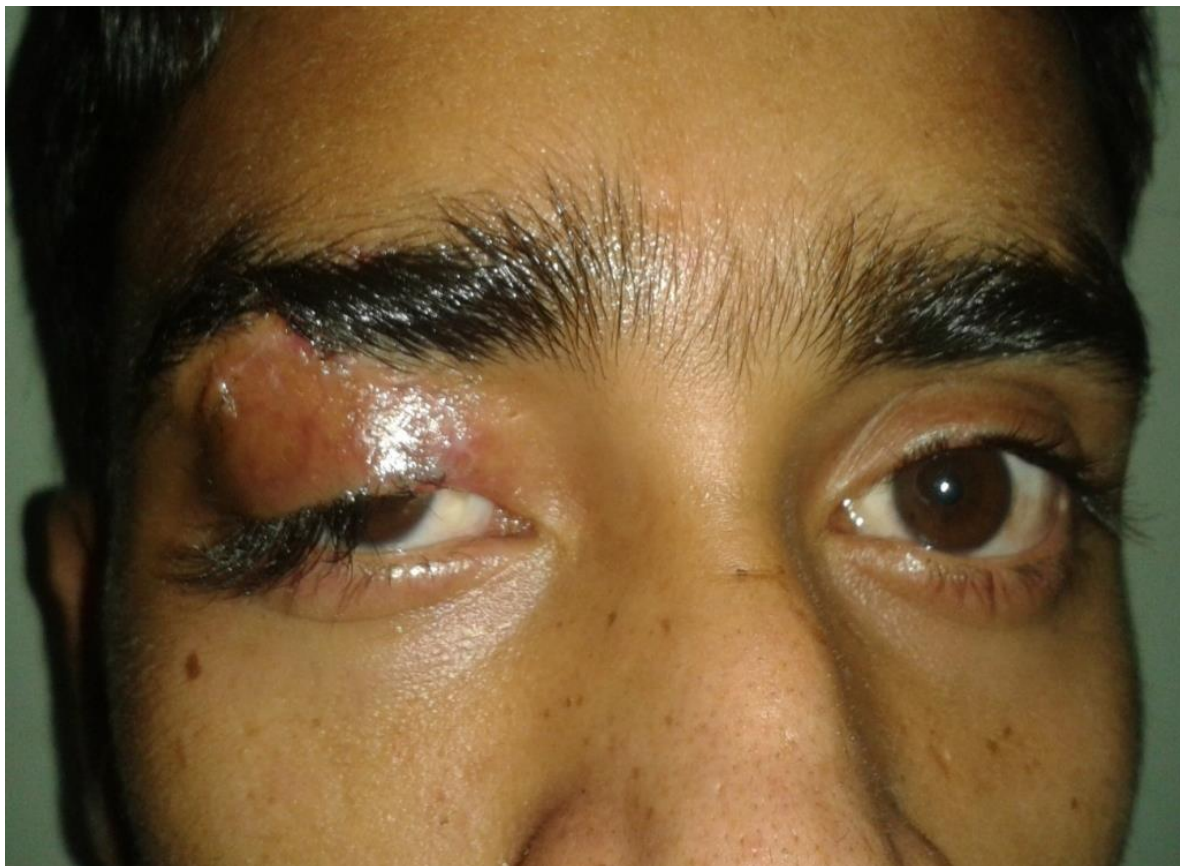**Figure 3: Surgically removed wooden foreign body.**



**Figure 4: Image of the extracted wood**



**Figure 5: Immediate post-operative photograph.**



**Figure 6: Two months postoperative face photograph**

### Discussion

Although orbital injuries with a retained foreign body are relatively rare in civilian life, they are usually caused by high velocity projectiles such as a gunshot or industrial accident/ road traffic accidents<sup>8</sup>. Penetrating orbital injuries with foreign body may result in severe complications, and may even be potentially fatal, since orbit provides access to the cranial cavity it can involve the meninges and central nervous system<sup>9</sup>. Complications usually depend on the type of injury and on the nature and location of foreign body. Orbitocranial injury and posteriorly located intraorbital foreign body have an increased risk of motility disturbance or traumatic neuropathy with trauma to ocular nerves<sup>10</sup>. Metallic and inorganic foreign bodies like glass and plastic are usually inert and thus well tolerated, if retained for longer durations. However, organic foreign bodies like wood are usually associated with severe inflammation and infection. The porous structure and organic nature of wood provides nidus and acts as an appropriate

culture media for growth of microbial agents<sup>11</sup>. Thus patients of wooden intraocular foreign body may present with complications like granuloma, orbital cellulitis, abscess or discharging sinus<sup>12</sup>.

We report this case of unnoticed intraorbital wooden foreign body without any ocular symptoms or complications one year after road traffic accidents. Identification or localization and removal of wooden intraorbital foreign body can often be technically challenging. Plain X ray is least important imaging technique for identifying wooden intraorbital foreign body as detection rate is low (0 to 15 %)<sup>13</sup>. CT is considered to be the gold standard to detect intraorbital foreign body but radio density of CT scan for wooden foreign body is variable and may be similar to that of orbital fat and muscle<sup>14</sup>. Wooden intraorbital foreign body shows negative Hounsfield unit due to air filled porous microstructures and water content. Hounsfield unit of wooden foreign body decreases over time. In acute stage, it mimics the orbital emphysema, and as water content dries up with increasing duration,

wood assumes moderate density and mimics orbital muscle and fat. CT scan of orbit may miss smaller wooden foreign bodies, although in such cases MRI can be advised, as it can distinguish between air and wood easily<sup>16</sup>. Previous literature reviews have suggested indications for removal of retained intraorbital foreign body, with various complications such as orbital granuloma, cellulitis and abscess. There was no such indication in our case. It was an accidental finding of retained intraorbital foreign body while patient was seeking cosmetic correction.

### References:

1. Cho RI, Kahana A, Patel B, Callcott JS, Buerger DE, Durairaj VD et al. Intraoperative fluoroscopy guided removal of orbital foreign bodies. *Ophthalmoplastreconstrsurg*2009; 25(3): 215 – 218.
2. Moretti A, Melissa L, Domenico C and Croce A. Periorbital foreign body: a case report. *Journal of medical case reports*. 2012; 6: 91.
3. Santos TDS, Melo AR, Moraes HHA, Junior PA, Dourado ED. Impacted foreign bodies in orbital region: review of nine cases. *Arq Bras optalmol* 2010; 73(5): 438-42.
4. Chatterjee SW, Bhattacharya A, Bhaduri G. Retained Intra –orbital foreign bodies: A short case series. *Indian J. Basic and Applied Med Res*. 2014; 3(2) 477- 480.
5. John S, Rehman TA, John D, Raju RS. Missed diagnosis of a wooden intra – orbital foreign body. *Indian J. Ophtalm* 2008; 56:322-4.
6. Owji N, Razeghinejad MR, Nowroozadeh MH. A missed intraorbital wooden foreign body presented as soft tissue mass. *Iranian J ophthal* 2011; 23(2): 66-68.
7. Banerjee A, Das A, Agarwal PK, Banerjee AR. Late spontaneous extrusion of a wooden intraorbital foreign body. *Indian J. ophthal* 2003; 51(1) : 83-4.
8. Moretti A, Laus M, crescenzi D and Croce A. periorbital foreign body: A case report. *Journal of Medical case reports* 2012; 6:91.
9. Nasr AM, Haik BE, Fleming JC, Al-Hussain HM, Karcioğlu. Penetrating orbital injury with organic foreign bodies. *Ophthalmology* 1999; 106(3): 523-32.
10. Singh A, Bhasker SK, Singh BK. Transorbital penetrating brain injury with a large foreign body. *J ophvis Res* 2013; 8(1) 62-63.
11. Potapov AA, Eropkin SV, Kornienko VN, Arutyunaw NV, Yelochiyani SA, Serova NK et al. Late diagnosis and removal of a large wooden foreignbody in cranio-orbital region. *J Craniofac surg* 1996; 7:311-314.
12. Marcea JA. Diagnosis and management of a wooden orbital foreign body: case report. *Br J Ophthalmol*. 1979;63 :848-51.
13. Griffith SPE. The value of plain radiography in suspected intraocular foreign body. *Eye* 1991; 5(6) 751-4.
14. Wilson WB, Dreisbol JN, Lattin DE, Stears JC. Magnetic resonance imaging of non-metallic orbital foreign bodies. *Am J. Ophthalmol*. 1998; 105(6); 612-7.
15. Boncoeur – martel MP, Adenis JP, Rulif JY et al. CT appearances of chronically retained wooden intraorbital foreign bodies. *Neurology* 2001; 43(2). 165-8.
16. Specht CS, Varga JH, Jalali MM, Edelstien JP. Orbitocranial wooden foreign body diagnosed by MRI. *Survey of Ophthalmology* 1992; 36(5): 341-4.

### Conclusion

The possibility of retained intraocular foreign body should be highly suspected in any road traffic accident case causing orbital injuries even in cases of no ocular signs and symptoms. Appropriate imaging modalities should be used for evaluation of orbital injuries and foreign bodies. The wooden intraorbital foreign body should be removed surgically, if present.