

Principles of echocardiography for the anesthesiologist.

Nikolaos Skubas, MD PhD

Abstract

Ultrasound-based diagnostic techniques are now part of the cardiological patients' chart, while echocardiography is used more often for intraoperative diagnostic as well, as monitoring practices by the anesthesiologist. This article will address the basic physical principles of the ultrasound waves and describe the interactions of ultrasound waves with tissues that lead to the generation of two-dimensional and Doppler ultrasound images

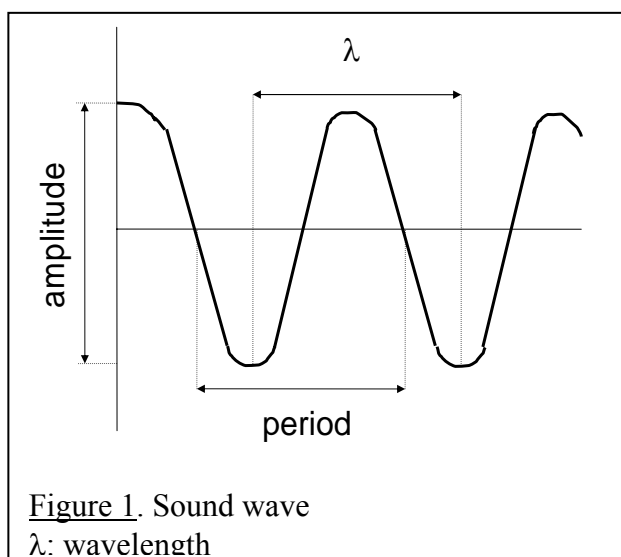
Sound waves and ultrasound: definitions

Any physical medium can vibrate and produce sound. The sound waves are nothing but tissue vibrations, and are comprised of alternate compressions (areas with tightly packed molecules) and rarefactions (areas where molecules are spaced apart). Sound is depicted as a sine wave with the peak representing the maximum and the nadir the minimum pressure. Vacuum cannot produce sound. Sound waves are described by: period, frequency, speed, amplitude, power, intensity and wavelength.

A single sound wave (one compression and one rarefaction) has a temporal (duration or **period**, sec) and a spatial (**wavelength**, λ , cm) dimension (figure 1). The number of sound waves in one second is termed **frequency** (**f**, Hz), and $\text{period} \times f = 1$. **Speed** (**c**, m/sec) of sound is the propagation velocity of the sound through the carrying medium (for biologic tissue, such as the human body, $c \approx 1540$ m/sec). Sounds of different frequencies travel at the same speed in the same medium, that is,

Assistant Professor, Assistant Attending, Director,
Intraoperative Echocardiography, Department of
Anesthesiology, Weill Medical College New York-
Presbyterian Hospital

it is the medium that determines the velocity of the sound. The sound velocity in a medium depends on the density and elasticity of that medium. The ability of tissue to transmit



sound is called **acoustic impedance** (**Z**) and is related to the density of the tissue (ρ): $Z = \rho \times c$. In general, as the density of a medium increases, the velocity of sound through the medium also increases (for example, sound travels faster through bone than liquids). Since $c = f \times \lambda$, frequency and wavelength are inversely related, so that as the frequency increases, the wavelength decreases. This relationship is important in echocardiographic imaging, as detailed imaging is produced by

smaller wavelength, while deeper penetration is accomplished by *larger* wavelength. **Amplitude** of a sound wave (the “strength”) is its peak pressure and is measured in dB, where $1 \text{ dB} = 20 \times \log$ (measured sound pressure / reference pressure, where reference pressure = $2 \times 10^{-4} \text{ dyn} \times \text{cm}^{-2}$). Accordingly, if the measured sound pressure is twice as strong as the reference pressure, its amplitude is 6 dB ($20 \times \log 2$), and if 100 times stronger its amplitude is 40 dB. **Power** (in Watts) is the rate of work performed by the sound wave. Power diminishes as the sound travels through the body. The power of the echocardiographic machine determines its ability to create a biologic effect. **Intensity** (or loudness) is the power of the sound wave in an area (W/cm^2).

Audible sound has frequencies between 20 and 20000 Hz, and sound with frequency higher than 20 kHz is termed ultrasound (US). Clinical ultrasound have frequencies ranging from 1 to 10 MHz, and because of the very short wavelength, clinical ultrasound is easily manipulated: steered, focused and directed to a specific target [1].

Interaction of ultrasound with tissue

The echocardiographic examination depends on, and is affected by the interaction of ultrasound waves with human tissue. These interactions are described by reflection, scattering, refraction and attenuation.

The basis of diagnostic ultrasound imaging is the **reflection** of the transmitted ultrasound signal by an interface between media of different acoustic impedances. If the interface separates two media with the same acoustic impedance, the ultrasound is not reflected, but continues to propagate (to be transmitted). When the interface separates media with different acoustic impedances, part of the ultrasound is reflected and the remaining is transmitted. The amount of reflected ultrasound energy is proportional to the difference in acoustic impedance of the two media (the greater the acoustic mismatch, the greater the amount of sound reflected). Optimal return (maximal reflection) occurs when the ultra-

sound wave strikes the interface perpendicularly (the angle of incidence is 90°). At any other angle of incidence, less energy is reflected back. The angle of reflection is equal to the angle of incidence. The strength of the recorded (reflected) echo is a function of both the acoustic mismatch at the interface and the angle of incidence. The mechanical aortic prosthesis or a calcified aortic valve create brighter echocardiographic images, than the native aortic valve, because they reflect more ultrasound. Furthermore, an aortic mechanical valve creates a “shadow” behind it, since very little ultrasound is transmitted distally. **Specular** echoes (reflections) are produced by fairly large (as related to the ultrasound wavelength) objects, which present a relatively smooth surface to the US beam. Small

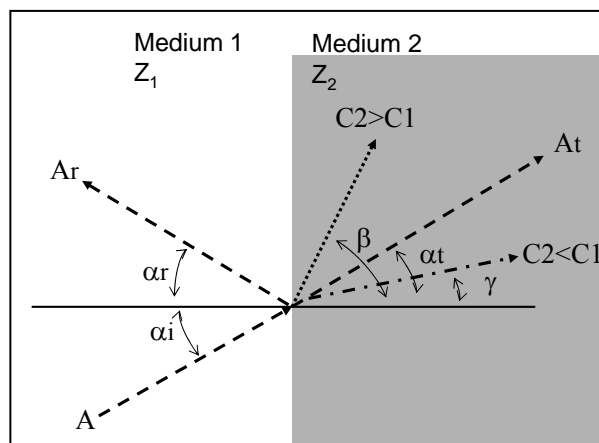


Figure 2. Interaction of ultrasound with tissue
A large and smooth interface that separates two media with the same acoustic impedance, will let an incident sound wave (A) travel unimpeded (At) through the second medium. However, if the media have different acoustic impedances ($Z_1 \neq Z_2$), the incident ultrasound wave (A) will be reflected (Ar) at an angle $\alpha_r = \alpha_i$. The portion of the ultrasound energy of the incident wave A that was not reflected will be transmitted through the second medium at an altered (refracted) direction. If the sound propagation velocity is faster in the second medium ($C_2 > C_1$), the refraction angle will be larger than the incident angle ($\beta > \alpha$). If $C_1 > C_2$, then $\gamma < \alpha$.

structures (less than one wavelength in width, or lateral dimension) or those with irregular surface will produce reflections that are less angle-dependent, propagate in all directions, and are less intense (**scattered** echoes). Although difficult to record (their amplitude is 40-60 dB less than the amplitude of a specular echo), scattered echoes are ever

present and are the basis of visualizing objects essentially parallel to the ultrasound beam, such as the lateral or the septal wall of the left ventricle in the mid-esophageal four-chamber view. The scattering of echoes from moving red blood cells is the basis of Doppler echocardiography.

Refraction is the deflection of the transmitted portion of the ultrasound wave, as it strikes, with an oblique angle of incidence, an interface separating media with different acoustic impedances (figure 2). Refraction cannot occur with a 90° incidence angle or when the propagation speeds are identical (the two media have the same acoustic impedance). The angle of the transmitted ultrasound is greater than the angle of incidence if the second medium has greater ultrasound propagation speed (**Snell's law**). Because the velocity of sound in human tissue is fairly constant, little refraction occurs while the ultrasound travels inside the body, and the beam path is considered to remain straight. The difference between refraction and reflection can be described by using a mirror as the interface surface: watching the approaching cars through a rear view mirror (refraction) versus one's face while shaving (reflection).

Attenuation of the ultrasound wave is the decrease in intensity, power and amplitude as the ultrasound wave travels through the body, and occurs due to 1) absorption and conversion of the ultrasound to heat, 2) scattering at the many small interfaces or elastic discontinuities encountered as the beam passes through even the most homogeneous medium. Attenuation results in a decrease in the amount of energy available to penetrate deeper into the body. The change in acoustic impedance contributes significantly to the ultrasound attenuation. That is why the ultrasound transducer is specifically designed, so that the ultrasound wave is not significantly attenuated before it leaves the transducer, and why a water-soluble gel is used to form an airless contact between the transducer and the skin during echocardiographic examination. Generally, the depth of

penetration for adequate imaging is limited to approximately $200 \times \lambda$, so that ultrasound with lower frequencies (larger wavelength) penetrates deeper. In transesophageal echocardiography (TEE), the distance that the ultrasound wave needs to travel is short, and higher frequencies are used to improve image quality, while in transthoracic echocardiography (TTE) visualization of structures that lie farther away necessitates the use of ultrasound with larger wavelengths. Attenuation is decreased at lower depths of examination and by using lower ultrasound frequency. The attenuation of ultrasound in tissue is approximately 1 dB/cm/MHz: the higher the frequency and the deeper the imaging, the more the attenuation [2].

Pulsed ultrasound and real-time scanning

A sound emitting device, such as an echocardiographic machine, that produces a *constant* sound wave is said to operate in a **continuous wave (CW)** mode, whereas if it transmits a series of identical pulses, each consisting of only a few cycles, is said to operate in a **pulsed wave (PW)** mode. Most imaging systems (either two-dimensional or Doppler echocardiography) operate in PW mode. **Pulse duration (PD)** is the time from the start to the end of that pulse, i.e., the actual time the pulse is "on" and is determined by the number of cycles and the period of each cycle. In clinical imaging, PD ranges from 0.5 – 3 μ sec and consists of 2 – 4 cycles. **Pulse repetition period (PRP)** is the time from the start of one pulse until the start of the next pulse, and includes both "on" and "off" time of the pulse. In clinical imaging, the PRP ranges from 100 μ sec – 1 msec. **Pulse repetition frequency (PRF)** is the number of pulses (resulting in lines of returning data) occurring in one second, and ranges from 1000 to 10000 Hz. PRP and PRF are reciprocals: $PRP \times PRF = 1$. When the imaging depth increases, the PRP lengthens (as the machine dedicates more time for "listening", since the pulse will travel farther, while the PD remains constant), and the PRF decreases [3,4].

In “real time” 2D imaging, ultrasound data is spatially oriented against time and images are created at a fixed rate. The amount of data collected in a certain period of time is limited by the speed of sound in tissue (more data information is collected when the imaged structures are closer to the transducer), and the information collected is determined by the number of images that can be displayed. The following variables are interdependent and describe the variables of real time imaging: depth of imaging, line (pulse) density, PRF, angle of sweep and sweep (frame) rate.

Table: Variables of real time imaging

| | | Imaging situation | | |
|----------|---|-------------------|---------------|---------------|
| | | A | B | C |
| Variable | | | | |
| 1 | Imaging depth (cm) | 10 | 15 | 20 |
| 2 | Total travel distance (cm) | 20 | 30 | 40 |
| 3 | ~PRP - time of flight for one US pulse [line] (msec) * | 0.13 | 0.20 | 0.26 |
| 4 | PRF (1÷PRP) (Hz) | 7692 | 5000 | 3846 |
| 5 | Sweep [frame] rate (sweeps/sec) | 60 | 45 | 30 |
| 6 | -time for each sweep (msec) | 17 (1÷60) | 22 (1÷45) | 33 (1÷30) |
| 7 | Lines [pulses] per sweep | 131 (17×0.13) | 110 (22×0.20) | 127 (33×0.26) |
| 8 | Angle of sweep [scan angle] (°) | 60 | 60 | 30 |
| 9 | Line density (lines [pulses] ÷ degree) | 2.18 | 1.8 | 4.2 |

[* in the total time of flight (PRP) one should add the time required for the transducer to be switched from the receiver to transducer mode – usually 0.02 to 0.01 msec. The PRF would be changed to 7142, 4545 and 3571 Hz, for depth of 10, 15 and 20 cm, respectively]

Real time scanning involves compromises and trade offs. Better imaging and resolution is accomplished by increased number of lines (pulses) per degree of sweep angle (variable 9, compare C vs A and B). If one begins with a fixed number of lines (pulses) of information, the same frame rate will be maintained by decreasing the depth of imagination (A5 vs B5). Decreasing the depth of imaging increases the line density (variable 9, A vs B) and maintains resolution with a faster frame rate (variable 5, A vs B). By decreasing the size of the picture (scan angle) [variable 8, C vs B] one can increase the density of lines per imaged field (variable 9, C vs B). To investigate deeper structures (variable 1, B vs A), one should decrease the sweep rate (variable 5, B vs A), in order to maintain line density (variable 9, B vs A). During clinical echocardiography, decreasing the depth of examination, and reducing the size of the scan sector are the cornerstones of a quality image.

Biologic effects

The biologic effects of a sound-emitting system depend on the total acoustic energy (power) produced by the system, the spatial distribution of the energy and the duration of exposure. Local heating (thermal effect) is directly associated to ultrasound intensity and most likely occurs close to skin surface (in trans-thoracic echocardiography) or esophageal mucosa (in transesophageal echocardiography). The perfusion of tissue by blood has a cooling effect and tends to offset the temperature increase. Cavitation is the formation of gas bubbles by vibration of dissolved O₂ or CO₂, but is not an issue in biologic systems, where the increased viscosity limits the motion of the bubbles significantly. The mechanical effects of ultrasound, radiation forces and radiation torques, probably do not occur in tissue. **Duty factor (D)** is the fraction of the time the transducer is operating (“on” time), and therefore is producing biologic effects, and is the ratio (%) of PD to PRP. Duty factors for diagnostic ultrasound sys-

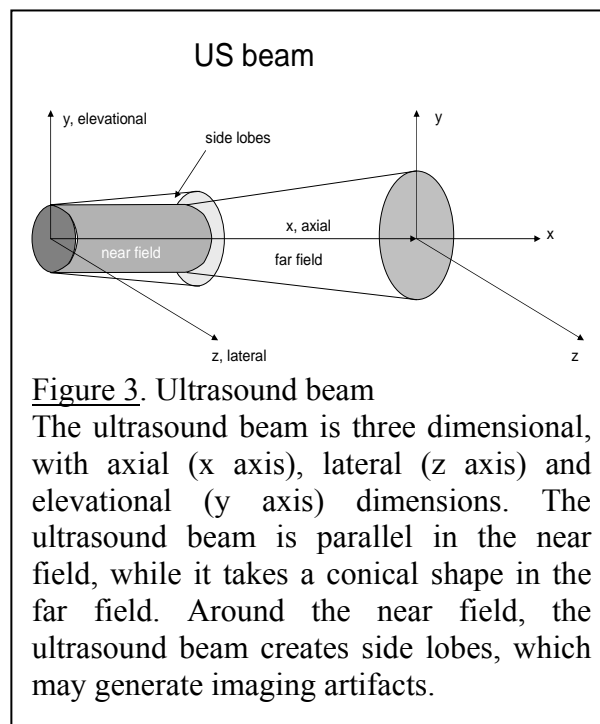
tems are very low, typically in the range of 0.0005 to 0.002 [5].

The ultrasound transducer and beam

Piezoelectric (pressure-electric) materials (PZ) change shape under the influence of an electric field. With the application of an alternating electric current, the PZ material alternately contracts and expands, generating compressions and rarefactions, or sound waves. Conversely, the mechanical stress produced by an ultrasound wave that strikes the PZ material, generates an electric signal. The strength of the electrical charge (voltage) is determined by the amount of stress applied to the PZ material, or the amount of returning acoustic energy (echo strength). If the speed of sound (c) in that particular medium is known, one can calculate the total distance traveled by the ultrasound wave (distance = $[c \times \text{time}] \div 2$), making possible the direct determination and appropriate display of the distance of the imaged structure from the transducer. Such a PZ element is the primary component of an ultrasound **transducer**, which generates, and transmits ultrasound into the heart, and receives the returning echoes. It comprises of the PZ element, electrodes which transmit the current required to shock-excite the it, and record the voltage produced by the returning echoes, backing (damping) material to control the vibration of the system, acoustic insulation, a case, matching layers, and a face plate to match the acoustic impedance of the esophagus (in the case of a TEE transducer) and to facilitate ideal sound transmission. The characteristic frequency of the transducer is determined by the thickness of the PZ element. Basically, the transducer emits a brief burst of ultrasound and then switches to the “receive” mode to wait for the reflected ultrasound signals from the intracardiac acoustic interfaces. The range of frequencies contained in the burst (pulse) of ultrasound is termed frequency bandwidth. This process is repeated temporally and spatially to generate ultrasound images. Each single small element-transducer generates US

waves that radiate, as would the ripples created by a pebble dropped into water [6].

The part of the ultrasound beam in close proximity to the transducer resembles a tube, and is called the **near field** (Fresnel zone), while the diverging, distal conical portion of the beam is called the **far field** (Frauenhofer zone). The junction of the near and far fields is the **transition zone**. The length of the near field is r^2/λ (r : radius of sound-generating surface) and a transducer can only be focused at a distance less or equal to the length of the near field. Narrower beams are preferable to broader beams, because they produce echoes from a more limited area of the heart, reducing ambiguity of the returning echoes, are more intense and thus generate stronger echoes, and have superior lateral resolution (see below). Although the majority of the sound energy produced by a simple disc-shaped transducer propagates directly away from the transducer face to form the **main beam**, at the lateral margins of the sound source a portion of the sound energy is transmitted radially, away from the main beam axis, creating the **side lobes** (figure 3).



The intensity of the side lobes decreases as one moves radially, away from the main beam. Side lobes are potential sources of artifact, because all echoes received by the

transducer are displayed as if they arose from targets along the central axis of the main beam. Strong reflectors illuminated by the side lobes, may be shifted on the display to a position that differs from their true location in space. The **focusing** the ultrasound beam, by mechanical or electronic methods, narrows the ultrasound beam, increases its intensity at the focal zone, and decreases the amount of divergence of the ultrasound in the far field. If multiple small elements are fired simultaneously, a linear wave front moving perpendicular from the linearly arranged elements is generated. An ultrasound transducer, comprised of multiple small elements fired individually in a controlled manner (in order to steer the US beam), is called a **phased array** transducer. By appropriate timing of the individual elements, the leading edges of the produced ultrasound waves produce a concentrically curved wave front, so that the resulting ultrasound beam focuses at a given point from the transducer. Formation of a tomographic cardiac ultrasound image is based on mechanical or electronic sweeping of the ultrasound beam across the plane of interest (sector scanning). The ultrasound beam produced by a phased array transducer is three-dimensional: it has axial (parallel to the direction of the ultrasound beam, also called "linear" or "longitudinal"), azimuthal (side to side, or lateral) and elevational (perpendicular) dimensions.(figure 3) If the phased array elements are circles instead of rectangles, both azimuthal and elevational dimensions of the produced ultrasound beam are reduced, and the axial resolution is increased. However, dispersion of the ultrasound beam laterally does occur, resulting in image or flow artifacts. Image **resolution** occurs for each of the three dimension of the ultrasound beam. **Axial resolution** (the ability to distinguish two structures that are close to each other, front to back, parallel to the ultrasound beam's main axis) is most precise, and quantitative measurements should be made using data derived from a perpendicular alignment between the ultrasound beam and the structure imaged, in two-dimensional and M-

mode echocardiography. The smallest resolvable distance between two specular reflectors with conventional ultrasound is 1λ , and therefore, better resolution is achieved by ultrasound beams with the smaller wavelength (or, the higher frequency). A wider bandwidth also improves resolution by allowing a shorter pulse, thus avoiding overlap between the reflected ultrasound signals from two adjacent reflectors. **Lateral resolution** (the ability to distinguish two structures that are close to each other, side to side, or perpendicular to the ultrasound beam's main axis) varies with the depth of the specular reflector from the transducer, approaching axial resolution in the focal region. The lateral resolution is approximated by the beam diameter. For this reason, parallel structures must be separated by more than the width of the ultrasound beam to be "resolved" as laterally distinct. At greater depths (far field), due to beam divergence, "blurring" of the image occurs. Also, a strong specular echo arising at the far field may be erroneously interpreted as a linear abnormal structure. Cardiac ultrasound images have a 3 - 10 mm thickness, resulting in artifacts of **elevational resolution** (linear echo from a calcified atheroma of the aortic wall may appear as a dissection flap) [7].

Increasing transducer frequency improves axial resolution as well as beam characteristics: the near field is elongated and the beam divergence in the far field is diminished. However, at the same time, attenuation increases, diminishing the ability of the US to penetrate to deeper cardiac structures. Penetration is of primary importance because resolution becomes irrelevant when the echo beam cannot reach the structures of interest.

The returning ultrasound energy strikes the PZ element, produces a transient vibrational stress, which is converted to oscillatory electrical signals (radio frequency signal). This is transformed to a video signal, which reflects both amplitude and duration. By differentiating this signal, the echo intensity is increased without significantly changing the

distance between echoes, thereby making measurements more reproducible.

Display formats

Standard ultrasound imaging is based on reflection of the fundamental transmitted frequency from tissue interfaces. The returning echoes generate electrical signals, with amplitude proportional to incident angle and acoustic impedance, and timing proportional to distance from the transducer. The signal undergoes complex manipulation (signal amplification, time-gain compensation, filtering, compression, rectification) to form the final image displayed in “real time” on the monitor. The basic formats display echocardiographic data along a line that represents the beam axis. In the **A-mode** format, the amplitude of the recorded echoes is depicted as horizontal deflections (spikes) along a vertical line that represents the depth from where they originate. In the **B-mode**

format, the returning echoes are depicted with brightness, indicating the intensity of the reflectors. The **2D** (two dimensional) format is a modification of the B-mode: the cross-sectional image is assembled by electronically sweeping the ultrasound beam from one area of the heart to another through a fixed plane, while continuously transmitting sound pulses and recording the resulting echoes. In the **M-mode** format (time-motion display), sequential B-mode lines are depicted across the face of the monitor, providing axial information concerning structure and depth, with the time dimension shown on the horizontal axis [8,9]. The high sampling rate of the M-mode display is valuable for assessing the absolute and relative motion of cardiac structures because it has the highest temporal resolution of any available ultrasound imaging modality. Accurate evaluation of rapid intracardiac motion such as, opening and closing of a valve, the high frequency fluttering of the anterior mitral valve leaflet in aortic insufficiency, the oscillations of valvular

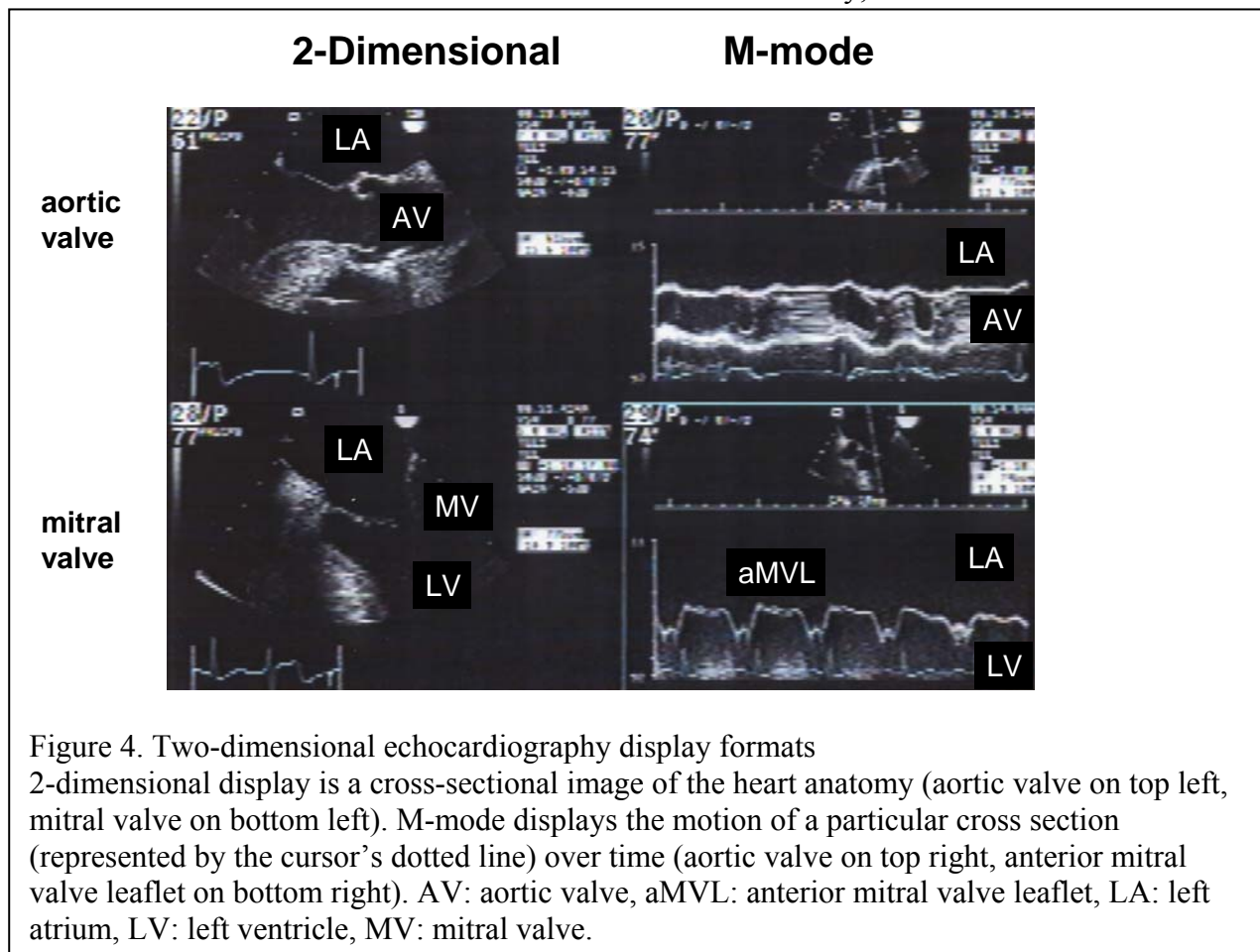


Figure 4. Two-dimensional echocardiography display formats

2-dimensional display is a cross-sectional image of the heart anatomy (aortic valve on top left, mitral valve on bottom left). M-mode displays the motion of a particular cross section (represented by the cursor's dotted line) over time (aortic valve on top right, anterior mitral valve leaflet on bottom right). AV: aortic valve, aMVL: anterior mitral valve leaflet, LA: left atrium, LV: left ventricle, MV: mitral valve.

vegetations as well as, identification of ventricular endocardial surface are viewed in M-mode (figure 4).

Newer echocardiographic display formats include **tissue harmonic imaging**, and **three-dimensional echocardiography**. Tissue harmonic imaging is based on the harmonic frequency energy generated as the ultrasound signal propagates through the tissues. These harmonic frequencies result from the nonlinear effects of the interaction of ultrasound with tissue and have two properties: the strength of the harmonic signal increases with depth of propagation, and stronger fundamental frequencies produce stronger harmonics. Harmonic imaging improves endocardial definition and reduces near field and side lobe artifacts in patients with poor fundamental frequency imaging. **3D echocardiography** is performed by simultaneously transmitting and receiving in a three dimensional volume, or reconstructing a 3D image by multiple 2D images, to allow the display of images in 3D. The 3D echocardiography is not yet applicable in the intra-operative setting.

System controls

The diagnostic accuracy of echocardiography is based on competent interpretation of a skillfully performed comprehensive examination. The following describe the majority of (most important) controls found in almost all modern echocardiographic machines [10].

1. **Frequency** increase improves imaging at the expense of depth penetration. In order to maintain line density for imaging a deeper structure, the frequency should be decreased.
2. The displayed **depth** (of examination) affects the pulse repetition frequency and frame rate of the image. **Resolution** or magnification modes focus on a specific depth of interest.
3. The **power output** adjusts the total ultrasound energy delivered by the transducer. Increasing the power results in higher amplitude reflected signals. Modern echocardiographic

machines usually operate on maximal power.

4. The **system gain** uniformly increases the amplitude of all returned (displayed) echoes. Higher system gain increases the ability to display weak or less distinct echoes at the expense of lateral resolution and sometimes, axial resolution as well (noise is maximized, too).

5. **Gray scale/Dynamic range** adjusts the numbers of gray in the image, providing an image with marked contrast or with gradation between the lightest and darkest areas. To improve image quality, dynamic range should be increased first, and then gain. If image is of superior quality, gain should be decreased first, prior to a decrease of dynamic range.

6. **Time-gain compensation** permits differential adjustment of gain along the path of the ultrasound beam. The **near-field gain** controls the amplitude of the strong, near-field echoes (it works as the reverse of TGC).

7. The **damping circuit** decreased the power output of the transducer and shortens the pulse duration, thus decreasing beam width and improving resolution, at the expense of signal strength. The **reject circuit** eliminates the weaker echoes, filtering all signals below a fixed amplitude, thereby removing weaker echoes and background noise from the final display and permitting the higher amplitude signals to be displayed in greater contrast.

Imaging artifacts

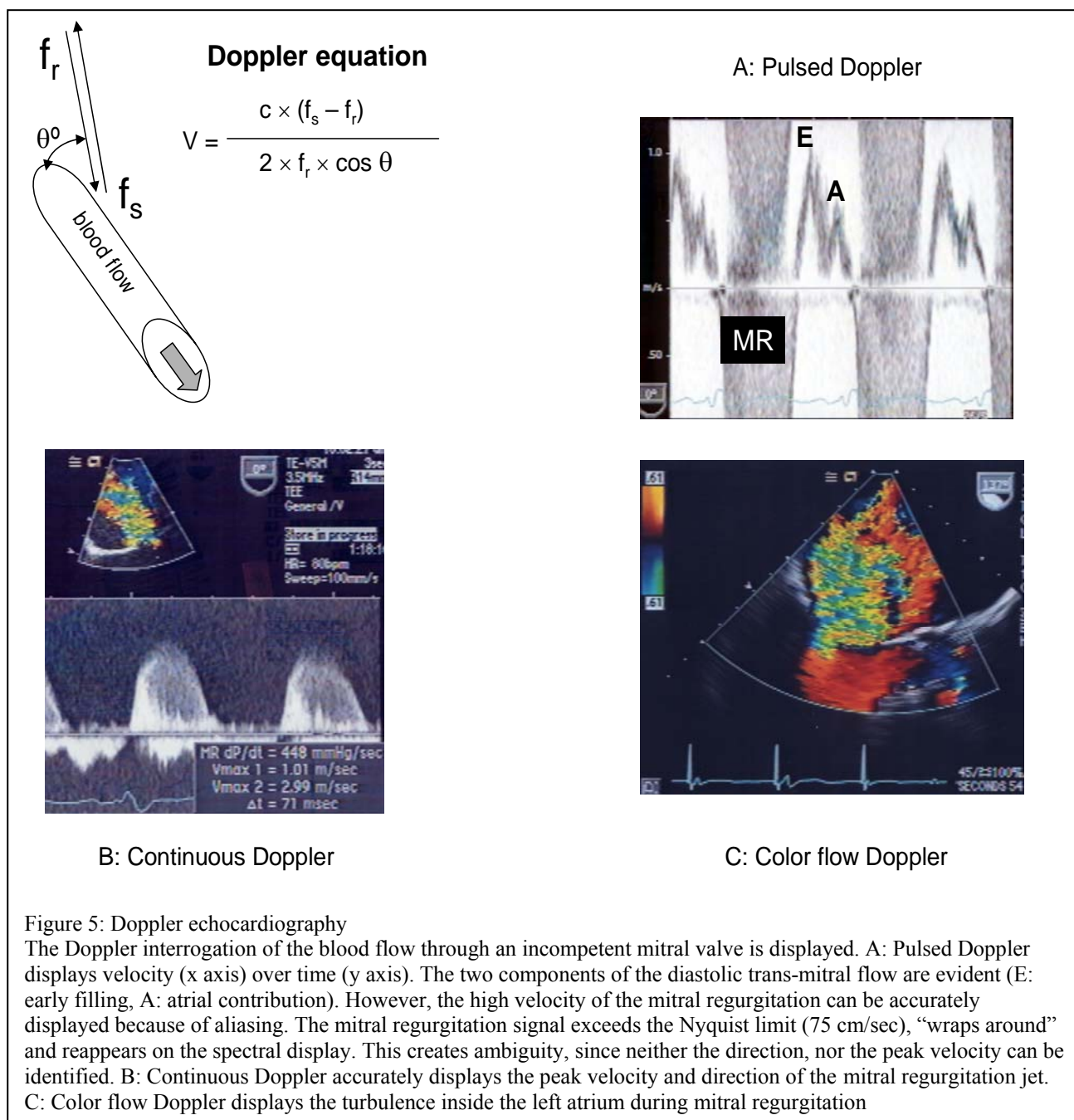
Under the term “imaging artifacts” echocardiographers refer to “structures” that are not actually present at all, are real but appear “misplaced”, the failure to image existing structures, the imaging of a structure much different in size (or shape) than is true. Although beyond the scope of this review, a brief description of the most common imaging artifacts is necessary, since their presence or absence interferes with echocardiographic examination, while knowledge of ultrasound physics helps in their elimination. **Suboptimal image quality** is

due to poor ultrasound beam penetration (because of interposition of high-impedance structures: adipose tissue, lung or bone). Tissue harmonic imaging or TEE may be needed to make an accurate diagnosis. **Acoustic shadowing** occurs when a structure with a marked difference in acoustic impedance (prosthetic valve, calcium deposit) inhibits transmission of the ultrasound wave beyond that point. The resulting image is devoid of echoes distal to this structure. A different acoustic window is needed to circumvent this problem (i.e.: after aortic valve replacement, acoustic shadowing does not allow investigation for the presence or absence of paraprosthetic leak in the mid-esophageal five-chamber, or long-axis view, while investigation is feasible in the deep transgastric view). **Reverberations** are multiple linear high-amplitude echo signals originating from two strong specular reflectors and result in a back-and-forth reflection of the ultrasound signal before it returns to the transducer, limiting evaluation of structures in the far field. The **beam width artifacts** are due to the 3D structure of the ultrasound beam: images at the edge of the far field or from the side lobes will be displayed in the tomographic section corresponding to the main beam, resulting in imaging of structures that do not belong to that particular location. Additionally, poor lateral resolution will result in abnormal displays: line instead of a point. **Refraction** of the transmitted ultrasound beam by tissue near the transducer will cause the beam to deviate from a straight path. The reflected signal of this refracted beam is assumed to have originated from the scan line of the transmitted pulse and is displayed in the wrong location. **Range ambiguity** results in deep structures appearing closer to the transducer than their actual location, when echo signals from an earlier pulse cycle reach the transducer on the next "listen cycle". With change of the depth setting or position, the artifact should disappear [11,12].

Principles of Doppler Echocardiography

The Doppler principle states that the frequency of reflected ultrasound is altered by a moving target. The magnitude of this frequency shift is relative to the velocity of the moving target, while the polarity of the shift, either positive or negative, reflects the direction of the movement, toward or away from the transducer, respectively. The classical Doppler echocardiographic techniques evaluate blood flow velocity with the red blood cells as the moving target. Current ultrasound systems can also apply the Doppler principle to assess velocity within cardiac tissue. The moving target in this case is tissue, such as myocardium, that produces a higher amplitude, and lower velocity backscattered echoes, as compared with echoes reflected by red blood cells. This new application is called **tissue Doppler (TD)**.

In more detail, a moving target will backscatter an ultrasound signal (transmitted with frequency f_r) with a frequency (f_s), which will be higher or lower than f_r if the target moves towards, or away from the transducer, respectively. The difference $f_s - f_r$ is called the **Doppler shift**. Doppler shifts (the difference between transmitted and backscattered frequencies) occur only if the target is moving, are audible (0-20 kHz) and can be used to determine the velocity (v) of a moving target, as expressed in the **Doppler equation**: $v = [c \times (f_s - f_r)] \div [2 \times f_r \times (\cos\theta)]$, where c is the speed of sound in blood (1540 m/sec), 2 is a factor to correct for the transit time both to and from the target, and θ is the **intercept angle** between the US beam and the direction of motion of the moving target. Since c and f_r are known, v depends on the Doppler shift and the intercept angle θ . The cosine of an angle 0° or 180° is 1, and the angle of intercept can be ignored if the US beam can be aligned parallel to the direction of motion of the target. With an angle of intercept $<20^\circ$, the cosine is close to 1 ($\cos 20^\circ = 0.94$) and the angle can still be ignored. However, with $>20^\circ$ angles of intercept, velocity becomes significantly affected by θ : at 60° the recorded velocity is half of the real



one ($\cos 60^\circ = 0.5$). The direction of the moving target (blood) can be difficult to ascertain from the 2D image, even more so for abnormal flow patterns, and attempts to correct for intercept angle may result in errors. Furthermore, even if the blood flow direction is well apparent in 2D imaging, one should keep in mind the direction in the elevational plane of the ultrasound beam remains unknown. From the above, it is obvious that Doppler-derived velocity measurements depend on parallel alignment of the ultrasound beam with the investigated blood

flow. In addition, it is apparent that Doppler echocardiography and 2D or M-mode imaging have quite opposite requirements. 2D imaging is at best when the ultrasound beam strikes a large reflective (mirror-like) surface at perpendicular angle of incidence, while Doppler echocardiography will detect no Doppler shift at 90° , since $\cos 90^\circ = 0$. Besides, the best Doppler information occurs with lower frequency transducers, a situation reverse of what is preferred for 2D echocardiography. In general, it is difficult to obtain an excellent Doppler examination and

an excellent cardiac image simultaneously [13,14]. Once the reflected signal is received, the difference between the transmitted and backscattered signal is determined by “comparing” the two waveforms. The multiple frequencies present in the back-scattered signal are analyzed with a process called fast Fourier transform and the generated display is called **spectral analysis** (figure 5A). This shows time in the horizontal axis, contains a zero baseline in the center and frequency shifts along the vertical line, above the baseline if directed toward the transducer and below if directed away. The amplitude (or loudness/strength) of the different frequencies is depicted with gray (or color) scale and their velocity with their distance from the zero baseline. The spectral display contains, at each time point, information regarding direction of motion, velocity and signal amplitude. Although color Doppler echocardiography uses 2D imaging, pulsed and continuous wave Doppler signals are optimal when the 2D image is frozen.

Continuous wave (CW) Doppler echocardiography uses two crystals, one transmitting and one receiving, so that very high frequency shifts can be measured accurately since sampling is continuous. The disadvantage of the technique is that all signals along the entire length of the ultrasound beam are recorded simultaneously, and one does not know where the individual target might be in relation to the transducer, or whether there is more than one moving target (there is no axial resolution). However, the characteristics of the signal (timing, shape, direction) as well as, 2D or other modes help to determine the depth of origin of the Doppler signal. A good quality Doppler signal has smooth contour with a well-defined edge, maximum velocity, onset and end of flow (figure 5B).

Pulsed Doppler (PW) echocardiography allows sampling of velocities from a specific intracardiac depth by transmitting an ultrasound beam and then sampling the back-scattered signal (PW Doppler can be described as a “time-gated” modification of the CW mode). **Sample volume** (usually 5

mm) is the volume of blood or tissue being investigated. The major disadvantage of PW is the inability to detect high-frequency velocities. The upper limit of frequency that can be detected is called the “**Nyquist**” limit (or number), which is approximately $\frac{1}{2} \times \text{PRF}$. Aliasing introduces confusion as to the direction of the flow (the signal is cut off at the edge of the display and the top of the waveform appears arising from the edge of the opposite direction towards the zero baseline), (figure 5A) and also prohibits one from measuring the maximal velocities. Methods to resolve aliasing include shifting the baseline (an electronic form of “cut and paste”), using a lower frequency transducer, increasing the PRF (essentially increasing the Nyquist limit) or using instead CW Doppler. **High PRF** introduces range ambiguity to increase the maximum velocity that can be detected. Multiple sample volumes are placed proximal to and at the depth of interest. PRF is determined by the depth of the most proximal sample volume, which allows measurement of higher velocities without signal aliasing at the depth of interest. The resulting spectral display includes frequencies from each of the sample volume depths, but the origin of the high-velocity signal is inferred from anatomic and physiologic data.

Color (Flow) Doppler (CD) echocardiography is a modified Doppler technique: instead of one sample volume along a single (PW), or along the entire (CW) ultrasound beam, the 2D image is scanned with multiple lines and with multiple sample volumes (usually eight) along each line. The mean (instead of peak, as in PW and CW) velocity of laminar blood flow is displayed and direction of flow is depicted by using blue color for flow away from, and red color for flow toward the transducer, respectively (mnemonic, BART: Blue Away Red Toward). An additional color (green) may be added along the color scale to indicate if the mean velocity for each of the sample volume had excessive variability [turbulence] (“variance”). As a pulsed US technique, color Doppler is limited by the physics of pulsed waves and is even more limited by aliasing

(manifested as color reversal). In addition, the frame rate with color Doppler is relatively slow because of the necessary electronic manipulation required. To increase the frame rate in color Doppler, one must decrease the sampling size, use lower frequency and reduce the scanning angle [15,16].

Limitations specifically related to color Doppler

The change in color may be due to either the blood flow direction relative to the transducer, or secondary to velocity aliasing. Although used extensively for evaluation (and quantification) of valvular regurgitation, as an equivalent to the regurgitation of dye during angiography, one should keep in mind that color Doppler simply records blood velocity. Therefore, the blood velocity recorded in the receiving cardiac chamber is not necessarily caused entirely by regurgitation of blood, nor the recorded velocity is proportionally related to the regurgitant orifice area. Furthermore, instrumentation settings and hemodynamic conditions (compliance of the receiving cardiac chamber, afterload, pressure gradient) also affect the recorded velocities. The color Doppler should be used for investigation or documentation of abnormal flow, and the flow abnormality should be evaluated further by PW or CW Doppler.

Instrumentation controls in Doppler echocardiography

The instrumentation controls in Doppler echocardiography are used to change the position of the sample in the desired position along the scan line (PD) or for steering the ultrasound beam (CW), shift the zero (baseline) velocity line, alter the size of the sample volume (PD), calculate the angle θ (not recommended), change the volume of the audible Doppler signal (PW, CW), alter the size of the sampling (CW, color Doppler), and filter out low frequency signals.

Clinical applications of Doppler echocardiography

Flow velocity can be evaluated using all 3 modes of Doppler echocardiography. Color Doppler allows faster detection of abnormal flows and provides a spatial display of velocities in a 2D view. Quantification of flow is performed with either PW or CW Doppler or, as is the case of proximal flow convergence in valvular regurgitation, with CD. PW Doppler is used primarily to assess velocities across normal valves or vessels, to evaluate cardiac function (diastolic and systolic function) or calculate flow (cardiac output, regurgitant volumes and intracardiac shunt flow). Tissue PW is used to measure blood velocities of the contracting and relaxing myocardium. CW Doppler is used to measure high velocities across restrictive orifices, such as stenotic or regurgitant valvular lesions. Based on the simplified **Bernoulli equation**, pressure gradient across an orifice is equal to the square of the distal (post-orifice) velocity times 4 (provided that the pre-orifice velocity is <1.5 m/sec): PG (mmHg) = $4 \times v^2$. In addition, intracardiac chamber pressures can be calculated: for example, the systolic RV or PA pressure are equal to the peak velocity of a tricuspid regurgitation jet, if the RAP is known, and no pulmonary artery stenosis exists [17,18].

References:

1. Otto CM: Principles of echocardiographic image acquisition and Doppler analysis. In Otto CM: Textbook of clinical echocardiography. WB Saunders, Philadelphia 2000, pp 1-3
2. Weyman AR: Physical principles of ultrasound. In Weyman AR (Ed): Principles and practice of echocardiography, 2nd edition, Lippincott Williams & Wilkins, Philadelphia 1994, pp 9-13
3. Feigenbaum H: Instrumentation. In Feigenbaum H (Ed): Echocardiography, 5th edition. Lea & Fabiger, Philadelphia, 1994, pp 14-5
4. Weyman AR: Cross-sectional scanning: technical principles and instrumentation. In Weyman AR (Ed): Principles and practice of

echocardiography, 2nd edition, Lippincot Williams & Wilkins, Philadelphia 1994, pp 45-7

5. Weyman AR: Physical principles of ultrasound. In Weyman AR (Ed): Principles and practice of echocardiography, 2nd edition, Lippincot Williams & Wilkins, Philadelphia 1994, pp 23-7

6. Weyman AR: Physical principles of ultrasound. In Weyman AR (Ed): Principles and practice of echocardiography, 2nd edition, Lippincot Williams & Wilkins, Philadelphia 1994, pp 8-9

7. Feigenbaum H: Instrumentation. In Feigenbaum H (Ed): Echocardiography, 5th edition. Lea & Fabiger, Philadelphia, 1994, pp 3-7

8. Feigenbaum H: Instrumentation. In Feigenbaum H (Ed): Echocardiography, 5th edition. Lea & Fabiger, Philadelphia, 1994, pp 7-14

9. Otto CM: Principles of echocardiographic image acquisition and Doppler analysis. In Otto CM: Textbook of clinical echocardiography. WB Saunders, Philadelphia 2000, pp 9-10

10. Weyman AR: Physical principles of ultrasound. In Weyman AR (Ed): Principles and practice of echocardiography, 2nd edition, Lippincot Williams & Wilkins, Philadelphia 1994, pp 21-3

11. Otto CM: Principles of echocardiographic image acquisition and Doppler analysis. In Otto CM: Textbook of clinical echocardiography. WB Saunders, Philadelphia 2000, pp 11-4

12. Miller JP, Perrino AC, Hillel Z: Common artifacts and pitfalls of clinical echocardiography. In Perrino AC Jr, Reeves S (Ed): A practical approach to transesophageal echocardiography, 1st edition, Lippincot Williams & Wilkins, Philadelphia 2003, pp 309-14

13. Feigenbaum H: Instrumentation. In Feigenbaum H (Ed): Echocardiography, 5th edition. Lea & Fabiger, Philadelphia, 1994, pp 26-32

14. Weyman AR: Principles of Doppler flow measurement. In Weyman AR (Ed): Principles and practice of echocardiography, 2nd edition, Lippincot Williams & Wilkins, Philadelphia 1994, pp 155-9

15. Feigenbaum H: Instrumentation. In Feigenbaum H (Ed): Echocardiography, 5th edition. Lea & Fabiger, Philadelphia, 1994, pp 32-5

16. Otto CM: Principles of echocardiographic image acquisition and Doppler analysis. In Otto CM: Textbook of clinical echocardiography. WB Saunders, Philadelphia 2000, pp 16-22

17. Oh JK, Seward JB, Tajik AJ: The echo manual. Lippincot Williams & Wilkins, Philadelphia 1999, pp 45-71

18. Zoghbi WA, Enriquez-Sarano M, Foster E, et al: Recommendations for evaluation of the severity of native valvular regurgitation with two-dimensional and Doppler echocardiography. J Am Soc Echocardiogr 2003; 16:777-802

Correspondence :

Nikolaos Skubas, MD
Assistant Professor, Assistant Attending
Director, Intraoperative Echocardiography, Department of Anesthesiology
Weill Medical College
New York-Presbyterian Hospital
525 East 68th Street, M-302C
New York, NY 10021
Telephone: +212 746-2755
Fax: +212 746-8563
E-mail: njs2002@med.cornell.edu

Keywords: ultrasound, echocardiography, Doppler.