

Permanent Restoration in Endodontically Treated Teeth: Clinical Dilemma, Future Trends and Review of Literature

Sudhanshu Shekhar¹, Sanjeev Mittal²

¹Postgraduate Student, Department of Prosthodontics, Maharishi Markandeshwar College of Dental Sciences and Hospital, Mullana, Ambala, Haryana, India, ²Professor, Department of Prosthodontics, Maharishi Markandeshwar College of Dental Sciences and Hospital, Mullana, Ambala, Haryana, India

ABSTRACT

The final and quality restoration of endodontically treated teeth involves a critical decision-making step, especially when in cases where difficult, complex prosthetic rehabilitations are required. Regarding single tooth undergoing an endodontic procedure, there are high-level requirements for the restorative components and the application of all necessary treatment steps to achieve the final restoration. Teeth that are affected by caries, fractured teeth or any pathology and tooth having multiple restorations that can be treated endodontically or conservatively are considered for endodontic surgical procedures. In addition to supposed teeth for a desirable endodontic procedure and under curative nature for endodontic treatment that is already weakened due to any anomaly it will further lead to weakening of internal as well as external tooth structures. Therefore, it is well accepted fact that on the basis of previous literatures and researched that endodontically treated teeth are structurally weaker, and they require special consideration for final restoration which should involves increased retention procedures to increase lifespan of that tooth, while maintaining adequate root strength. Different materials and techniques have been developed and or proposed to restore such teeth while retaining their function, strength, and longevity.


Key words: Endodontics, restoration, root canal treatment, conservative

INTRODUCTION

Teeth don't always have the same anatomy, variations such as some roots and its canal or even many times shape of the root is not the same. The conservative procedures like restorations, etc. for extensive damage teeth is one that have lost its external, internal or both structures due to any anomaly is a significant clinical dilemma for clinicians. Most of the dental practitioner

tries to treat all the teeth in the same standard procedure of conservatively or endodontically to save the teeth. There are compelling shreds of evidence from previous studies that the root canal treatment (RCT) affords excellent clinical outcomes for patients undergoing endodontic procedures. One such measure of success is the survival of the tooth over extended periods of time after a conservative or endodontic surgery, e.g., RCT, etc.

Now, a traditional RCT involves the removal of necrotic and infected tissue along with the provision of a well-condensed obturation so as to prevent further microbial proliferation into the canal system.^[1] The ingress of microbes into the canal system compromises the outcome of endodontic treatment. Eliyas *et al.* in the year 2015 have very clearly summarized the importance

| Access this article online | |
|---|---|
| Publisher  | Website: www.renupublishers.com |
| | DOI: 10.5958/2394-4196.2015.00021.7 |

Address for Correspondence:

Dr. Sanjeev Mittal, Maharishi Markandeshwar College of Dental Sciences and Hospital, Mullana, Ambala, Haryana, India.
E-mail: ambaladental@yahoo.com

Submission: 26 Jul 2015; **Revision:** 20 Aug 2015; **Acceptance:** 09 Sep 2015

of an adequate coronal seal in endodontic surgery [Table 1].^[2-4]

Over the years, controversies seem over the variety of materials used for the reinforcement of the endodontically treated teeth, especially over the use of a post and core material.^[3] Ideally, the restoration is accompanied by two procedures:^[3] Placement of a core or a post and core, and placement of a final cast restoration. The core provides a foundation on which the cast restoration can be placed for reinforcement, whereas the cast restores the tooth to its original contours and functions.

Even though the successful RCT promises to enhance the lifespan of the treated tooth in both structural and aesthetic aspects, there are few studies that suggest that the teeth with root canal procedures and are not restored with permanent restoration after their RCT are thought to be about two to four times weaker. And thus results in failure of RCT and chances to undergo for extraction of that teeth as compared to that teeth that were restored with a permanent restoration.^[4] This assessment via reviewing the previous research was similar to that observed in the other studies or literature that have proven the same facts about post-operative restoration in endodontically treated teeth.^[5-7] It is so suggested that saving the natural tooth requires both excellent endodontic treatment along with follow-up for a restorative treatment.

Based on these controversies, we have done this systematic literature review, so as to summarize the findings of various studies being done in this field, the related issues as per case studies and to conclude as to what stands best in favor of the patients.

METHODS

Search strategy for identification of studies: A Pubmed literature including Google search was performed, which

includes the following search terms: “endodontically treated tooth,” “retaining endodontically treated teeth,” and “post endodontic treatment.” Search was limited to review articles. The English language works of literature were only explored and included and was reviewed.

Treatment planning for endodontically treated teeth

Schilder has given four key objectives for the preparation of restoration of an endodontically treated tooth:^[7]

- Treatment procedures must be confined to the roots
- Necrotic debris must not be forced beyond the apical foramina
- All pulp tissues must be removed from the root canal space
- Sufficient space must exist for the intra-canal medicaments and irrigants.

These objectives have provided for a basis of assessing the quality of the endodontic procedure prior to a restoration of the tooth.

Goerig and Mueninghoff had suggested that the tooth restoration be based on the following 5 criteria:^[8]

1. Location of the tooth in the arch
2. Root morphology
3. Degree of coronal destruction
4. Amount of occlusal stress
5. Whether the tooth would serve as an abutment for fixed or removable partial denture.

Based on These Principles the Decisions have been made at all Times

Points to considered after and during RCT

As and when we plan for an RCT, the tooth should first be properly examined for any caries and fracture.^[9] Further, the assessment needs to be made for storability, occlusal function, and periodontal health, and issues such as biological width and the crown-to-

Table 1: The importance of good coronal seal^[2]

| Study | Measure of coronal seal | Number of teeth | Outcome |
|---------------------------------------|-------------------------|-----------------------------|--|
| Ray and Trope ^[3] | Rads | 1,010 (no post+cores) | GR more important than GE |
| Tronstad <i>et al.</i> ^[4] | Rads | 1,000 (post+cores included) | GE more important than GR |
| Kirkevang <i>et al.</i> | Rads | 773 | Better periapical status with GR |
| Hommez <i>et al.</i> | Exam and Rads | 745 | Better periapical status with GR |
| Boucher <i>et al.</i> | Rads | 5,373 | No coronal restoration more periapical areas |
| Segura-Egea <i>et al.</i> | Rads | 93 | Better periapical status with GR |
| Tavares <i>et al.</i> | Rads | 1,035 | Better periapical status with GR |
| Ng <i>et al.</i> | Exam and Rads | 1,452 | Better periapical status with GR |

Eliyas *et al.* 2015^[2], GE: Good endodontics, GR: Good restoration

root ratio should be evaluated. If these factors are deemed satisfactory, the tooth can be included in the comprehensive treatment plan.

As possible, all previous restorations, caries (decayed) must be removed before initiating the RCT.^[9] The principal accent should be on prevention of secondary infection from further contamination as it is thought to be an important determinant of future dilemmas in endodontically treated teeth. Delaying restorative treatment procedure should not be the pre-eminent concern for the patient. Temporary restorations in case of such type of teeth do not efficiently limit contamination for extended time periods, nor do they prevent from fractures due to functional overload.^[9]

It is thought be that after endodontic or conservative treatments, there is a loss of the mechanoreceptors, which increases the threshold of the pressure receptors in the periodontium, leading to functional overload.^[10] Furthermore, there is decreased elasticity, tensile strength and shear of the tooth, due to the loss of pulp, causing dehydration of the tooth. An endodontically treated tooth with a crown can withstand more loads, compared to the tooth that is restored only with a restorative filling.

The changes in the methods for restoring endodontically treated teeth depend on the improvement of adhesive techniques, resin composite materials, fiber posts, and indirect ceramic materials.^[11] Furthermore, there are many challenges inherent in treating teeth with an endodontic disease, before finalizing on the type of restoration to be undertaken. An RCT can be performed on almost any tooth, but its restore ability must be discussed prior to the deciding which endodontic treatment to be undertaken.^[11,12]

Restoration of Intact Teeth

Prior to restoration of teeth, few assessments must be made for:^[12]

- Cracked/fissured teeth [Figure 1 a and b]
- Enamel craze lines [Figure 2].

Teeth, where the access cavity has been preserved, can be treated effectively simply by the filling with a base over the gutta-percha and a coronal bonded composite resin.^[10] The ones with insignificant loss of tooth structure can be taken care of using a core and a cast restoration. Amalgam restoration in conservative dentistry is one of the most common and universally

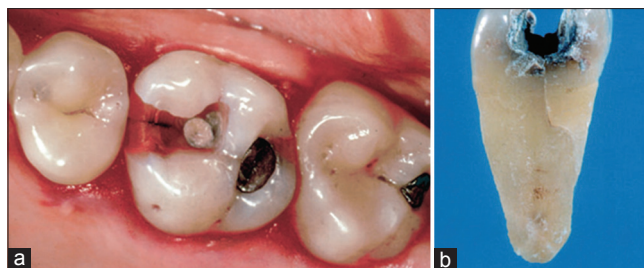


Figure 1: (a and b) Fissured and cracked teeth

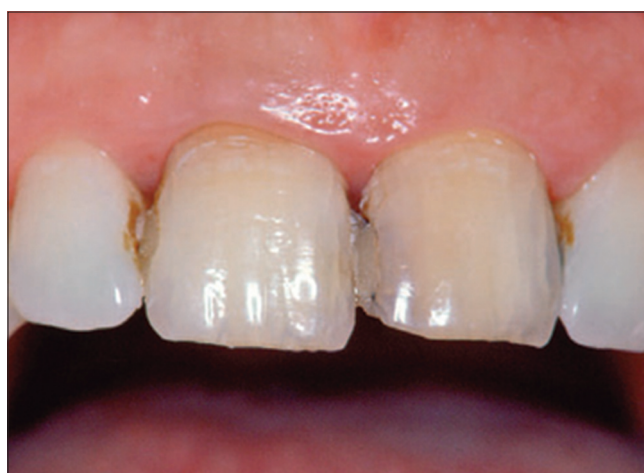

Figure 2: Enamel craze lines

used core materials for such restorations. It has been used as a direct restoration because of many clinical, practical, and ergonomic advantages of providing the optimal marginal seal, wear resistance and compression strength along with good polishability and excellent costs-benefits ratio.^[13] The disadvantages of amalgam being long setting time, corrosion reaction and base metal alloy due to galvanic activity and the prevention of natural tooth translucency, in conjunction with ceramic crowns.^[10]

Gold restoration is another “noble” yet “high quality” alternative to amalgam. Cast gold partial crowns have in the past ensured conservative preparations, protection against biomechanical stress with optimal long-term reliability.^[14] The use of gold restorations has however decreased, despite its reliability. Today, it is still the material of choice for posterior teeth, majorly where aesthetics is not a concern. The second molars are also suitable candidates for such restoration, especially in case of limited interocclusal space or in bruxism patients.^[15]

However, these restorations are possible only when a single axial wall is missing, whereas, in cases where 2 or more axial walls are lost, a post becomes mandatory for restoration.^[10]

Restoration of Anatomically and Structurally Weakened Teeth

Teeth that have little or no coronal remnant require the use of intra-radicular post and core. It should be made sure that there is little or no coronal remnant to retain or support the final restoration, only then will the post and core behave successfully.^[16]

The Endodontic Post

Post-installation is recommended only in case of extensive loss of tooth structure and should be restored with very caution. Inter-radicular post restoration can also lead to fracture of teeth. Thus, inter-radicular installation is advised when other options to retain a core or final restoration cannot be used. For example, Molars may not require posts because a core can usually be retained by the pulp chamber and canals.

Whenever a post treatment becomes necessary, it should be ideally fixed in a palatal canal of maxillary molars and the distal canal in mandibular molars, as the other canals are thinner and more curved.^[9] Anterior teeth with the extensive loss of coronal tooth structure usually need a post because the pulp chamber and single canal are not adequate to retain a core. Furthermore, anterior teeth are subject to lateral forces during function, whereas posterior teeth are subject primarily to vertical forces. Premolars because of their transitional morphology require clinical judgment. Decisions on whether a post is indicated to compensate for the extensive loss of coronal tooth structure will depend on the structure of the remaining denture.^[17]

Now, the use of a post has an associated risk of root fracture, particularly if sound dentin is removed during preparation. Development of the post space in such type of teeth can also lead to perforation apically or a lateral strip perforation in the fluted portion of the mid-part of the root. To avoid these problems, the dentist should prepare the post space.^[18]

Some of the areas of general agreement and few points to be considered regarding post design include:^[19]

- When a post is needed, remove little if any additional dentin beyond what is required to perform the RCT
- Retain a minimum of 4 mm of gutta-percha apically
- Use a post designed to incorporate mechanical

features that resist rotational forces. Since forces concentrate at the crest of bone during function, place the post to extend apically to the crest of the bone

- One “rule of thumb” is that the post should extend “into bone” at least as far as it protrudes “out of bone.”

Post Materials

Nearly all posts were made of metal until recent years. However, now they are also available in ceramic, composite and fiber-reinforced materials.^[9] There are two main categories of posts, Custom-fabricated and prefabricated. Custom-fabricated cast gold post and core have been used as a foundation restoration to support the final restoration in endodontically treated teeth. A 6 years retrospective study reported a success rate of 90.6% using a cast post and core as a foundation restoration. Cast gold alloy (Type III or IV) is an inert material with modulus of elasticity (stiffness of 14.5×10^6 psi) and coefficient of thermal expansion ($\approx 15 [C-01] \times 10^6$) similar to those of enamel, and yet it has enough compressive strength that can withstand normal occlusal forces.^[20] Other commonly used post materials are cast metal posts, prefabricated metal posts, ceramic, glass and zirconium posts, fiber posts, and luting materials.^[9]

Post Space Preparation

- The anatomy of the root is an important parameter to be studied before preparing any canal space for installation of the post. The root diameter differs in the facial-lingual and mesiodistal dimensions. These considerations, such as root taper, proximal root invaginations, root curvatures and angle of the crown to the root during the mechanical preparation of a post space so to determine the appropriate post length and width to avoid root perforation, must be kept in mind.^[21]
- An excellent review of anatomical and biological considerations in restoring endodontically treated teeth has been given by Gutman.^[19] Mechanical preparation technique for post spaces is most commonly used because they are faster. However, it is associated with a higher risk of root perforation and may disturb the apical seal. It has been established that Gates-Glidden drills and P-type reamers used on low speed are the safest instruments.^[20-22] Use of one of these instruments should precede the utilization of any post drill that comes with the

prefabricated post kit. The thermal method of removing gutta-percha using heat pluggers is safer but more time-consuming

- It has been observed that the longer the post in the canal, the more retentive it is. However, increased post length also increases the risk of fracture and perforation of the remaining root.^[23] It is accepted that the apical 3-6 mm of gutta-percha must be preserved to maintain the apical seal.^[24-26] Guidelines accepted for determining the post length include the following^[27,19]
- Post length should be equal to the clinical crown length
- Post length should be equal to one-half to two-thirds of the length of the remaining root
- Post should extend to one-half the length of the root that is supported by bone
- It is observed widely that the post diameter makes little difference in the retention of the post. It has been studied by clinicians that an increase in the post's width increases the risk of root fracture.^[19,25,28-30] The post width should not exceed one-third of the root width at its narrowest dimension, and clinicians should bear in mind that most roots are not perfectly rounded.^[30]

Post Cementation

Cement is used to improve post retention, help in creating a seal and acts as a buffer zone for stress distribution. Some of the most common used dental cement is zinc phosphate, polycarboxylic, glass ionomer cement, resin-based composite and the hybrid of resin and ionomer cement. Among all these zinc phosphates have the longest history of success. However, the use of various types of fiber-reinforced posts and resin cement is becoming increasingly popular.

Numerous *in vitro* and *in vivo* research have been done to compare failure mode, retention, and fracture strength of various post (two types custom fabricated and pre-fabricated) systems using continuous or intermittent loading with mixed results. Schwartz and Robbins have offered a detailed view of similar results in their review.^[31,32]

Core Buildup and Restoring the Tooth Finally

The importance of the core is such that it enhances the development of retention and resistance provided by the remaining tooth structure.^[33] Some of the desirable features of an ideal core material have been detailed by

Morgano and Bartlett:^[25,28]

- Adequate compressive strength to resist intraoral forces
- Sufficient flexural strength
- Biocompatibility
- Resistance to leakage of oral fluids at the core-to-tooth interface
- Ease of manipulation
- Ability to bond to remaining tooth structure
- Thermal coefficient of expansion and contraction similar to tooth structure
- Dimensional stability
- Minimal potential for water absorption
- Inhibition of dental caries

DISCUSSION

As stated earlier, conventional core materials such as amalgam and cast gold core hold some disadvantages, and there is no such ideal core material as of today. Despite a few drawbacks, these core materials tend to hold the market. However, the use of glass ionomer cement as a core material should be avoided. This statement is driven by the results of an *in vitro* study comparing resin-based composite, amalgam, and cast gold as core material under a crown in endodontically treated teeth^[32] found no significant difference in fracture and failure characteristics of these materials, provided a 2 mm ferrule existed on the margin of healthy tooth substance.^[33] Glass ionomer cement, however, was shown to be weak in tensile and compressive strengths, and it had little fracture resistance as a core material in another study.^[34,35]

Now, the question arises as to whether full cuspal coverage should be carried out routinely on endodontically treated teeth or not. Reeh *et al.* in the year 1989^[36] compared the contributions of endodontic and restorative procedures to the loss of cuspal stiffness by using nondestructive occlusal loading on extracted intact human teeth. They concluded that endodontic procedures reduced the relative stiffness by only 5%. An occlusal cavity preparation, on the other hand, caused a 20% reduction of cuspal stiffness, and mesial-occlude distal cavity preparation caused a 63% reduction. They concluded that endodontic procedures do not weaken teeth with intact marginal ridges.

Meyenberg in the year 2013^[37] stated that the restoration of endodontically treated teeth has much in common with modern implantology: Both must include

multifaceted biological, biomechanical and esthetic considerations with a profound understanding of materials and techniques. He also concludes those both are technique sensitive and require a multidisciplinary approach. And for both, two fundamental principles from team sports apply well: first, the weakest link determines the limits, and secondly, it is a very long way to the top, but a very short way to failure.

Várlan *et al.* in the year 2009^[38] gives Basic principals in restoration of endodontically treated teeth:

The most relevant perspective to be judged after RCT is coronal restoration that reduces the vital tooth structure after caries or trauma. Noncarious lesions (abrasion, erosion or abfraction), should also be considered, and it is a significant factor in RCT procedure, primarily associated with the age of patient's. Preparation of extensive access opening and endodontic procedures itself are the prime causes of tooth fragility, which will further result in partial or complete fractures of tooth cusps or roots and incised margins.^[19]

Moreover, teeth can be weakened not only by endodontic procedures but by pre-existent restorative techniques that also decrease tooth strength, as well as by the removal of marginal ridges. Endodontic procedures associated with removal of pulp chamber wall and root dentin resembles directly responsible for the greater brittleness of such type of teeth. Other determinants that may also influence the fracture resistance of teeth are external and internal anatomy of teeth and its position and the alterations in the mechanical and physical properties of dentin.^[20]

- Cuspal coverage restorations appear to grant higher longevity to posterior teeth with RCT; according to some recent studies, bonded restorations thought to preclude the need for cuspal coverage in such teeth, might provide a short-term strengthening.^[9,11]
- Bonded restorations represent the main choice for conservatively restoring anterior teeth with the minimal loss of tooth structure.^[2]
- Maximum preservation of coronal and radicular sound tooth structure is recommended; coronal tooth structure should be preserved to provide resistance and retention form, either for conservative bonded restoration, or for the core, which will support the crown.^[59,21,22] The purpose of a core is to provide the compromised crown of the tooth with resistance, retention, and geometric form for the final restoration. The core material fills the pulp chamber and replaces lost tooth structure prior

to crown preparation. The amount of remaining radicular tooth structure is important for the choice and placement of a post

- When a tooth has more than 50% of its coronal structure missing, the use of a post and core foundation is recommended prior to prosthetic restoration. The main purpose of a post is to retain a core buildup in a tooth with extensive loss of coronal tooth structure
- Since posts do not reinforce endodontically treated teeth, they are indicated only when there is inadequate tooth structure to retain a core; however, preparation of a post space adds a certain degree of risk to a restorative procedure
- Posts can be prefabricated or custom made. Custom cast posts and cores allow for a close adaptation of posts to the post space preparations and should fit optimally.^[23] Prefabricated posts have an advantage in that the post space can be prepared and the post directly bonded in a single appointment
- A ferrule, defined as “a metal band or ring used to fit around the root or crown of a tooth,”^[12] is highly desirable when a post is used. An adequate ferrule is considered to need a minimum of 2 mm of vertical height and 1 mm of dentin thickness.

Radiographic examination is an integral part of the diagnosis, treatment planning, and management in endodontic. Angulated and digital radiography including cone-beam computed tomography (CBCT) compared to single radiographs substantially will gain the aptness to recognize changes in anatomy of teeth.^[40] The information provided in angulated and digital radiography will be limited because superimposition and distortion of teeth structures and the fact that it is a two dimensional image.^[41] Use of CBCT can help overcome these limitations associated with intraoral and panoramic radiography. CBCT can be used to highlight particular anatomic regions for diverse diagnostic tasks by reconstructing the projection data to provide interrelation images in 3 planes. The elimination of anatomic noise facilitates the assessment of some features essential in endodontic diagnosis and treatment.^[42]

One of the causes of failure of endodontic treatments is an incomplete instrumentation or filling of all root canals.^[43] Furthermore, Ingle^[44] considered that one of the most important causes of endodontic treatment failure is the incomplete filling of the root canal system. Similarly, Vertucci^[45] and DeGroot and Cunningham^[46] reported that a considerable number

of failures could be assigned to anatomical variations, such as the presence of canals not usually found.

Eugeniu, *et al.* in the year 2015^[47] in his study stated that during dental treatments, chlorhexidine an oral rinse solution or gel for topical application is used, and it can also be used to enhance the life span of by using it as an irritant solution in endodontic and conservatively treated teeth.

Esteves *et al.* in year 2011^[48] gives a classification of teeth with extensive endodontic damage as follows:

Class I

- Ferrule effect: Height of remaining tooth ≥ 2 mm at 4 locations (mesial, distal, buccal, palatine or lingual) and thickness of remaining tooth walls ≥ 2.2 mm for an esthetic restoration or ≥ 1.6 mm for nonesthetic restorations
- Remaining root length: At least as long as the future crown height plus 5 mm for the apical seal
- Endodontic condition: Endodontic treatment may be performed without predictable complications
- Prognosis: Good.

Class II

- Ferrule effect: Height of remaining tooth 0.5-2 mm or width of remaining tooth walls 1.6-2.2 mm with visible margins or 1.2-1.6 mm with non-visible margins
- Remaining root length: Less than crown height plus 5 mm but equal or greater than crown height plus 3 mm
- Endodontic condition: Without predictable complications or with uncertain results
- Prognosis: Moderate
- Note: A tooth in this class should not be used as an abutment. A new evaluation should be performed after endodontic treatment in cases where pretreatment prognosis is uncertain.

Class III

- Ferrule effect: Height of remaining tooth < 0.5 mm or width of remaining tooth wall < 1.2 mm at future margin level
- Remaining root length: Less than crown height plus 3 mm
- Endodontic condition: With irreversible complications
- Prognosis: Poor.

CONCLUSION

Comprehensive studies of the literature and cases have led us to draw meaningful conclusions as to how the endodontically treated tooth must be handled. The primary goal of retaining the treated tooth must be planned strategically as per the present condition of the tooth for best and long-term results. The first step should be to assess the level of predictability involved in the restoration. Anterior teeth with intact crowns, merely closing the access with composite should be as lucky as placing a crown. However, where significant coronal destruction has occurred, a crown with a cast post core should come into play. A crown is however indicated on all endodontically treated posterior teeth.

Retaining a losing tooth is, however, one of the challenges faced by dentists world over, and longitudinal and long follow-up studies are still needed to draw conclusions on procedures for all teeth.

REFERENCES

1. European Society of Endodontology. Quality guidelines for endodontic treatment: Consensus report of the European Society of Endodontology. *Int Endod J* 2006;39:921-30.
2. Eliyas S, Jalili J, Martin N. Restoration of the root canal treated tooth. *Br Dent J* 2015;218:53-62.
3. Ray HA, Trope M. Periapical status of endodontically treated teeth in relation to the technical quality of the root filling and the coronal restoration. *Int Endod J* 1995;28:12-8.
4. Tronstad L, Asbjørnsen K, Døving L, Pedersen I, Eriksen HM. Influence of coronal restorations on the periapical health of endodontically treated teeth. *Endod Dent Traumatol* 2000;16:218-21.
5. Kohli S. Restoration of endodontically treated tooth: Recent concepts. Available from: <http://www.medindia.in/eaat/t90/i1/eaat90i1p25.pdf>. [Last cited on 2015 Jul 15].
6. Mindiola MJ, Mickel AK, Sami C, Jones JJ, Lalumandier JA, Nelson SS. Endodontic treatment in an American Indian population: A 10-year retrospective study. *J Endod* 2006;32:828-32.
7. Schilder H. Cleaning and shaping the root canal. *Dent Clin North Am* 1974;18:269-96.
8. Goerig AC, Mueninghoff LA. Management of the endodontically treated tooth. Part I: Concept for restorative designs. *J Prosthet Dent* 1983;49:340-5.
9. Baba NZ. Treatment planning for endodontically treated teeth. Contemporary restoration of endodontically treated teeth. Evidence-Based Diagnosis and Treatment Planning. Chicago, IL: Quintessence Publishing Co.; 2013.
10. Modern anderlini G. Guidelines for the Restoration Dental. Bologna: Edizioni Martina; 1995.
11. Mangani F. Partial crowns in gold for the restoration of the elements rear endodontically treated. *G Ital Endod* 1988;2:37-45.
12. Mannocci F, Cowie J. Restoration of endodontically treated teeth. *Br Dent J* 2014;216:341-6.
13. Gonzaga CC, Campos EA, Baratto-Filho F. Restoration of endodontically treated teeth. *RSBO* 2011;8:e33-46.
14. Robbins JW. Guidelines for the restoration of endodontically treated teeth. *J Am Dent Assoc* 1990;120:558, 560, 562.

15. Baratieri LN, De Andrada MA, Arcari GM, Ritter AV. Influence of post placement in the fracture resistance of endodontically treated incisors veneered with direct composite. *J Prosthet Dent* 2000;84:180-4.
16. Cooney JP, Caputo AA, Trabert KC. Retention and stress distribution of tapered-end endodontic posts. *J Prosthet Dent* 1986;55:540-6.
17. Bergman B, Lundquist P, Sjögren U, Sundquist G. Restorative and endodontic results after treatment with cast posts and cores. *J Prosthet Dent* 1989;61:10-5.
18. Cheung W. A review of the management of endodontically treated teeth. Post, core and the final restoration. *J Am Dent Assoc* 2005;136:611-9.
19. Gutmann JL. The dentin-root complex: Anatomic and biologic considerations in restoring endodontically treated teeth. *J Prosthet Dent* 1992;67:458-67.
20. Gordon FL Jr. Post preparations: A comparison of three systems. *J Mich Dent Assoc* 1982;64:303-4.
21. Leary JM, Aquilino SA, Svare CW. An evaluation of post length within the elastic limits of dentin. *J Prosthet Dent* 1987;57:277-81.
22. Zillich RM, Corcoran JF. Average maximum post lengths in endodontically treated teeth. *J Prosthet Dent* 1984;52:489-91.
23. Shillingburg HT, Hobo S, Whitsett LD, Jacobi R, Brackett SE. *Fundamentals of fixed prosthodontics*. 3rd ed. Quintessence, Chicago; 1997 (p. 85-103, 191-2).
24. Kvist T, Rydin E, Reit C. The relative frequency of periapical lesions in teeth with root canal-retained posts. *J Endod* 1989;15:578-80.
25. Bartlett SO. Construction of detached core crowns for pulpless teeth in only two sittings. *J Am Dent Assoc* 1968;77:843-5.
26. Stern N, Hirshfeld Z. Principles of preparing endodontically treated teeth for dowel and core restorations. *J Prosthet Dent* 1973;30:162-5.
27. Caputo AA, Standlee JP. Restoration of endodontically involved teeth. In: *Biomechanics in Clinical Dentistry*. Chicago: Quintessence; 1987. p. 185-203.
28. Morgano SM. Restoration of pulpless teeth: Application of traditional principles in present and future contexts. *J Prosthet Dent* 1996;75:375-80.
29. Schwartz RS, Robbins JW. Post placement and restoration of endodontically treated teeth: A literature review. *J Endod* 2004;30:289-301.
30. Kovarik RE, Breeding LC, Caughman WF. Fatigue life of three core materials under simulated chewing conditions. *J Prosthet Dent* 1992;68:584-90.
31. Craig RG, Ward ML. *Restorative Dental Materials*. 10th ed. St. Louis: Mosby; 1997. p. 137.
32. Larson TD, Jensen JR. Microleakage of composite resin and amalgam core material under complete cast crowns. *J Prosthet Dent* 1980;44:40-4.
33. Lakshmi S, Krishna VG, Sivagami. Prosthodontic considerations of endodontically managed teeth. *J Conserv Dent* 2006;9:104-9.
34. Pilo R, Cardash HS, Levin E, Assif D. Effect of core stiffness on the *in vitro* fracture of crowned, endodontically treated teeth. *J Prosthet Dent* 2002;88:302-6.
35. Millstein PL, Ho J, Nathanson D. Retention between a serrated steel dowel and different core materials. *J Prosthet Dent* 1991;65:480-2.
36. Reeh ES, Messer HH, Douglas WH. Reduction in tooth stiffness as a result of endodontic and restorative procedures. *J Endod* 1989;15:512-6.
37. Meyenberg K. The ideal restoration of endodontically treated teeth - structural and esthetic considerations: A review of the literature and clinical guidelines for the restorative clinician. *Eur J Esthet Dent* 2013;8:238-68.
38. Vârlan C, Dimitriu B, Vârlan V, Bodnar D, Suci I. Current opinions concerning the restoration of endodontically treated teeth: Basic principles. *J Med Life* 2009;2:165-72.
39. Polesel A. Restoration of the endodontically treated posterior tooth. *G Ital Endod* 2014;28:2-16.
40. Garlapati R, Venigalla BS, Chintamani R, Thumu J. Re-treatment of a two-rooted maxillary central incisor - A case report. *J Clin Diagn Res* 2014;8:253-5.
41. Grondahl HG, Huuonen S. Radiographic manifestations of periapical inflammatory lesions. *Endod Topics* 2004;8:55-67.
42. Scarfe WC, Levin MD, Gane D, Farman AG. Use of cone beam computed tomography in endodontics. *Int J Dent* 2009;2009:634567.
43. Leonardo MR. Anatomical aspects of the pulp cavity: Relations in the treatment of root canals. In: Leonardo MR, Leal JM, editors. *Endodontics: Root Canal Treatment*. 3rd ed. Are Paul: Panamericana; 1998. p. 191.
44. Ingle JI. *Endodontics*. 3rd ed. Philadelphia: Saunders; 1985.
45. Vertucci FJ. Root canal anatomy of the human permanent teeth. *Oral Surg Oral Med Oral Pathol* 1984;58:589-99.
46. DeGrood ME, Cunningham CJ. Mandibular molar with 5 canals: Report of a case. *J Endod* 1997;23:60-2.
47. Eugeniu MC, Radu C, Vlad P. Chlorhexidine as endodontic cleaning solution compared to sodium hypochlorite: An *in vivo* study. *Int J Dent Med Spec* 2015;2(1):2-6.
48. Esteves H, Correia A, Araújo F. Classification of extensively damaged teeth to evaluate prognosis. *J Can Dent Assoc* 2011;77:b105.

How to cite this article: Shekhar S, Mittal S. Permanent Restoration in Endodontically Treated Teeth: Clinical Dilemma, Future Trends and Review of literature. *Int J Dent Med Spec* 2015;2(3):29-36.

Source of Support: None; **Conflict of Interest:** None