

Oral Soft Tissue Metastasis of Ovarian Malignancy, A Way to Other Hidden Malignancies: A Rare Case Report

Nupur Agarwal¹, Puneet Gupta²

¹Department of Oral Medicine and Radiology, Institute of Dental Sciences, Bareilly, Uttar Pradesh, India,

²Department of Public Health Dentistry, Institute of Dental Sciences, Bareilly, Uttar Pradesh, India

ABSTRACT

The metastasis of malignant tumors within the oral cavity always remains a rare clinical entity. Most metastatic tumors have the propensity for involving the mandible rather than the other oral soft tissues structures. Within, we describe an unusual case of ovarian malignancy that metastasized to the mandibular and involved the mandibular gingiva as an initial manifestation, and as per our best knowledge this is the second reported case until now. There is limited erudition regarding ovarian cancer metastatic and involving the oral cavity.

Key words: Gingival metastasis, immunohistochemistry, ovarian malignancy

INTRODUCTION

The oral and maxillofacial region is an uncommon site for metastatic tumor cell colonization and is usually evidence of a widespread disease. In 25% of cases, oral metastases were found to be the first sign of the metastatic spread and in 23% it was the first indication of an undiscovered malignancy at a distant site. The jaw bones, particularly the mandible, were more frequently affected than the other oral and maxillofacial hard and soft tissues structures with a ratio of 2:1. In the oral soft tissues, the attached gingiva was the most commonly affected site (54%). The principal vital organs presenting with oral metastases were the lung, kidney, liver, and prostate for men, breast, female

genital organs (FGO), kidney, and colorectum for women. The primary site differs according to oral site colonization, in male the lung found to be the most common primary vital organ affecting both the jaw bones and oral mucosa (22% and 31.3%, respectively), followed by the prostate gland, jawbones (11%) and kidney in the oral soft tissues (14%). In females, the breast was the most common affecting organ including primary tumor affecting the jawbones (7.7%) and soft tissues (41% and 24.3%, respectively), followed by the adrenal gland and FGO (14.8%).

Metastatic tumors of the oral and maxillofacial region are rare with an incidence of about 1% of all oral cancers. The tumor metastasize in the oral soft tissues or the jawbones, individually the mandible (14, 21), indicating the evidence of a widespread disease. Due to the rarity of this clinical entity, the correct diagnosis of metastatic tumors to the oral cavity remains a challenge (14). Histological evaluation of the oral lesion and imaging studies of the whole body is warranted to detect a possible primary malignancy, whenever a metastatic tumor in the oral cavity is suspected.

Access this article online	
	<p>Publisher</p>
	<p>Website: www.renupublishers.com</p>
	<p>DOI: 10.5958/2394-4196.2015.00004.7</p>

Address for correspondence:

Dr. Nupur Agarwal, Department of Oral Medicine and Radiology, Institute of Dental Sciences, Bareilly, Uttar Pradesh, India.
Phone: +91-8937946494, E-mail: rupun48@gmail.com

Submission: 08 Dec 2014; **Revision:** 04 Jan 2015; **Acceptance:** 28 Jan 2015

In women, the breast cancer is the most common primary tumor affecting the jawbones and oral soft tissues, followed by carcinomas of the adrenal and FGO (14). Various cases of the mandibular metastasis from gynecologic cancers have been reported, including endometrial cancer (8, 12) and cervical cancer (20). However, there is insufficient erudition regarding the metastatic ovarian cancer to the oral cavity. Within, we describe an unusual case of ovarian mucinous cystadenocarcinoma metastasizing to the gingiva at an initial clinical manifestation.

Ovarian cancer is the utmost usual condition of death from gynecological malignancy in Europe and the United States.^[1] Most patients have local or systemic metastasis at the time of examination.^[2,3] Although the intraperitoneal route of dissemination is considered the most common, it may also metastasize through lymphatic channels and hematogenous spread.^[4] Metastasis of ovarian serous carcinoma to the axillary lymph node is uncommon with only isolated case reports so far. Epithelial ovarian cancer is the most lethal gynecologic malignancy and the fifth most common cause of cancer-related death in women.^[5] The estimated annual incidence of this disease worldwide is just over 200,000 individuals, with approximately 125,000 deaths.^[6]

The clinical presentation of the metastatic lesions differs between the various sites in the oral region. In the jawbones, most patients complain of swelling, pain and paresthesia, which developed in a relative short period. Early manifestation of the gingival metastases resembled a hyperplastic or reactive lesions, such as pyogenic granuloma, peripheral giant cell granuloma, or fibrous epulis. Due to its rarity, the diagnosis of a

metastatic lesion in the oral region is challenging, both to the clinician and to the pathologist, in recognizing that a lesion is metastatic and in determining the site of origin. The clinical presentation of a metastatic lesion in the oral cavity can be deceiving leading to a misdiagnosis of a benign process; therefore, in any case where the clinical presentation is unusual, especially in patients with a known malignant disease a biopsy is mandatory.

CASE REPORT

A 60-year-old female patient was reported to the department of oral medicine, diagnosis and radiology with the principal complaint of painless swelling on the right lower side of the face since 2 months. Initially swelling was approximately 1 cm smaller in size and has reached its present size in 2 months. Patient is giving history of extraction in right and left lower back teeth region 2 and 2.5 months back. There is no history of

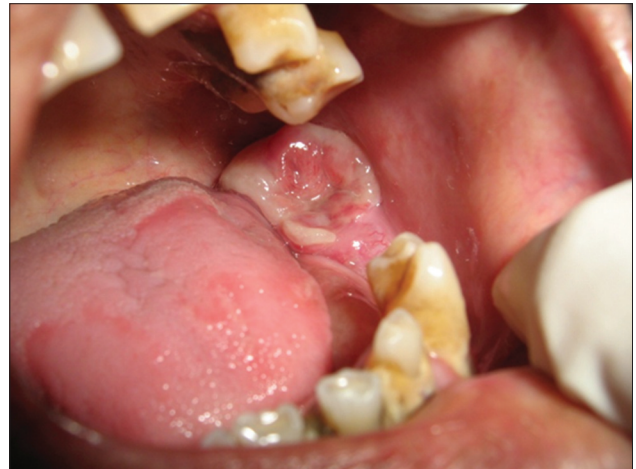

Figure 2: Intraoral photograph showing ulceroproliferative growth

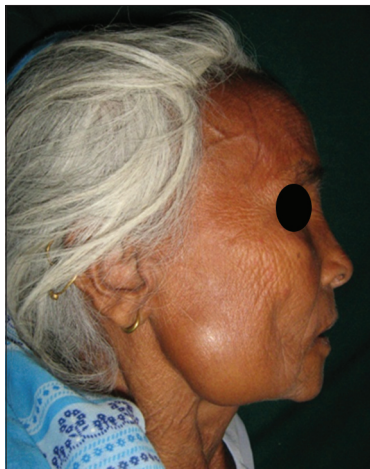

Figure 1: Extraoral photograph showing swelling

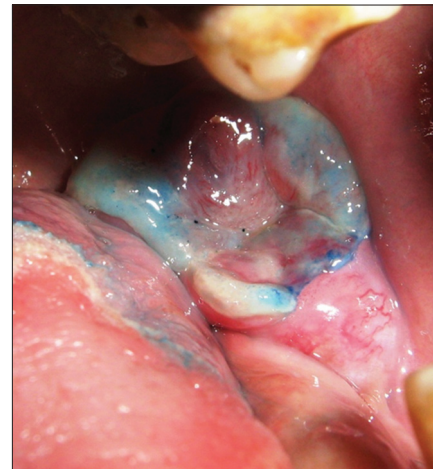


Figure 3: Toluidine blue staining

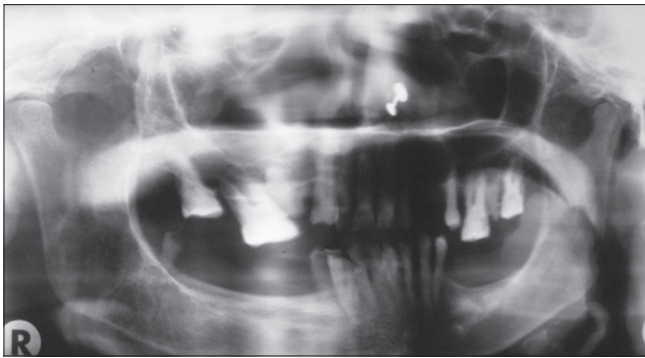


Figure 4: Orthopantomogram

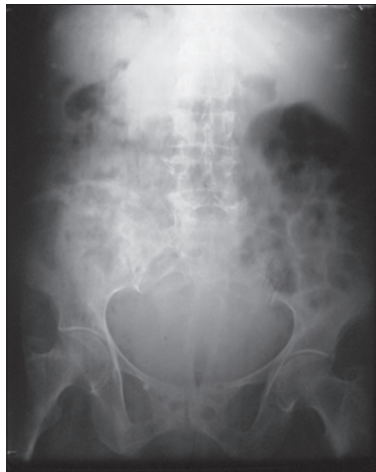

Figure 5: Non-significant general body radiograph

anesthesia or paresthesia. Patient was also giving history of fever since 15 days and generalized body ache. Patient visited the medical college for this swelling also, where fine needle aspiration cytology (FNAC) was performed, and it was diagnosed as pleomorphic adenoma. No treatment was given, and the patient was referred to the dental college. Patient gave history of gutka and tobacco chewing since 20 years. She took 2-3 packets per day. General physical examination revealed that temperature was raised to 99° F. Patient was hypertensive with the blood pressure of 160/80 mmHg. Pallor of palpebral conjunctiva was present.

Extraoral examination revealed that face of the patient was bilaterally asymmetrical with a solitary well defined swelling present on the right side of the face extending over the angle of the mandible measuring about 3-4 cm in diameter roughly oval in shape extending anteroposteriorly from a line dropping from the outer canthus of the eye to the angle of the mandible and superoinferiorly from 0.5 cm below the tragus of the ear to 0.5 cm below the lower border of the mandible. It had well-defined boundaries, color of the overlying

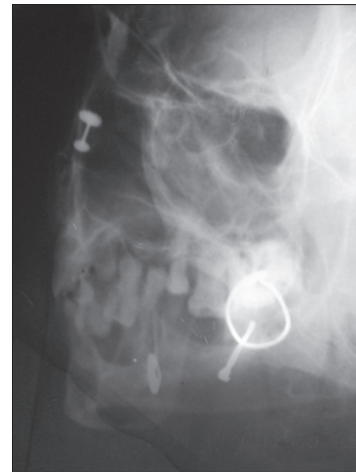


Figure 6: Lateral oblique view

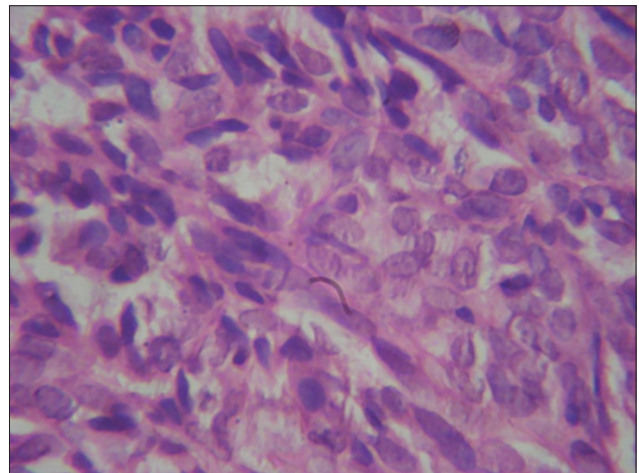


Figure 7: Histo-pathological photograph

skin was normal. No secondary changes were seen. On palpation, swelling was non-tender, firm in consistency, non-fluctuant and non-mobile. All the inspeactory, as mentioned above findings, were confirmed. Temperature of the overlying skin was slightly raised. Submandibular lymph nodes on the right and left side were palpable, 4 in number i.e. 2 on each side, non-tender, firm in consistency and fixed. Intraoral examination revealed the presence of ulcero proliferative growth measuring about 3 cm in its greatest dimension in the left mandibular alveolar ridge extending from the distal surface of 35 to the retromolar area. It had irregular borders with raised and everted edges on the lateral aspect and sloping edges on the posterior medial aspect. It was sessile and had indurated base. On palpation, it was soft in consistency and slightly tender. Other findings were atrophy of papillae of the tongue.

Hard tissue examination revealed missing teeth in relation to 36, 37, 46 and 47, supra erupted teeth in

relation to 16, 17, 26, 27, Grade 1 mobility in relation to 26 and 27, generalized attrition, and generalized gingival recession with generalized stains and calculus was present.

Hence considering the history and clinical examination provisional diagnosis of chronic non-healing ulcer was given in relation left mandibular alveolar ridge was given. Differential diagnosis of malignant ulcer and metastatic carcinoma was thought.

Vital staining was performed, and the lesion took the toluidine blue stain, and hence it was suggestive of dysplastic changes. Orthopantomograph was taken to see the bone involvement no finding was seen in the area of interest. Full body radiographs were taken and were suggestive of generalized osteoporosis. Biopsy was taken from the ulcer-proliferative growth and was sent for histopathological examination. Histopathological findings were suggestive of anaplastic carcinoma [Figures 1-7]. However, it revealed the presence of cells that were giving the coffee bean appearance with the central grooving that are the characteristic features of granulosa cell tumor of the ovary. Hence, patient was referred to the department of general medicine for full body checkup where ultrasound of the abdomen was advised and which revealed the presence of large ovarian mass and was suggestive of ovarian malignancy.

As the diagnosis has not been confirmed by histopathology, it was sent for immunochemistry, which revealed that inhibin and vimentin were the positive markers, which was suggestive of granular cell tumor of an ovary. Hence considering the history, clinical examination, histopathology and immunohistochemistry (IHC) final diagnosis of secondary metastasis from ovary was given. Patient was called up for treatment, but she did not report, on enquiring we came to know that patient was expired.

DISCUSSION

Metastasis is defined as the spread of tumor by invasion in such a way that discontinuous secondary tumor mass/masses are formed at the site of lodgment. Metastatic tumors to the oral region are uncommon, comprising only 1-3% of all malignant oral neoplasms.^[1] These tumors, however, are of great clinical significance, as their appearance may be the first indication of an

undiscovered malignancy at a distant primary site or the first evidence of dissemination of a known tumor from its central site. Metastatic lesions may occur in the oral soft tissues, in the jawbones or involving both osseous and soft tissue. The common primary sources of tumors metastatic to the oral region are the breast, lung, and kidney.^[2] The lung is the most common source of metastases to the oral soft tissues, whereas the breast is the most common source of metastatic tumors to the jawbones. In the jawbones, the mandible is the most common location for metastases, with the molar area being the most frequently involved site.

The criteria by which one can consider a malignant jaw lesion to be a metastatic tumor include: (a) Histological verification – namely finding that the primary tumor and the jaw lesion are identical from a histological standpoint, including special staining and other studies such as electron microscopy, (b) the fact that the MT is not found in a site typical of primary oral tumors, (c) the fact that the possibility of direct extension to the jawbones from a primary oral tumor can be excluded, (d) genetic analysis - namely, the identical cytogenetic findings in both the primary tumor and in the metastatic jaw lesion, can be a significant contribution to the histopathologic diagnosis of the lesion, being a metastasis.^[3] The exact mechanism of tumor metastasis from distant sites to the jawbones is not entirely understood. However, autopsy records indicate that tumors tend to be site-specific in their patterns of metastases. For many tumors the nearest anatomic site encountered will be the most common site for metastatic-colony formation. Other tumors are more “selective” and by-pass nearby proximal organs and selectively colonize in a particular distal organ. The primary tumors that metastasize to the oral region and the jawbones probably belong to the group of “more selective” tumors. The common routes of metastases by distant tumors to the oral region and/or the jawbones are via the lymphatic channels or by hematogenous spread.

Each of the three main categories of ovarian tumors has distinctive immunohistochemical features and stains can be used to suggest or confirm a diagnosis. IHC is often useful to differentiate between primary ovarian adenocarcinoma and metastatic adenocarcinomas specially those of colorectal origin. It is also helpful in diagnosing other ovarian metastatic tumors, especially in the absence of a known primary elsewhere. Various markers may also be of value in peritoneal biopsy or fluid specimens when faced with an adenocarcinoma of unknown primary.

Cormio *et al.*^[7] reported 8% of their patients had distant metastasis at initial presentation, and 22% developed them during the course of their diseases, only five of their 162 patients had extra-abdominal spread. They also concluded that distant metastasis occurs in about one-third (30%) of epithelial ovarian carcinoma, and the interval time between diagnosis of ovarian cancer and documentation of distant metastases is the most important prognostic factor.

Tumor markers like serum Ca125 (glycoprotein antigen and most widely used marker), human epididymis protein 4, alpha-feta protein, human chorionic gonadotropin and lactate dehydrogenase are also recommended in women under 40 years. Carcinoembryonic antigen and cancer antigen 19.9 (Ca19.9) are two other tumor markers that are commonly ordered for the investigation of an ovarian mass; however, their application to clinical practice is unclear.

Clinical features:^[1,2]

- The metastatic tumors to the oral cavity remain to be uncommon
- The jawbones are more frequently affected than the oral soft tissues, and the mandible is the,
- Most common location with the molar area being the most frequently involved site
- In the oral soft tissues, the gingiva is the most common affected site, followed by the tongue
- The most common primary tumors metastasizing to the oral mucosa in females are breast, followed by FGO, kidney, bone, colorectum, and skin.

Clinical presentations of the metastatic lesions includes the swelling, pain, ulcer, mobile teeth, hemorrhage, trismus, paresthesia, pathological fracture, paresthesia in the, mandibular metastasis is reported to be located in the area innervated by the mandibular alveolar dental nerve. Gingival metastases are shown to be polypoid or exophytic, highly vascularized, and hemorrhagic.

Radiographic examination of the metastatic lesions often presents a radiolucent osteolytic lesion with ill-defined border, while metastatic prostate carcinoma gives osteoblastic appearance. Metastatic renal or breast carcinoma may give the appearance of osteolytic, osteoblastic, or mixed type.^[4] The radiographic appearance of metastatic disease in the oral and maxillofacial region varies from well- to poorly

circumscribed radiolucencies is known as a “moth-eaten” appearance.

The differential diagnosis includes hemangioma, pyogenic granuloma, giant-cell granuloma, peripheral fibromas, adenoid squamous cell carcinoma and polymorphous low-grade adenocarcinoma that affects the minor salivary glands of the mouth.^[1,5] The treatment regimen includes local resection, palliative radiotherapy, chemotherapy, or supportive care only to improve the quality of life. In most cases of the oral metastasis, the prognosis is shown to be grave with an average survival period of about 7 months.^[2,5]

CONCLUSION

Ovarian carcinoma mostly remains the leading cause of death in women worldwide. Because ovarian cancer tends to grow silently, this disorder is often diagnosed at an advanced stage. We presented an unusual presentation of an ovarian cancer that developed the gingival metastasis. This case emphasizes that although rare, metastatic ovarian cancer to the oral cavity should be incorporated in the differential diagnosis of the metastatic tumors in the oral cavity.

The patient should be complete and detail oral examination is must and hematological investigations such as complete blood count, liver and renal function tests, bronchoscopy, oesophageal-duodenoscopy, ultrasound whole abdomen and FNAC also play a significant role in diagnosis and management of ovarian tumors. Computed tomography scan of abdomen and chest should be done to exclude gastric and lung carcinoma. Tumor markers may be performed whenever necessary.

REFERENCES

1. Sasaki H, Ohara N, Minamikawa T, Umeda M, Komori T, Kojima N, *et al.* Gingival metastasis from ovarian mucinous cystadenocarcinoma as an initial manifestation (a rare case report). *Kobe J Med Sci* 2008;54:E174-82.
2. Bodner L, Sion-Vardy N, Geffen DB, Nash M. Metastatic tumors to the jaws: A report of eight new cases. *Med Oral Patol Oral Cir Bucal* 2006;11:E132-5.
3. Chang KH, Lee JP, Ryu HS. Rare case of stage IA epithelial ovarian cancer with bone as the first site of recurrent metastasis. *Int J Gynecol Cancer* 2006;16:322-6.
4. D'Silva NJ, Summerlin DJ, Cordell KG, Abdelsayed RA, Tomich CE, Hanks CT, *et al.* Metastatic tumors in the jaws: A retrospective study of 114 cases. *J Am Dent Assoc* 2006;137:1667-72.
5. Galen DM. Mandibular metastasis of endometrial carcinoma diagnosed via a dental radiograph. *J Am Dent Assoc* 1998;129:1595-8.

6. Coward JI, Middleton K, Murphy F. New perspectives on targeted therapy in ovarian cancer. *Int J Womens Health* 2015;7:189-203.
7. Cormio G, Rossi C, Cazzolla A, Resta L, Loverro G, Greco P, *et al.* Distant metastases in ovarian carcinoma. *Int J Gynecol Cancer* 2003;13:125-9.

How to cite this article: Agarwal N, Gupta P. Oral Soft Tissue Metastasis Ovarian Malignancy, Way to Other Hidden Malignancies: A Rare Case Report. *Int J Dent Med Spec* 2015;2(1):18-23.

Source of Support: None; **Conflict of Interest:** None