

# Management of Empty Scrotum (Cryptorchidism) in Childrens: Testicular or Scrotum Abnormality (Review)

Muhammad Ujudud Musa

Department of Surgery, Federal Medical Centre, Katsina, P.M.B 2121, Katsina State, Nigeria

## ABSTRACT

Cryptorchidism (translated hidden testis) is the most common genital abnormality of childhood, refers to the incomplete descent of the testicle into dependent scrotum. The undescended testicles (UT) can be located anywhere along the path of regular descent between the kidney and just outside of scrotal inlet. It is also known as UT because the majority of testicles that do not migrate completely into the scrotum by birth can be palpable in different areas like in the inguinal region. It affects approximately 30% of baby boys born prematurely and about 4% born at term. As a baby boy grows inside mother's womb, his testicles are typically formed inside his abdomen and move down (descend) into the scrotum shortly before birth. However in some cases, that move or descent does not occur, and the baby is born with a condition known as UT (or cryptorchidism). Almost 1 in every 100 male children born will have an empty scrotum. It may be on one side or both sides of the scrotum.

**Key words:** Children, cryptorchidism, scrotum, undescended testes

## INTRODUCTION

The word cryptorchidism is obtained from the Greek word "Kryptos" meaning "hidden" and "orchid" meaning "testicles".<sup>[1]</sup> The scrotum is the muscular out-pouching of the lower part of the anterior abdominal wall housing the normal testis.<sup>[2]</sup> The management of empty scrotum in children poses a serious challenge to the urologist, in terms of management, which depends on how early the patient present. It is one of the most visible congenital anomalies, occurring in 1-4% of full-term male neonates.<sup>[3]</sup> In 1950, Scorer followed 1499 male newborns and reported

an overall incidence of undescended testis (UT) in 2.7% at birth and 0.8% at 3 months of age. The prevalence of cryptorchidism in adults is about 1% at 1-year of age.<sup>[4]</sup> Testicular descent occurs late in fetal life and is governed by many factors, including intra-abdominal pressure, hormonal and neurological influence and presence of the gubernaculum. The nonexistence of any of these elements may contribute to cryptorchidism. The incidence of cryptorchidism also increases in neural tube defect disorders, myelomeningocele, omphalocele, anencephaly, abnormalities of testosterone or gonadotropin deficiencies such as Kallmann's syndrome, etc.

The patient can present with the symptom of empty scrotum early in birth (premature) to <2 years old or late presentation after 2 years and low birth weight children. It includes child born prematurely due to a host of maternal and fetal causes, including twin gestation. Maternal obesity, cesarean section

| Access this article online  |  |
|---|--|
| <b>Publisher</b><br> | <b>Website:</b><br><a href="http://www.renupublishers.com">http://www.renupublishers.com</a> |
|   | <b>DOI:</b><br>10.5958/2394-4196.2014.00007.7  |

### Address for correspondence:

Dr. Muhammad Ujudud Musa, Department of Surgery, Federal Medical Centre, Katsina, P.M.B 2121, Katsina State, Nigeria.  
Tel.: +234-8036005365. E-mail: [ujudud@gmail.com](mailto:ujudud@gmail.com)

**Submission:** 11 Oct 2014; **Revision:** 21 Nov 2014; **Acceptance:** 09 Dec 2014

delivery and low birth weight have been associated with cryptorchidism. Delayed menarche and shorter menstrual have been noted with increased frequency in mothers of cryptorchidism child. Its growth and maturity are retarded and its capacity to produce hormones and sperms may be reduced or permanently lost. Cryptorchidism may also arise from male descent of testes 2 when they become resided at an ectopic site resulting on malformation of the gubernaculum testis that guides the gonadal descent.

It is well-known that the gonads in both sexes originate in the lumbar region of the fetus and then descend in internal inguinal ring. Further migration into the scrotum is influenced by androgens and Mullerian inhibiting substance (MIS), and therefore happens only in male fetuses.

Cryptorchidism may be of two types [Figure 1] congenital or acquired, which may be true or ectopic cryptorchidism. Recent evidences suggest that not all the UT are present from birth. Many children with cryptorchidism present late in childhood. This has led to controversy over whether the diagnosis of abnormality was missed in early childhood or whether they have an anomaly that only becomes clinically evident later on. Such type of testis may be called as retractile or ascending testis. Acquired cryptorchidism may be secondary to failure of the spermatic cord to elongate in proportion to body growth. Although testis may appear to ascend out of the scrotum with increasing age, the real anomaly is more likely to be the failure of elongation of cord.

Cryptorchidism is a defect involving male descent of the testicle. The objectives of therapy for cryptorchidism include preservation of fertility, reduction of the risk of malignancy, and alleviation of physiological stress in human male. The incidence of cryptorchidism

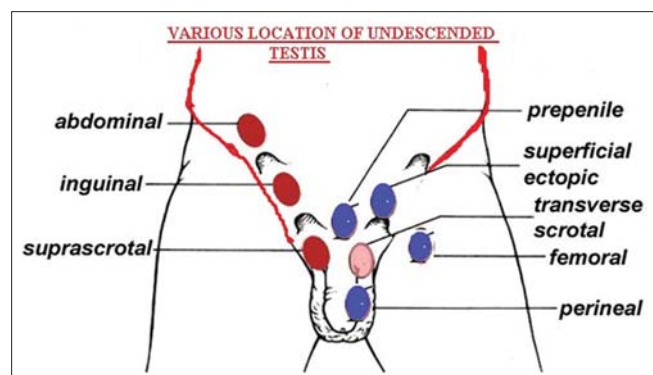


Figure 1: Various location of testes

in the newborn is 2-6%; however, with spontaneous descent of the testis, this incidence drops to 1% by the age of 3 months.<sup>[3]</sup> Both the testes and ovaries originate from a common bipotential precursor. In the embryonic level, several factors such as SRY genes (sex-determining region on Y chromosome), SRY proteins, anti-mullerian hormone, and MIS helps in the differentiation of the male gonad.

There are many possibilities in a child suffering with an empty scrotum ranging from congenital UT with 4% incidence at birth. For a full termed neonate, out of which 80% will spontaneously descend by 6 months, through retractile testis down to the rare, testicular anochia.<sup>[5]</sup>

The dilemma and enigma the urologist had when this presentation is bilateral can be very tasking especially if the child present late for the treatment of empty scrotum, with the risk of malignant transformation rising to 8-folds higher than the normal individuals. They also have a higher risk of testicular torsion and trauma or it may be a harbinger to a more serious congenital anomaly such as ectopia vesicea, prune-belly syndrome or disorder of sexual development and differentiation.

In Zaria Nigeria 75% of the patients present after 5 years while in Tanzania 57.5% were operated after 5 years 74% were palpable and 26% were non-palpable, 45% were canalicular, 31% were found in the internal ring and 20% each in the internal ring and intra-abdominal.<sup>[6]</sup>

Pre-termed children have up to 40% incidence of UT, commonly on the left testis, about 20% of children with UT will descend in within the first 4 months of life,<sup>[7]</sup> hence the parents of those presenting early may just needs to be reassured, while in late presentation a detailed history and through physical examination with relevant investigations will form the armamentarium of evaluating this patient.

The treatment depends on the cause, the presentation, associated anomalies, the co-morbidities and whether it is unilateral or bilateral pathology [Table 1]. The treatment options ranges from reassurance, through orchidopexy to inguinal exploration with or without orchidectomy.

Giwerzman *et al.* (1993)<sup>[8]</sup> in their reports have suggested that the incidence of genitourinary abnormalities in human males has increased during the past 50 years, including congenital abnormalities

**Table 1:** Management of un-descended Testicles

| Non-surgicals                          | Surgicals  |
|--|--|
| Observation for retractile testes only | Standard orchidopexy (open surgery or laparoscopy) |
| Hormone therapy                        | Two staged laparoscopic orchidopexy                |

such as cryptorchidism and hypospadias, which seem to be occurring more commonly. The increase in these abnormalities over a relatively short period of time may be due to the environmental rather than genetic factors.

## CLINICAL FEATURES

History is very important in this category of individuals which can be obtained from the mother or the care giver of the child. History of the age of the patient at presentation is paramount which has a bearing to the on the type of treatment will be offered, the gestational age of the patient at birth and the birth weight of the child are important.

History of associated anomalies such as micro phallus indicating hypogonadism or presence of abnormal swellings in the inguinal region due to hernia, history of perineal or femoral swellings may be due to ectopic testis.<sup>[9]</sup>

History of events during the pregnancy such as maternal ingestion of drugs may be a pointer to androgenized female presenting with bilateral UT. History of occasional presence of the testis, but its absence, especially during cold season is seen in retractile testis.

History of abdominal swellings, weight loss, cough, difficulty in breathing or jaundice and other metastatic symptoms may be elicited in those children presenting late with malignant transformation due neglected to UT.<sup>[9]</sup>

On pathological findings:

- Testicular atrophy
- Hyalinized seminiferous tubules
- Hypospermatogenesis
- Sertoli cell-only syndrome
- Immature testis.

Semen analysis findings:

- Azoospermia
- Asthenozoospermia.

On pre-operative palpation of scrotum may be palpable with smaller size or not palpable. Location of testis

during surgery can be seen at inguinal, pre-pubic or intra-abdominal region.

Complications if left un-treated:

- Infertility: This can occur in patients who had bilateral orchidectomy or in those with bilateral testicular artery injury
- Torsion and loss of organ
- Development of cancer in the testis
- Psychological disorders
- Testicular cancer
- Hematoma: Which can be seen early post-operatively
- Surgical site infection: Due to proximity to the perineum
- Retraction: This may necessitate second surgery to address
- Malignant transformation: This is seen in neglected patients in which the chronic temperature insult to the testis leads to dysplasia, metaplasia and malignant transformation
- Testicular atrophy: This can be seen in up to 5% of patients who had exploration because of testicular vessels injury<sup>[10]</sup>
- Psychological stress: This is seen in patients who had bilateral orchidectomy.

### Possible cause of cryptorchidism

| Anomaly                            | Possible cause   |
|------------------------------------|--|
| Prune belly syndrome               | Enlarged bladder blocks inguinal canal   |
| Posterior urethral valves          | Enlarged bladder blocks inguinal canal   |
| Persistent mullerian duct syndrome | MIS deficiency blocks gubernacular swelling                                    |
| Abdominal wall defects             | Lower abdominal wall pressure/ gubernacular rupture                            |
| Perineal ectopic testis            | Aberrant site of GFN misdirects migration                                      |
| Testicular epididymal separation   | Disruption of gubernacular attachment; androgen deficiency inhibits epididymis |
| Ascending testis                   | Fibrous remnant of processus vaginalis   |
| Congenital cryptorchidism          | Failure of first/second phase of testicular descent                            |
| Acquired cryptorchidism            | Failure of elongation of spermatic cord  |
|                                    | Cerebral palsy   |
|                                    | Persisting remnant of processus vaginalis                                      |

GFN: Genitofemoral nerve, MIS: Mullerian inhibiting substance

## INVESTIGATIONS

- Ultrasonography
- Computed tomography
- Magnetic resonance imaging.

The most important investigation in diagnosis for empty scrotum is ultra-sonography, gives details about its availability and absence of radiation.

In 3 of 10 boys, the testicle may not be in a location where it can be located or palpated, and may appear to be missing. In some of these cases, the testicle could be inside the abdomen. In some boys with a “non-palpable” testicle, however, the testicle may not be present because it was lost while the baby was inside the womb.

In some boys, the testicles (or “testes”) may appear to be outside of the scrotum from time to time, which can raise the concern of an UT. Some of these boys may have the condition known as retractile testes. This is a normal condition in which the testes reside in the scrotum, but on occasion temporarily retract or pull back up into the groin.

There is no need to treat a retractile testicle, since it is a normal condition, but it might require examination by a pediatric specialist to distinguish it from an UT.

- Abdominal-pelvic ultrasound scan: This is important in locating the testis in the abdomen or the inguinal canal, it also helps in determining the size of the testis, and it can be useful in evaluating the internal sex organs
- Endocrine analysis: This is indicated in suspected cases of hypogonadism leading to testicular anochia, which will show an elevation of luteinizing hormone and Follicle stimulating hormone with low testosterone
- Chromosomal analysis: In the form of karyotyping or peripheral blood film for bar bodies, in suspected cases of masculinized females
- Serum urea, electrolytes and creatinine: In patients with the salt losing type of congenital adrenal hyperplasia the serum sodium and chloride levels are very low
- Diagnostic laparoscopy: This will help in visualizing the location of an intra-abdominal testis and its nature whether normal or hypoplastic, it can also envision the internal sex organs of the patient
- Minilaparotomy: If the facility for laparoscopy is not available then, minilaparotomy can be used to envision the internal sex organs and to take a biopsy
- Baseline investigations: Full blood count and differentials, genotype, grouping and cross matching of blood, urine microscopy culture and sensitivity are necessary for the preparation for definitive surgery.

## DISCUSSION

Numerous previous studies have concluded the risk of cancer and fertility in cryptorchidism patients by

evaluating the clinical perspective with therapeutic preferences (orchipexy or orchiectomy), histological findings and semen analysis.

In terms of clinical characteristics, previous studies have demonstrated that most adult patients had unilateral cryptorchidism, which was palpable before the surgical procedure, but in numerous cases cryptorchid testes were smaller than the contralateral testes. The location of the cryptorchid testis in the intra operative surgery was mostly in the inguinal area. The clinical characteristics in adult cryptorchidism seem to be similar to those of child cryptorchidism.

It is thought to be difficult to establish a treatment for adult cryptorchidism, given the small number of patients. Therefore, some controversy exists regarding the effect of cryptorchid testis on neoplasia and fertility in adult patients.

In previous studies,<sup>[11-15]</sup> it has been noted that a late operation for UT is associated with an increased risk of testicular malignancy and infertility. The relative risk of testicular cancer in a cryptorchid testis is 2.75~8 times (maximally 40 times) greater than in the general population.<sup>[16,17]</sup> In a large cohort study of 16,983 men who were surgically treated for cryptorchidism, the risk of testicular cancer among men who were treated at 13 years of age or older was approximately twice that among men who underwent orchiopexy before the age of 13.<sup>[12]</sup>

In terms of fertility, it is well established that the untreated cryptorchid testis is associated with infertility. There is evidence that the development of postnatal germ cells deteriorates in the UT after the 1<sup>st</sup> year, and perhaps for this reason, the risk of infertility increases with age.<sup>[13-15]</sup> Many authors have reported that testes remaining undescended until post-pubertal age will not function and that fertility rates are not improved after post-pubertal repair.<sup>[18-20]</sup> Therefore, it has been recommended that these testes be resected because they cannot produce spermatozoa and have a significant risk of malignant change.<sup>[21]</sup> In other studies, orchiectomy is recommended more highly, especially in unilateral cases, for several reasons, including abnormal findings in the semen analysis and testicular neoplasm in follow-up studies.<sup>[11,22]</sup>

On the other hand, some articles on the topic of post-pubertal cryptorchidism have demonstrated that post-pubertal orchiopexy could provide fertility by initiating

spermatogenesis.<sup>[18-20]</sup> Shin *et al.*<sup>[19]</sup> reported the induction of spermatogenesis and pregnancy after adult orchiopexy. Lin *et al.*<sup>[20]</sup> reported successful testicular sperm extraction and paternity in an azoospermic man after bilateral post-pubertal orchiopexy.

Frank,<sup>[21]</sup> and Yan *et al.* 2014 researched and concluded, under the physiological conditions, Uchl1, Jab1 and p27 kip1 were not expressed in spermatocytes, but in response to the thermal stimulus of experimental cryptorchidism, the three kinds of proteins occurred simultaneously in apoptosis morphological spermatocytes. The initial apoptosis of spermatocytes and subsequent formation of MC induced by heat-stress are two main ways of spermatogenetic cell loss in cryptorchid testes, but only the former was related to Uchl1. Uchl1 occurred abnormally in the spermatocytes in response to abdominal hyperthermia, and in association with Jab1 and p27kip1, can be used to specify the mechanisms of Uchl1 involvement in the heat-stress-induced apoptosis of spermatocytes.

Treatment is necessary for several reasons:

- The higher temperature of the body may inhibit the normal development of the testicle, which could impair normal production of sperm in the UT in the future, which could lead to infertility
- The UT is at a greater risk to form a tumor than the normally descended testicle
- The UT may be more vulnerable to injury or testicular torsion
- An asymmetrical or empty scrotum may cause a boy worry and embarrassment
- Sometimes boys with UT develop inguinal hernias.

If a surgery is recommended, it's likely to be an orchiopexy. In orchiopexy, a minute cut is created in the groin and the descended testicles are brought down into the scrotum where it is arranged (or fixed) in scrotum. Surgeons typically do this on an outpatient basis, and most boys recover fully within a week.

Most doctors believe that boys who've had a single UT will have normal fertility potential and testicular function as adults, while those who've had two UT might be more likely to have diminished fertility as adults.

It is recommended that all boys who've had UT undergo follow-up evaluations by an urologist for years after their corrective surgeries.

It is important for all boys - Even those whose testicles have duly descended - To learn how to do a testicular self-exam when they are teenagers so that they can detect any lumps or bumps that might be early signs of medical problems.

Orchidopexy represents the gold standard treatment for UT. Advances in laparoscopic surgery have led to laparoscopy being used by most pediatric surgeons as both a diagnostic and therapeutic tool.

It is important to observe if, after release, the testes spontaneously stay in the scrotum. If the testes remain in the scrotum without tension on the spermatic cord, this represents a case of retractile testes. If after this maneuver the testis is not palpable, one should look for the possibility of ectopic testes. If the testis is initially felt above the scrotum, the child should be re-examined at the age of 3 months. If it remains outside of the scrotum at this age, a diagnosis of UT can be made.

## Prognosis

This depends on the age at presentation, unilateral or bilateral the degree of testicular atrophy, level of descent and time of intervention. About 75% will have fertility after orchidopexy out of which 84% have fertility if unilateral and 60% in bilateral cases.<sup>[18]</sup> 10% of patients with testicular cancer have history of UT.

## CONCLUSION

The psychological stress and trauma the parents and the child with an empty scrotum undergoes and the high risk of malignant transformation makes an empty scrotum a serious urologic problem, hence the need for meticulous evaluation prompt and appropriate treatment for these category of patients. Few studies have also concluded that orchiopexy did not provide advantages to the adult cryptorchid patients However, most adult patients still prefer orchiopexy to avoid the negative perception of emasculation. In addition, our patients did not have any malignancy or complication after orchiopexy. Therefore, we can conclude that the orchiopexy in adult cryptorchidism may be a legitimate option for management respecting the patient's preference. However, based on previous studies, ailments found in histologic findings and the semen analysis, adult patients who have undergone orchiopexy should be regularly examined in the outpatient clinic.



## REFERENCES

1. Knobil E, Neill DJ. The Physiology of Reproduction. Vol. 1. New York: Raven Press; 1988. p. 727-53.
2. Gillenwater JY, Howards SS, John T, Mitchell ME. Adult & Pediatric Urology. 4<sup>th</sup> ed. Philadelphia: Lippincott Williams & Wilkins; 2002.
3. Sengupta P. Environmental and occupational exposure of metals and their role in male reproductive functions. Drug Chem Toxicol 2013;36:353-68.
4. Diamond DA, Flores C, Kumar S, Malhotra R, Seethalakshmi L. The effects of an LHRH agonist on testicular function in the cryptorchid rat. J Urol 1992;147:264-9.
5. Wien AL, Kavoussi LR, Norvic AC. Campbell-Walsh Urology. 9th ed. Philadelphia, PA: Saunders Elsevier; 2007.
6. Steven GD, Douglas AC. The Kelalis-King-Belman Text Book of Clinical Pediatric Urology. 5<sup>th</sup> ed. London: Informa Health Care; 2007.
7. Tagnagho EA, McAninch JW. Smith's General Urology. 17th ed. New York: McGraw Hill Lange; 2008.
8. Giwercman A, Carlsen E, Keiding N, Skakkebaek NE. Evidence for increasing incidence of abnormalities of the human testis: a review. Environ Health Perspect 1993;101 Suppl 2:65-71.
9. Ameh EA, Mbibu HN. Management of undescended testes in children in Zaria, Nigeria. East Afr Med J 2000;77:485-7.
10. Soomro S, Mughal SA. Perineal ectopic testis - A rare encounter in paediatric surgical practice. J Coll Physicians Surg Pak 2008;18:386-7.
11. Lania C, Grasso M, Mantovani G, Hadjigeorgiou D, Annoni F, Rigatti P. Cryptorchidism: Review and evaluation of the fertility of adult cryptorchids. J Androl 1984;5:125-7.
12. Pettersson A, Richiardi L, Nordenskjöld A, Kaijser M, Akre O. Age at surgery for undescended testis and risk of testicular cancer. N Engl J Med 2007;356:1835-41.
13. Toppari J, Kaleva M. Maldescendus testis. Horm Res 1999;51:261-9.
14. Timing of elective surgery on the genitalia of male children with particular reference to the risks, benefits, and psychological effects of surgery and anesthesia. American Academy of Pediatrics. Pediatrics 1996;97:590-4.
15. Hutson JM, Hasthorpe S. Abnormalities of testicular descent. Cell Tissue Res 2005;322:155-8.
16. Farrer JH, Walker AH, Rajfer J. Management of the postpubertal cryptorchid testis: a statistical review. J Urol 1985;134:1071-6.
17. Wood HM, Elder JS. Cryptorchidism and testicular cancer: separating fact from fiction. J Urol 2009;181:452-61.
18. Rogers E, Teahan S, Gallagher H, Butler MR, Grainger R, McDermott TE, *et al.* The role of orchietomy in the management of postpubertal cryptorchidism. J Urol 1998;159:851-4.
19. Okuyama A, Nonomura N, Nakamura M, Namiki M, Fujioka H, Kiyohara H, *et al.* Surgical management of undescended testis: retrospective study of potential fertility in 274 cases. J Urol 1989;142:749-51.
20. Grasso M, Buonaguidi A, Lania C, Bergamaschi F, Castelli M, Rigatti P. Postpubertal cryptorchidism: review and evaluation of the fertility. Eur Urol 1991;20:126-8.
21. Frank JD. Recent Advances in Urology and Andrology. Edinburgh: Churchill Living Stone; 1987. p. 269-78.
22. Raghavendran M, Mandhani A, Kumar A, Chaudary H, Srivastava A, Bhandari M, *et al.* Adult cryptorchidism: Unrevealing the cryptic facts. Indian J Surg 2004;66:160-3.
23. Heaton ND, Davenport M, Pryor JP. Fertility after correction of bilateral undescended testes at the age of 23 years. Br J Urol 1993;71:490-1.
24. Shin D, Lemack GE, Goldstein M. Induction of spermatogenesis and pregnancy after adult orchiopexy. J Urol 1997;158:2242.
25. Lin YM, Hsu CC, Wu MH, Lin JS. Successful testicular sperm extraction and paternity in an azoospermic man after bilateral postpubertal orchiopexy. Urology 2001;57:365.
26. DU P, Yao YW, Shi Y, Gu Z, Wang J, Sun ZG, *et al.* Uchl1 and its associated proteins were involved in spermatocyte apoptosis in mouse experimental cryptorchidism. Sheng Li Xue Bao 2014;66:528-36.

**How to cite this article:** Musa MU. Management of empty scrotum (cryptorchidism) in childrens: Testicular or scrotum abnormality (review). Int J Dent Med Spec 2014;1(2):27-32.

**Source of Support:** None; **Conflict of Interest:** None